

Contents

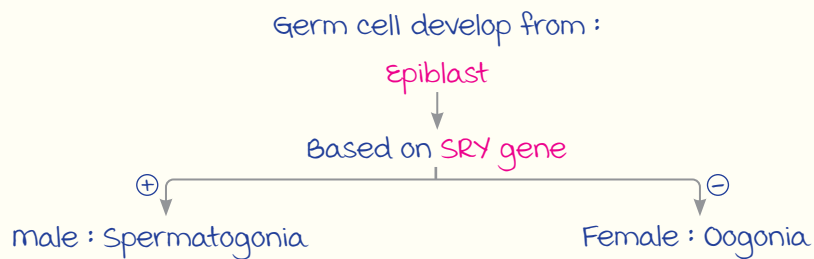
Gynaecology : Part 1	1
Gynaecology : Part 2	13
Gynaecology : Part 3	22
Gynaecology : Part 4	31
Gynaecology : Part 5	40
Gynaecology : Part 6	47
Gynaecology : Part 7	53
Gynaecology : Part 8	57
Gynaecology : Part 9	69
Gynaecology : Part 10	78
Obstetrics : Part 1	97
Obstetrics : Part 2	112
Obstetrics : Part 3	121
Obstetrics : Part 4	127
Obstetrics : Part 5	137
Obstetrics : Part 6	146
Obstetrics : Part 7	159
Obstetrics : Part 8	178

GYNAECOLOGY : PART 1

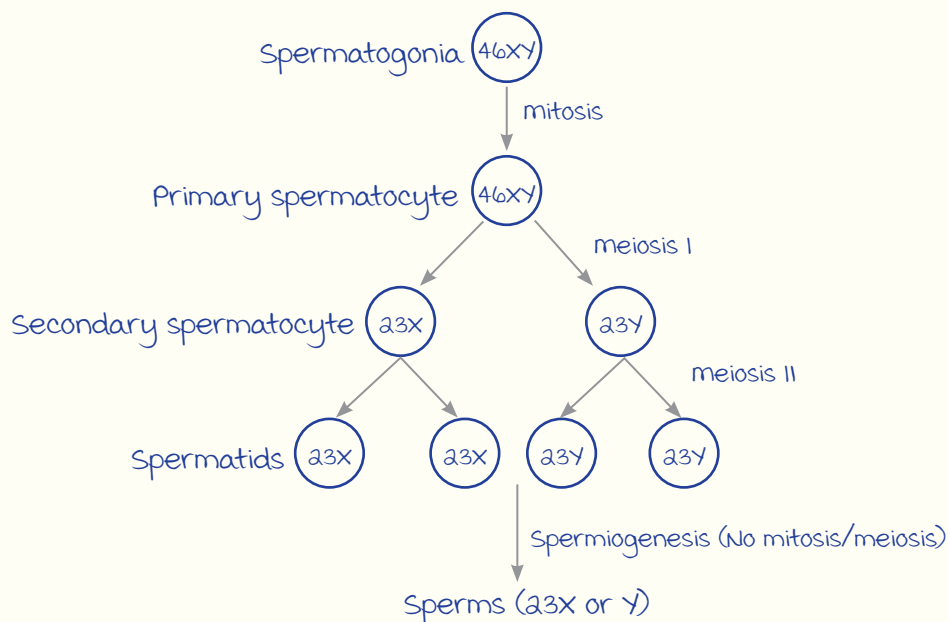
----- Active space -----

Gametogenesis

00:00:38

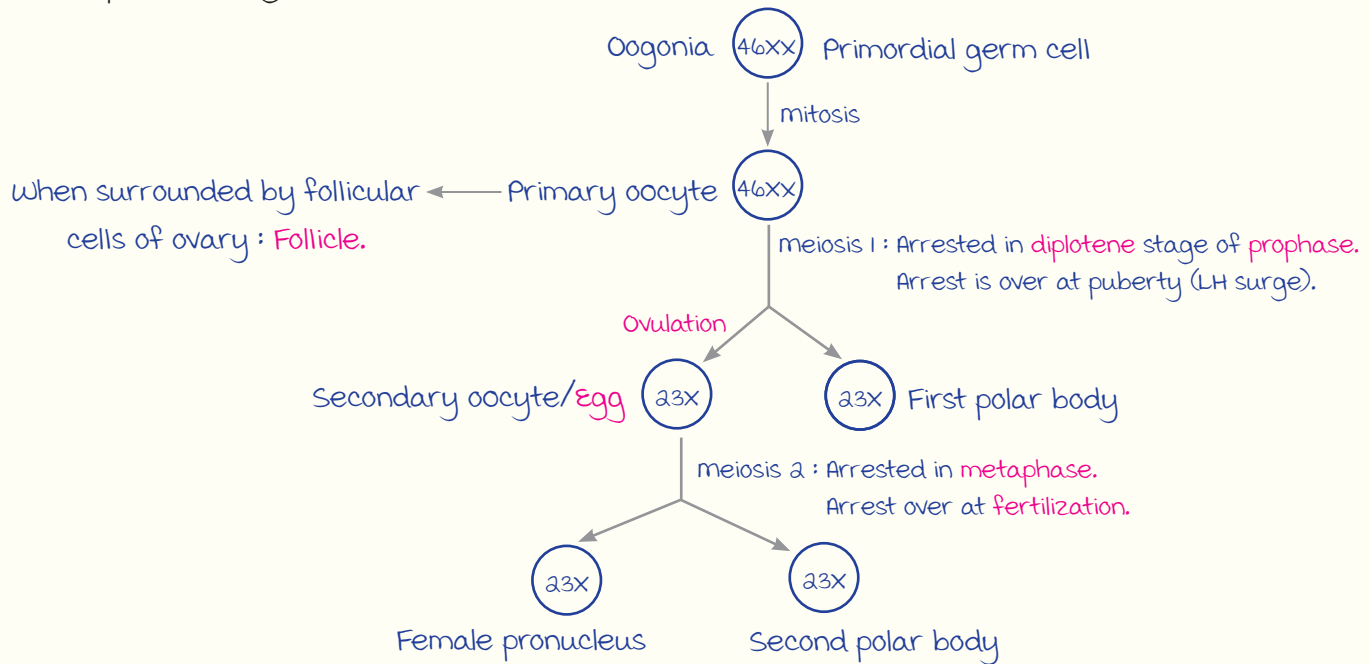


Spermatogenesis :



- Spermatogenesis begins at : Puberty.
- Spermatogenesis occurs in : Seminiferous tubules.
- Size of sperms : 50-60 microns.
- Fertilizable span : 48-72 hours.
- Time taken for spermatogenesis : 70-75 days (72 days).
- Sperms attain maturity in : Proximal end of epididymis.
- Sperms attain motility in : Distal end of epididymis.
- Time taken for sperm maturation : 12-14 days.
- Total time taken to form mature sperm : ≈ 90 days (74 + 14 days).

----- Active space ----- Oogenesis :



- Oogenesis begins : Intrauterine.
- Fertilisable span of ova : 12-24 hours.
- Size of mature follicle : 18-20 mm (Graafian follicle).
- Number of follicles :
 - maximum : 6-7 million at 5th month of intrauterine life. (20 weeks of pregnancy).
 - At birth : 1-2 million.
 - Puberty : 4-5 lakh.
- Follicles undergo apoptosis.

Menstrual Cycle

00:09:16

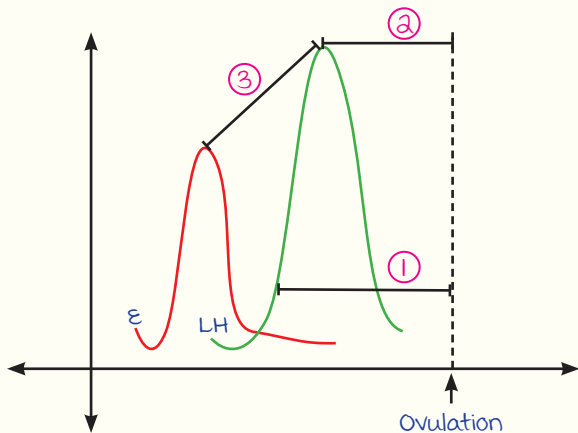
----- Active space -----

1 st half of cycle	LH surge
<ul style="list-style-type: none"> Called as : Proliferative/follicular phase. main hormone : Estrogen. Ovarian cycle is initiated by : FSH. Hormones formed by granulosa cells <ol style="list-style-type: none"> Estrogen (E_2). Inhibin B. AMH (Small antral & pre antral follicles). Estrogen effect on FSH : Negative. Estrogen effect on LH : Negative, except when >200 pg for 48 hrs \rightarrow LH surge. Inhibin effect on FSH : Negative. 	<ul style="list-style-type: none"> LH surge is initiated by : Estrogen (≥ 200 pg for 48 hrs). LH surge is maintained by : Estrogen + progesterone. Before ovulation : Both LH & FSH surge. Ovulation is due to : LH surge. LH acts on Theca cells <div style="text-align: center; margin: 5px 0;"> ↓ <div style="border: 1px solid black; padding: 2px; display: inline-block;">Androgens</div> </div> <ul style="list-style-type: none"> Androgens $\xrightarrow[\text{Adipose tissue}]{\text{Aromatase}}$ Estrogen (E_1). - In granulosa cells : Androgens \rightarrow Estrogen(E_2).

MENSTRUAL CYCLE

Ovulation
<ul style="list-style-type: none"> Primary oocyte \rightarrow Secondary oocyte/egg Follicle \rightarrow Corpus luteum
Time between
<ol style="list-style-type: none"> LH surge and ovulation : 32-36 hrs (Best), 24-36 hrs. LH peak and ovulation : 10-12 hrs. Estrogen peak and LH peak: 12-24 hrs.

2 nd half of cycle
<ul style="list-style-type: none"> AKA : Secretory/Luteal phase main hormone : Progesterone
Progesterone
<ul style="list-style-type: none"> In low concentration : +ve on LH, FSH. In high concentration : -ve on LH, FSH.
Note
Time duration of luteal phase fixed to : 14 days.



Note : Granulosa cell tumors.
Tumor markers \rightarrow Inhibin B & AMH.

----- Active space -----

Corpus Luteum :

- Corpus luteum in non-pregnant females is maintained by : LH.
- Corpus luteum in pregnant females is maintained by : hCG.
- Life span of corpus luteum in non-pregnant females : 12-16 days.
- Hormone which prevents luteolysis : hCG.
- maximum size and activity of corpus luteum is seen on : 8 days after ovulation (D-22).
- maximum progesterone is seen on : D-22.
- minimum LH & FSH is seen on : D-22.
- All tests for ovulation done on : D-22 = 1 week before menstruation.
- Day of ovulation : 14 days prior to next menstruation (Length of cycle - 14 days).
- Pain at time of ovulation (mid cycle abdominal pain) : mittelschmerz syndrome.

Dysmenorrhea :

Pain at time of menstruation.

	Primary/Spasmodic dysmenorrhea	Secondary/Congestive dysmenorrhea
Pathology	Progesterone (Relaxant) withdrawal ↓ vasoconstriction ↓ Release of $PGF-2\alpha$ → Pain. (No pelvic pathology)	Causes : Pelvic pathologies <ul style="list-style-type: none"> • Endometriosis (m/c) • Adenomyosis • Fibroid • Pelvic inflammatory disease
Presentation	Young female, c/o pain since menarche except initial few cycles (Anovulatory)	<ul style="list-style-type: none"> • Reproductive age group female (≥ 30) • c/o pain at the time of menstruation • No h/o pain
Pain location	Suprapubic area (Generalized)	Localised
Pain character	Just before or at menstruation; Relieved within 72 hours.	Begins much before menstruation, and remains after menses.
Pain progression	Pain decreases on its own : <ul style="list-style-type: none"> • After physical act. • marriage. • Child birth 	Pain increases progressively
P/v	Ⓝ	Abnormal
Rx	<ul style="list-style-type: none"> • NSAIDs or • OCPs (makes the cycles anovulatory) 	manage the cause

Drugs in Gynaecology

00:23:14

----- Active space -----

Third generation/Artificial progesterone	Drugs for endometriosis/dysmenorrhea (Hyperestrogenic condition : Rx → ↓ Estrogen)
<ul style="list-style-type: none"> As generation increases : Androgenic side effects decrease. Third generation : <ul style="list-style-type: none"> - Desogestrel - Norgestimate - Gestodene Least androgenic side effect 4th generation : Cyproterone acetate (Anti androgenic) 	<p style="text-align: center;">minimal-mild :</p> <ul style="list-style-type: none"> 1st line : NSAIDs/OCs. 2nd line : Progesterone (Downregulates estrogen receptor). 3rd line : GnRH continuous. If no relief : Laparoscopic management. <p style="text-align: center;">moderate-severe :</p> <ul style="list-style-type: none"> 1st line : Continuous GnRH. If no relief : Laparoscopic management.

DRUGS IN GYNAECOLOGY

Hirsutism :
Hair growth in male pattern + Alopecia + Acne


- Seen in : ↑ Androgen
 - Androgen secreting tumors
 - PCOS
 - CAH
- Score : Ferriman Gallwey (≥8).
- 1st line :
 - ↓ Androgen production
 - ⊖ LH ← E + P ← OCP : DOC

In case of conception, spironolactone can affect external genitalia of a male fetus. Hence **OCs are added.**

Spironolactone + OCP
(Antiandrogenic)

↓ 6 months (Not before)

- Alternative :
 - Flutamide.
 - Ketoconazole.
 - Finasteride.
 - Cyproterone acetate.
- Topical : Eflornithine.
- Last resort : Continuous GnRH (↓ LH & FSH).



Virilisation :

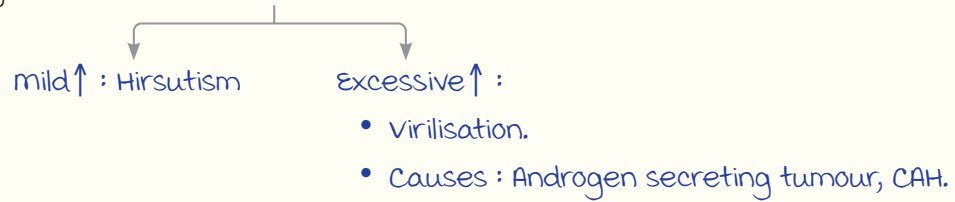
1. Clitoromegaly.
2. Breast atrophy.
3. Deepening of voice.
4. muscle mass ↑.
5. Hirsutism.

----- Active space -----

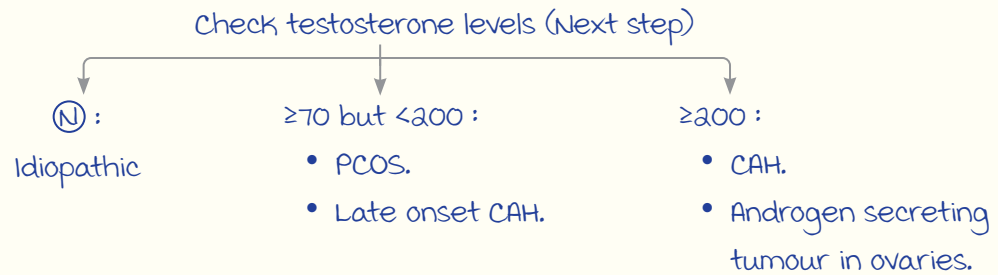
Note :

Drug not used for hirsutism : **Danazol** (Causes hirsutism).

Androgens in females :




Female with hirsutism :



- m/c cause of hirsutism in young : PCOS.
- m/c cause of rapid onset hirsutism in young females : Androgen secreting tumour of ovaries.

----- Active space -----

SERM : Selective Estrogen Receptor modulator
Clomiphene :
• Use : Ovulation induction (If HPO axis intact i.e FSH \uparrow).
• most common side effect : Hot flushes.
• 2 nd most common side effect : Formation of ovarian cyst.
• Chances of multiple pregnancy : 7-10%.
• Side effect because of which its use should be stopped immediately : Visual disturbances.
• Common S/E : vaginal dryness

Raloxifene
• Use : Osteoporosis.
• Side effect : Hot flushes, vaginal dryness.
Tamoxifen
• Use : Breast cancer.
• Side effect : Hot flushes, vaginal dryness.
Leads To : Endometrial Ca.
 minimum time gap between tamoxifen & pregnancy : 2 months. Ideal gap : 3 months. } Teratogenic.

Ospemifene :
mx vaginal dryness.

Ormiloxifene :
Component of centchroman (Chhaya).

DRUGS IN GYNAECOLOGY

Drugs for Fibroid :
1 st line : D's which decrease bleeding but NOT size of fibroid
1. Tranexamic acid.
2. OCP.
3. Progesterone.
2 nd line : D's which decrease size of fibroid & bleeding
Drugs Decrease Estrogen :
1. Letrozole (Androgen $\xrightarrow{\text{Aromatase}}$ Estrogen)
2. Danazole (S/E : Hirsutism)
3. GnRH analogues (Continuous)
4. GnRH antagonist
Progesterone :
1. SPRM : Ullipristal (Also as emergency contraceptive)
2. Progesterone antagonist : mifepristone (RU 486 : medical abortion).

GnRH :
Synthetic Analogue : Leuprolide, Goserelin.
Route :
• S/c injections. } (Orally inactive).
• Intranasal spray. }
Uses : Pulsatile = \uparrow E, \uparrow LH, \uparrow FSH
1. Delayed puberty.
2. Kallmann syndrome.
3. Anovulation.
Continuous GnRH = \downarrow E, \downarrow androgen, \downarrow LH, \downarrow FSH.
1. Fibroid
2. Endometriosis
3. Precocious puberty
4. Hirsutism
5. ER +ve breast cancer
6. Prostate cancer

Rx : Hyper estrogenic conditions.

SPRM : Selective Progesterone Re-uptake modulator.

----- Active space ----- Note :

GnRH antagonist.

- Elagolix.
 - Cetrorelix.
- } usually active but expensive.
- used same as continuous GnRH.

Abnormal Uterine Bleeding

00:45:34

Normal characteristics of menstrual cycle :

- Length of cycle : 24-38 days (Old : 21-35 days).
- No. of days bleeding : 4.5-8 days (Old : 2-8 days).
- Volume of blood loss : 20-80 mL.
- Cycle to cycle variation : 2-20 days.

Abnormal Uterine Bleeding

Any deviation from normal characteristics of menstrual cycle.

Causes : **PALM COEIN.**

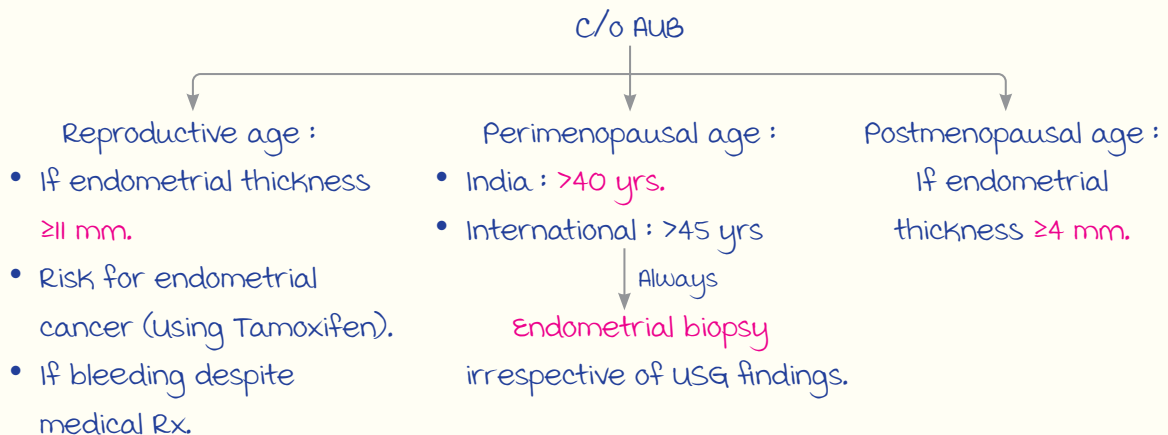
- Polyp.
- Adenomyosis.
- Leiomyoma.
- malignancy/hyperplasia.
- Coagulopathy.
- Ovulatory dysfunction.
- Endometrial cause.
- Iatrogenic.
- Not yet classified.

Investigation :

- 1st : uPT except post-menopausal/virgin female.
- 2nd : TVS except puberty menorrhagia (D/t anovulation > coagulopathy).
- 3rd : Endometrial biopsy.

Endometrial Biopsy/Endometrial Aspiration Cytology/Endometrial Sampling

Indications :



Uses :

----- Active space -----

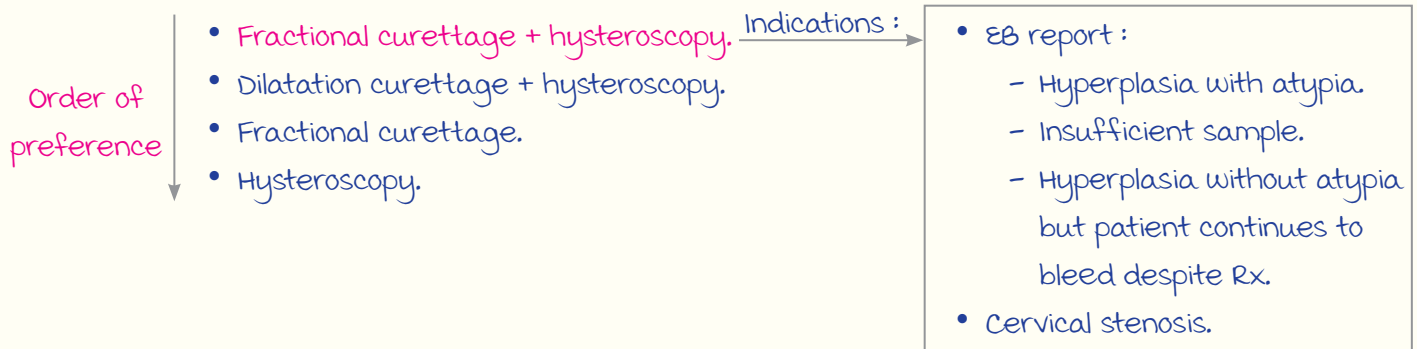- Endometrial hyperplasia/cancer : **IOC**.
- Lynch syndrome : Screening.
- Genital TB diagnosis.
- Couples with anovulation
 - Ovulated : Glands coiled (**Corkscrew/sawtooth** appearance).
 - Non-ovulated : Simple tubular glands.
- Late menopause (Long estrogen exposure).

Procedure :

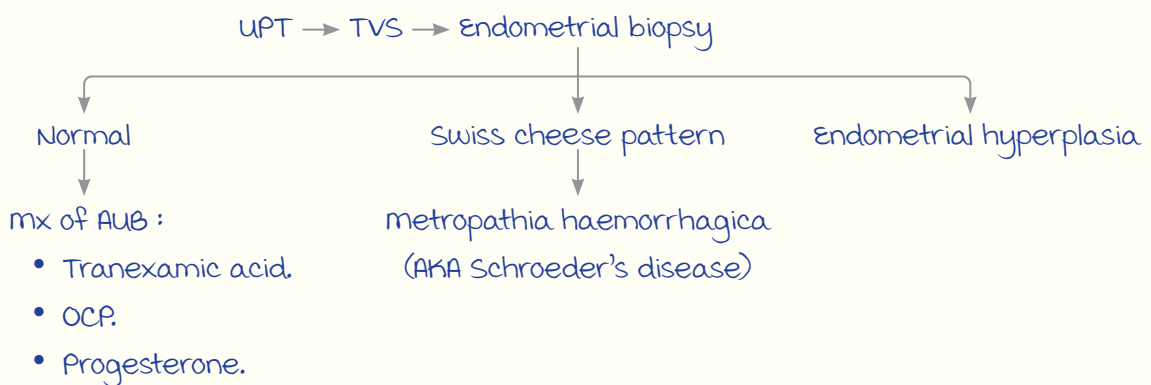
- Instrument :
 - **Pipelle/vabra** aspirator (Worldwide).
 - **Karman** cannula (India).
- Time : 2-3 days prior to menstruation.

Note :

Endometrial pathology gold standard :



Perimenopausal Bleeding :

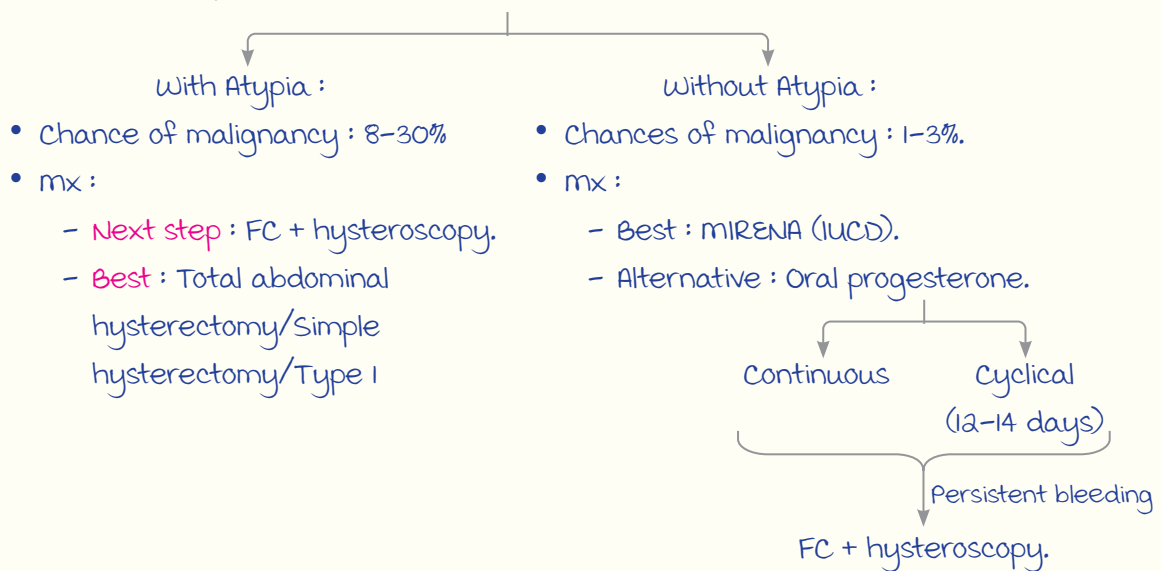


If bleeding persists : Fractional curettage + hysteroscopy ↓ GA in OT.

metropathia hemorrhagica :

- Age : Perimenopausal female.
- C/o : 2-3 months of amenorrhea $\xrightarrow{F/b}$ Bleeding.
- Cause : Anovulatory cycles (↓ Progesterone).
- Risk of malignancy : 1.1%
- Rx : Progesterone.

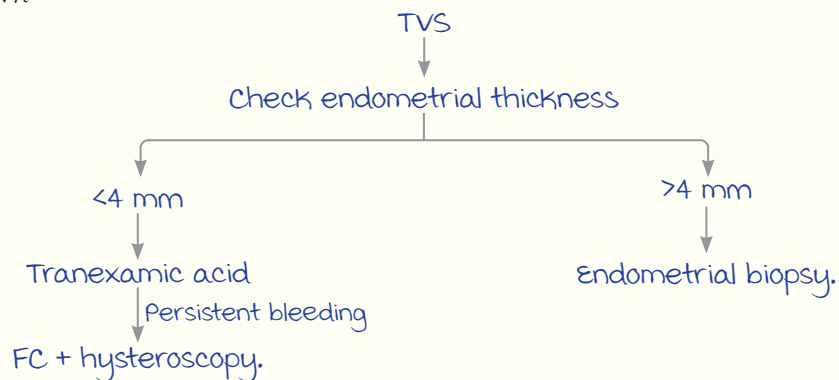
----- Active space ----- Endometrial hyperplasia :



Postmenopausal Bleeding :

- m/c cause : Polyp (37%).
- 2nd m/c cause : Endometrial atrophy/Senile endometriosis (30%).
- m/c cause in India : Cervical cancer.

management :



Menopause

01:06:02

----- Active space -----

Age worldwide : 51 yrs.

Age India : 47 yrs.

POI/Premature menopause : menopause <40 yrs
(Primary ovarian insufficiency).

Late menopause : Not achieved at ≥55 yrs.

Diagnosis : Clinical, amenorrhea ≥12 months.

Diagnosis of POI : FSH levels

- (N) : 1-10 IU.
- Suggestive : ≥25 IU.
- Diagnostic : ≥40 IU.

Hot Flashes :

Vasomotor symptom.

Due to : ↓Estrogen.

Imbalance in : Serotonin & norepinephrine.

more at : Night (Night sweats).

Feeling of : Intense heat f/b sweating

Severe hot flush : Affects daily activities.

Seen in : Perimenopausal & menopausal females.

Management :

- HRT : Severe hot flashes.
- SSRI : Fluoxetine.
- Others : Phytoestrogens, clonidine, gabapentine, tibolone.

Drugs not used : Clomifene, raloxifene, tamoxifen.

SERM approved : ε + Bazedoxifene.

MENOPAUSE

Osteoporosis :

- ↓Estrogen, quantitative defect.
- C/o backache.
- m/c fractures : vertebral > Neck of femur > Colle's fracture.
- Compulsory bone mineral density check : Dexa scan (IOC).
- management :
 - Bisphosphonates : Alendronate (1st line).
 - SERM : Raloxifene.
 - Others : Tibolone, teriparatide (PTH analogue), strontium, denosumab (RANK ligand ⊖)
 - Drugs on osteoblasts : Teriparatide, strontium.

Senile vaginitis/Genitourinary Syndrome of menopause :

- Due to : ↓Estrogen.
- Patient c/o : vaginal dryness, spotting, dyspareunia.
- management :
 - 1st line : vaginal lubricants.
 - 2nd line : HRT (Estrogen cream).

⊖ SERM used : Ospemifene.

SERMs not used : Clomiphene, Raloxifene, Tamoxifen

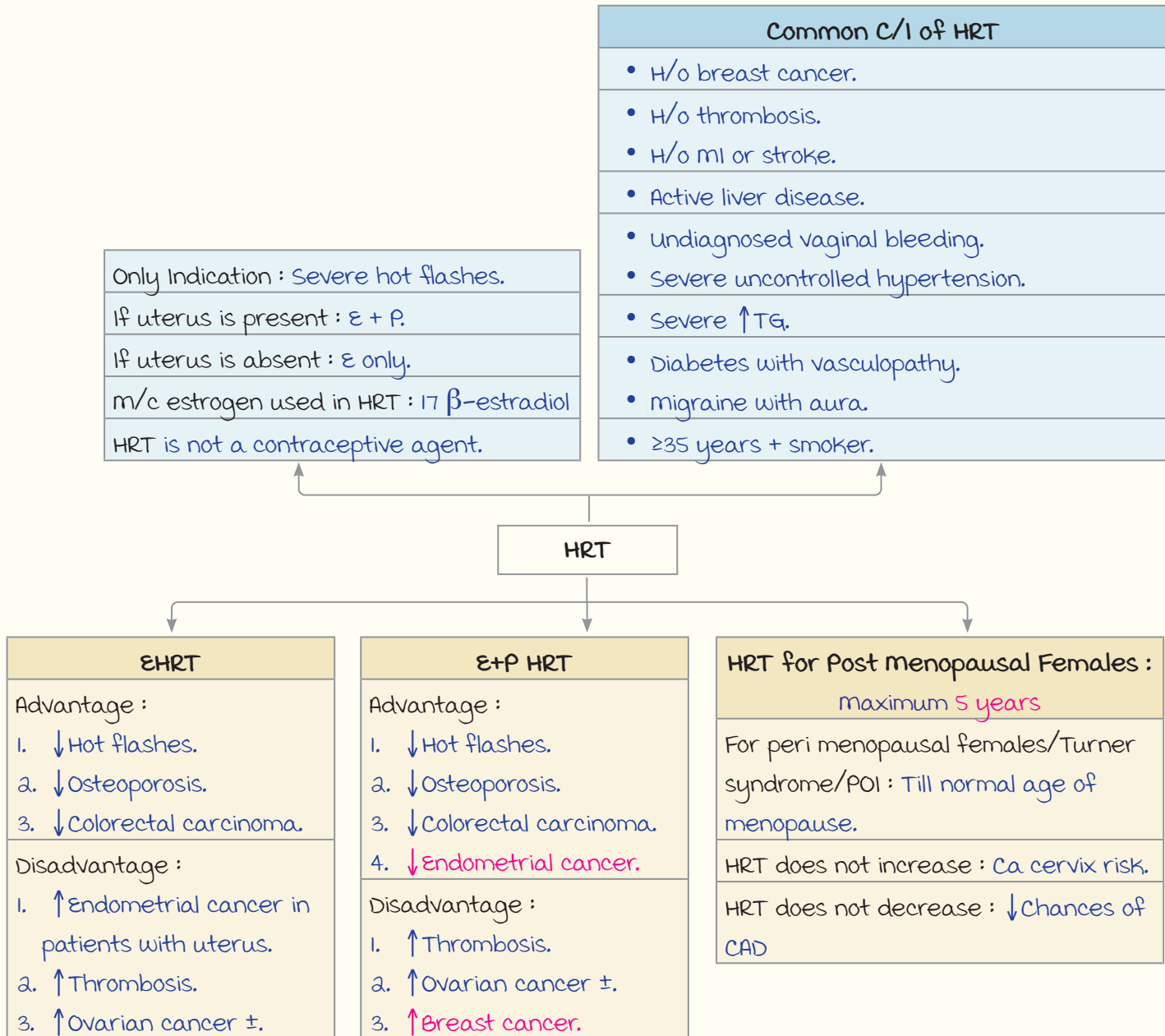
Coronary Artery Disease :

- Estrogen is cardioprotective (↑HDL, ↓LDL).
- After menopause ↑CAD risk but HRT not given for prevention.
 - In females ≥60 y : HRT slightly ↑ses risk.
 - ε + P HRT ↑ses risk > ε only HRT.

----- Active space -----

Hormone Replacement Therapy

01:16:01



GYNAECOLOGY : PART 2

----- Active space -----

PCOS

00:00:06

Primary Pathology :

↑ androgen production by ovaries.

(N) Androgen levels in females : <70ng/dL.

In PCOS : 70-120 ng/dL.

Due to ↑ androgen :

1. Hirsutism.
2. It is folliculotoxic.
3. No follicular maturation → Anovulation. → No corpus luteum → No progesterone.
 - Patient c/o infertility, 2° amenorrhoea.
 - ↑ chances of abortion.

Additional Features :

1. Insulin resistance.
2. Obesity.
In Obese PCOS females :
E1 : E2 =
- 2:1 d/t androgen $\xrightarrow{\text{Adipose tissue}}$ E1.
- (N) → 1:2.
Also c/o : menometrorrhagia.

3. Abnormal Gonadotropin Secretion :

- LH : ↑.
FSH : (N).
Normally LH : FSH : 1:1.
In PCOS patients : 2:1 / 3:1.
Test for FSH is done on : Day 2 or day 3 of menstrual cycle.

4. HAIR-AN Syndrome :

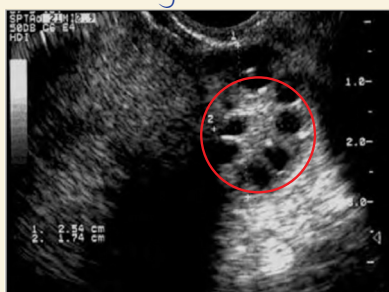
- HA : Hyperandrogenism.
IR : Insulin resistance.
AN : Acanthosis nigricans.

PCOS

Rotterdam Criteria :

Any 2 of the following 3 should be present :

1. Androgen levels : ↑
- ↑ testosterone (Biochemically) or hirsutism.
2. Ovulatory dysfunction :
- Oligomenorrhoea (<9 cycles/year) or amenorrhoea.
3. On USG :
- Follicles (In one/both ovaries) : Number ≥12,
size : 2-9 mm or
- Volume of ovary : ≥10cc



Lab Findings Increased :

1. Testosterone.
2. DHEA.
3. LH.
4. LDL.
5. Estrogen : In obese females.
6. AMH.

Decreased :

1. Progesterone.
2. SHBG.

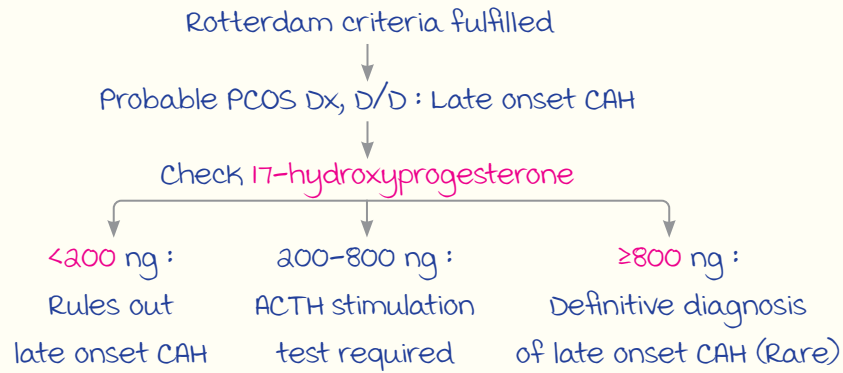
Unchanged :

1. FSH.
2. Prolactin.

Progesterone Challenge Test

----- Active space ----- Note :

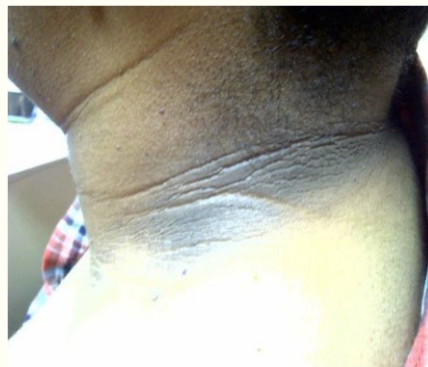- Necklace pattern (Follicles arranged around periphery of ovary in PCOS) **not** included in Rotterdam criteria.
- European/American society : **>20 follicles** is diagnostic.



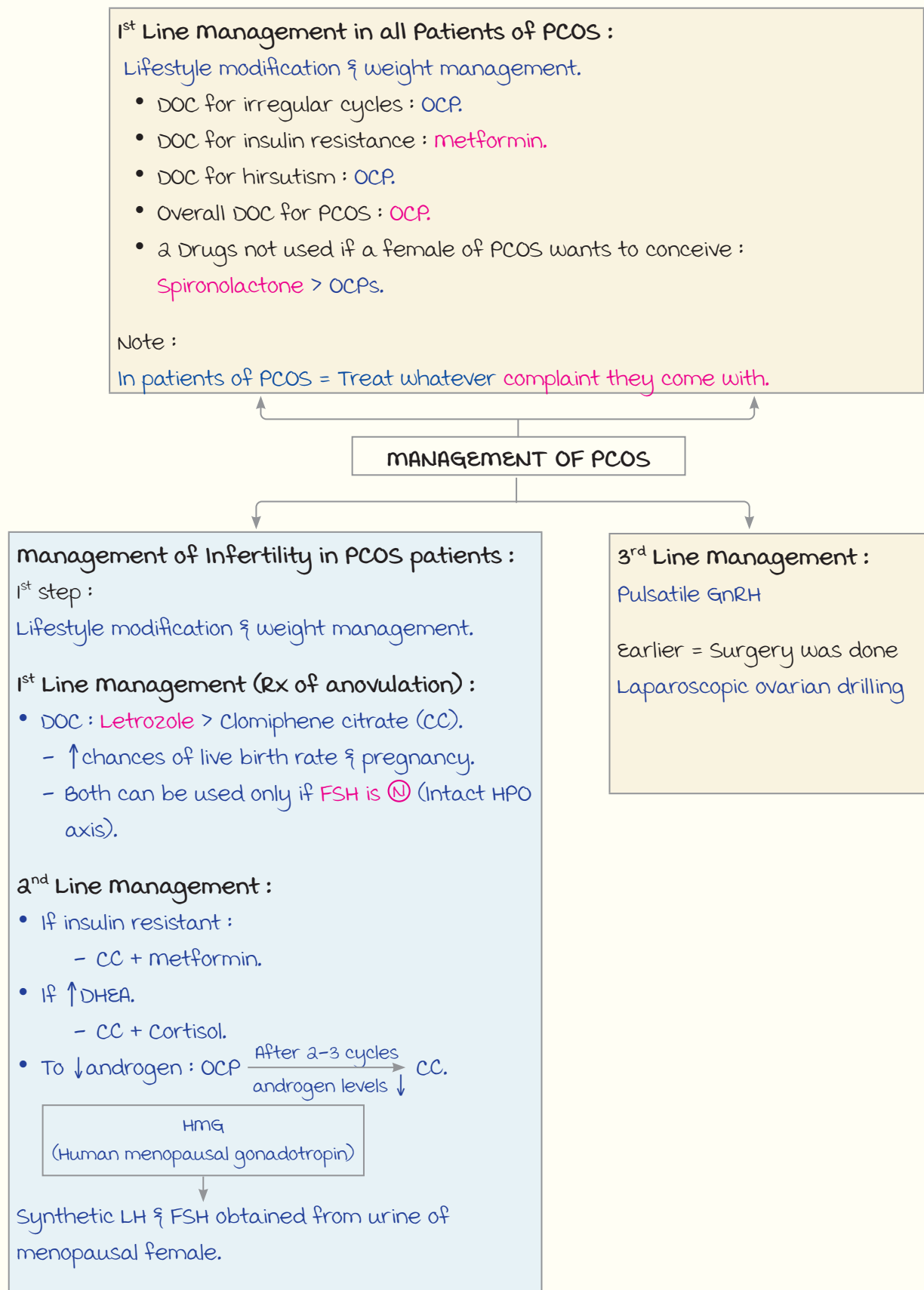
- PCOS vs Ovarian Hyperstimulation Syndrome (OHSS) USG :

	PCOS	OHSS
Follicle	Small, 2-9mm	Large
Stroma	Visible, hyperechoic	Not visible

Acanthosis nigricans at nape of neck :



----- Active space -----



----- Active space -----

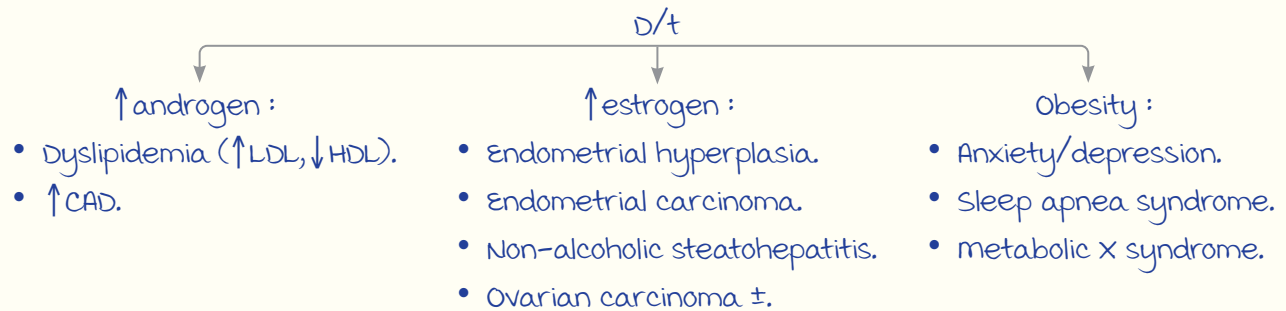
Laparoscopic ovarian drilling :

- Principle :
Burn stroma of ovary
↓
Destroy theca cells
↓
↓ androgen

- Advantage : No ↑ chances of twin pregnancy & OHSS.

- Disadvantages : may lead to premature ovarian insufficiency (POI).

Long term complication of PCOS :



Note :

- Complication not seen : Osteoporosis (In PCOS : E levels are never ↓).
- Endometrial hyperplasia → AUB (M).
- Hirsutism scoring system : Ferriman Gallwey score → ≥8 : Significant (>6 in Asian females).



Ashermann Syndrome

00:18:47

----- Active space -----

<ul style="list-style-type: none"> • Pathology : <ol style="list-style-type: none"> 1. Intrauterine adhesions. + 2. Thin defective endometrium. • m/c cause : Excessive curettage. • maximum risk : In postpartum period. • Other causes : <ul style="list-style-type: none"> - Excessive D & C. - Genital TB. 	<ul style="list-style-type: none"> • m/c symptoms : <ul style="list-style-type: none"> - Group of symptoms : menstrual irregularities - Single symptoms : Infertility > 2° amenorrhea > hypomenorrhea (Scanty bleeding). • 1st investigation : <ul style="list-style-type: none"> - HSG : Filling defect. • IOC : <ul style="list-style-type: none"> - Hysteroscopy : Diagnostic + therapeutic.
--	--

ASHERMAN SYNDROME

<p>On HSG :</p>  <p>moth eaten appearance : multiple filling defects with irregular margins.</p> <p>Note :</p>  <p>Polyp/fibroid : Single filling defect + smooth regular margins.</p>	<ul style="list-style-type: none"> • LH. • FSH. • Estrogen. <p>} (N)</p> <ul style="list-style-type: none"> • Progesterone challenge test : Negative (No bleeding). • E+P challenge test: Negative . 	<p>management :</p> <ol style="list-style-type: none"> 1. Hysteroscopic adhesiolysis + 2. Insert paediatric foleys catheter (Prevent adhesion formation) + 3. E + P for 3 months (To build the endometrium)
---	---	---

Secondary Amenorrhea



Absence of menstruation for **3 months/90 days** in a previously normally menstruating female.

Causes :

- Pregnancy (m/c cause).
- Thyroid disorders.
- ↑ prolactin levels.

Tests :

- UPT.
- Prolactin level.
- TSH level.
- LH, FSH & E levels.

Organ	Condition	Features	Hormonal assay	Other Ix
Hypothalamus ↓ GnRH	-	Causes : • Anorexia • Bulimia • ↑ physical exertion • Stress	-	mRI : (N)
Pituitary ↓ LH ↓ FSH	 Sheehan's syndrome	• Necrosis of anterior pituitary d/t PPH • Symptoms : - Inability to breast feed (m/c) - Persistent amenorrhoea (2 nd m/c)	• GH : ↓ (First) • LH, FSH, E : ↓ • Prolactin : ↓ • TSH : ↓ (Last)	mRI : Empty sella tursica
	Prolactinoma	• Prolactin secreting pituitary adenoma • Symptoms : - Secondary amenorrhoea (m/c) - Infertility (2 nd m/c) - Galactorrhea - Headache, visual disturbances	• LH, FSH, E : ↓ • GnRH : ↓ • Prolactin : ↑	• mRI : Space occupying lesion Note : • DOC : Cabergoline • In pregnancy & lactation : Treat only if visual disturbance ⊕
Ovary ↓ E ↓ P	POI	• Absent follicles • No ovulation (↓ E & P) • Symptoms : Hot flushes, osteoporosis	• LH, FSH : ↑ • E, P : ↓ • AMH : ↓ ((N) level : 1-3) - <1 : Suggestive of POI - <0.5 : Diagnostic of POI	-
	PCOS	• Secondary amenorrhoea • Hirsutism • Insulin resistance	• FSH : (N) • LH : ↑ • E : Normal/↑ • AMH : ↑	Progesterone challenge test : Positive
Uterus	 Asherman syndrome	• Infertility • Secondary amenorrhoea • Hypomenorrhoea	• FSH, LH : (N) • E : (N)	Challenge tests : • P } Negative • E + P }

Note : \uparrow LH, FSH $\text{\textcircled{N}}$ conditions.

- PCOS \rightarrow **Secondary** amenorrhea.
- Androgen insensitivity syndrome \rightarrow **Primary** amenorrhea.

----- Active space -----

Pituitary Apoplexy $\text{\textcircled{STP}}$

00:37:52

Acute infarction/hemorrhage of pituitary gland in a patient with undiagnosed pituitary adenoma.

Precipitating factors :

- **PPH.**
- Acute shock.
- Hypertension.
- DM.

Presentation :

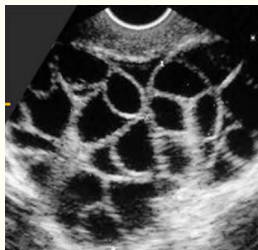- H/o post partum shock.
- C/F :
 - Headache & visual disturbance (D/t adenoma).
 - Hypoglycemia (D/t \downarrow cortisol).

Ix : All pituitary hormone \downarrow .

Treatment :

- 1st line : **Corticosteroid** supplementation $\xrightarrow{F/b}$ Thyroid hormone, sex steroid, vasopressin & GH.
- Indications for Sx : Progressive visual loss, cranial nerve involvement & loss of consciousness.

Note : OHSS vs molar pregnancy



USG : OHSS

USG findings :

- Large follicles.
- \uparrow no. of follicles.
- No stroma.

H/o infertility + IVF (HMG use) \rightarrow OHSS

UPT \oplus , c/o bleeding in 1st trimester/early 2nd trimester, β HCG \uparrow \rightarrow Theca lutein cysts (molar pregnancy)

Ovarian Hyperstimulation Syndrome (OHSS) $\text{\textcircled{STP}}$

00:43:50

- Iatrogenic complication.
- max risk with : **HMG** > CC.
- Not caused by : **Letrozole.**

Etiopathogenesis :

hCG (Ovulation trigger with HMG use) \rightarrow multiple follicles mature \rightarrow \uparrow VEGF \rightarrow \uparrow Capillary permeability.

----- Active space -----

Risk factors :

- PCOS.
- Thin females.
- Pregnancy.
- Young age.
- S. estradiol : >2500 pg.
- AMH : >3.3.
- >20 follicle, >10 mm size.

Note :

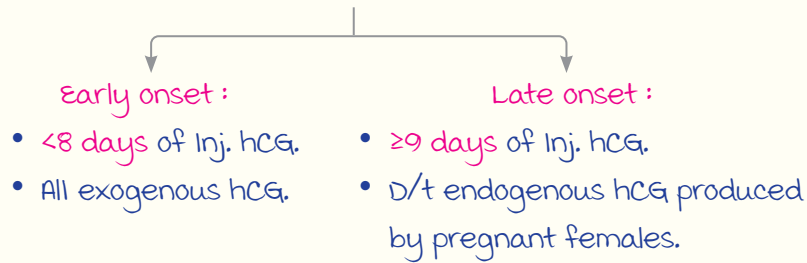
Indication for metformin in PCOS :

- Insulin resistance.
- HMG use (Decrease risk of OHSS).

Prevention :

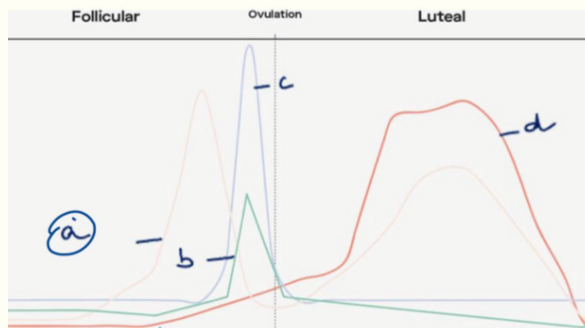
- monitor follicular number & size, estrogen (E₂) levels.
- Stop gonadotropins.
- Do not give inj. hCG for ovulation if E >2500 pg.
- Give : Cabergoline (↓VEGF).

Classification of OHSS :



mild	Abdominal pain, nausea, vomiting
moderate	USG : Ascites or ovarian enlargement
Severe	Clinical : Ascites & hypovolemia features
Critical	Sign of end organ damage ⊕

Note : menstrual cycle



- Peak Hormone
- a : Estrogen.
 - b : FSH.
 - c : LH → LH surge is responsible for ovulation.
 - d : Progesterone.

ESTROGENS :

Potency (५७) :

Ethinyl estradiol (EE) > Conjugated equine estrogen (CEE) > E2 > E1 > E3

Synthetic estrogens

Physiological estrogens

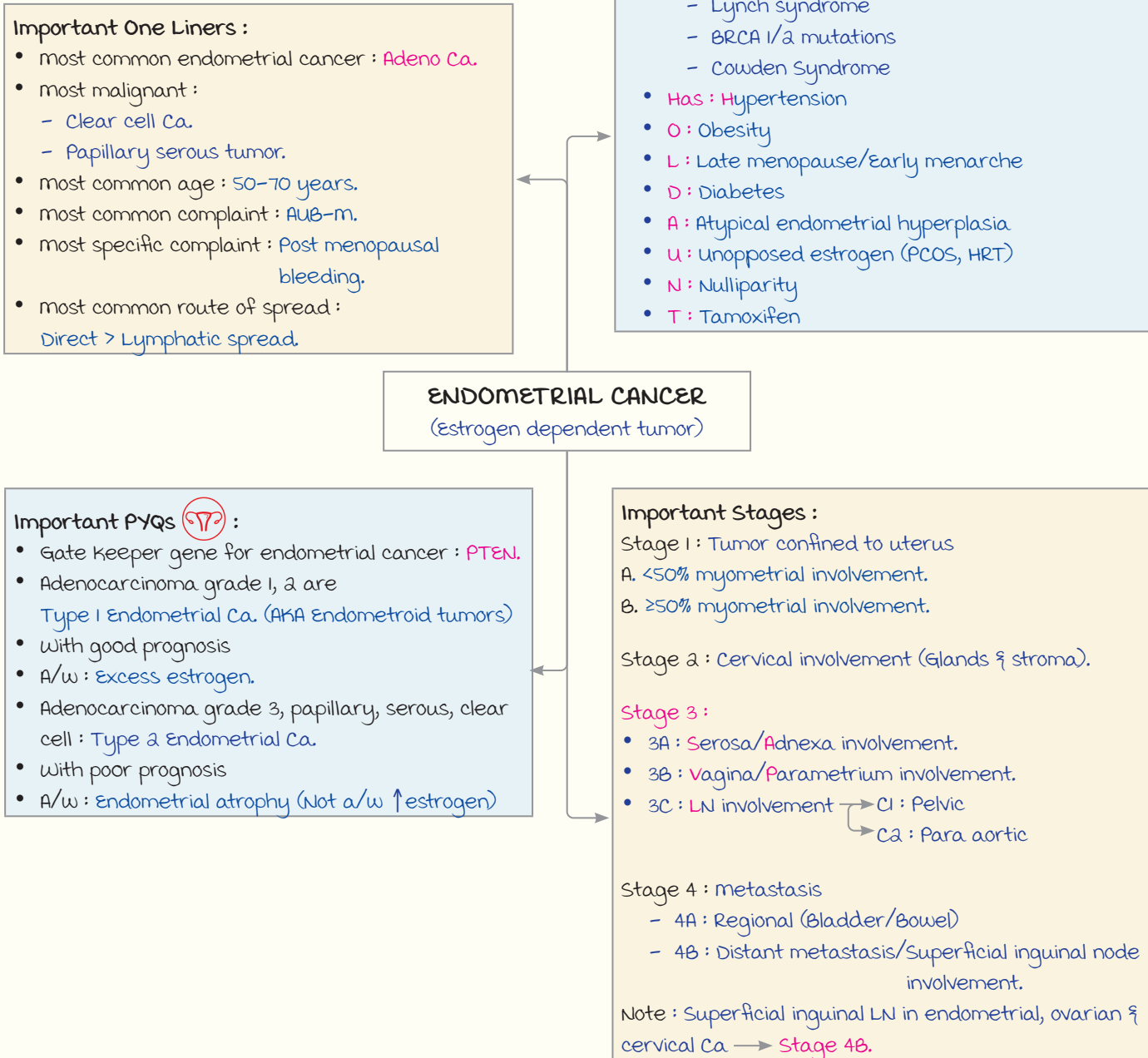Condition	Estrogen
m/c synthetic E in OCP	E.E.
m/c synthetic E in HRT	17 β estradiol
m/c E in reproductive age female	E2 (Estradiol)
m/c E in menopausal female	E1 (Estrone)
m/c E in pregnancy	E2
most specific E in pregnancy	E3

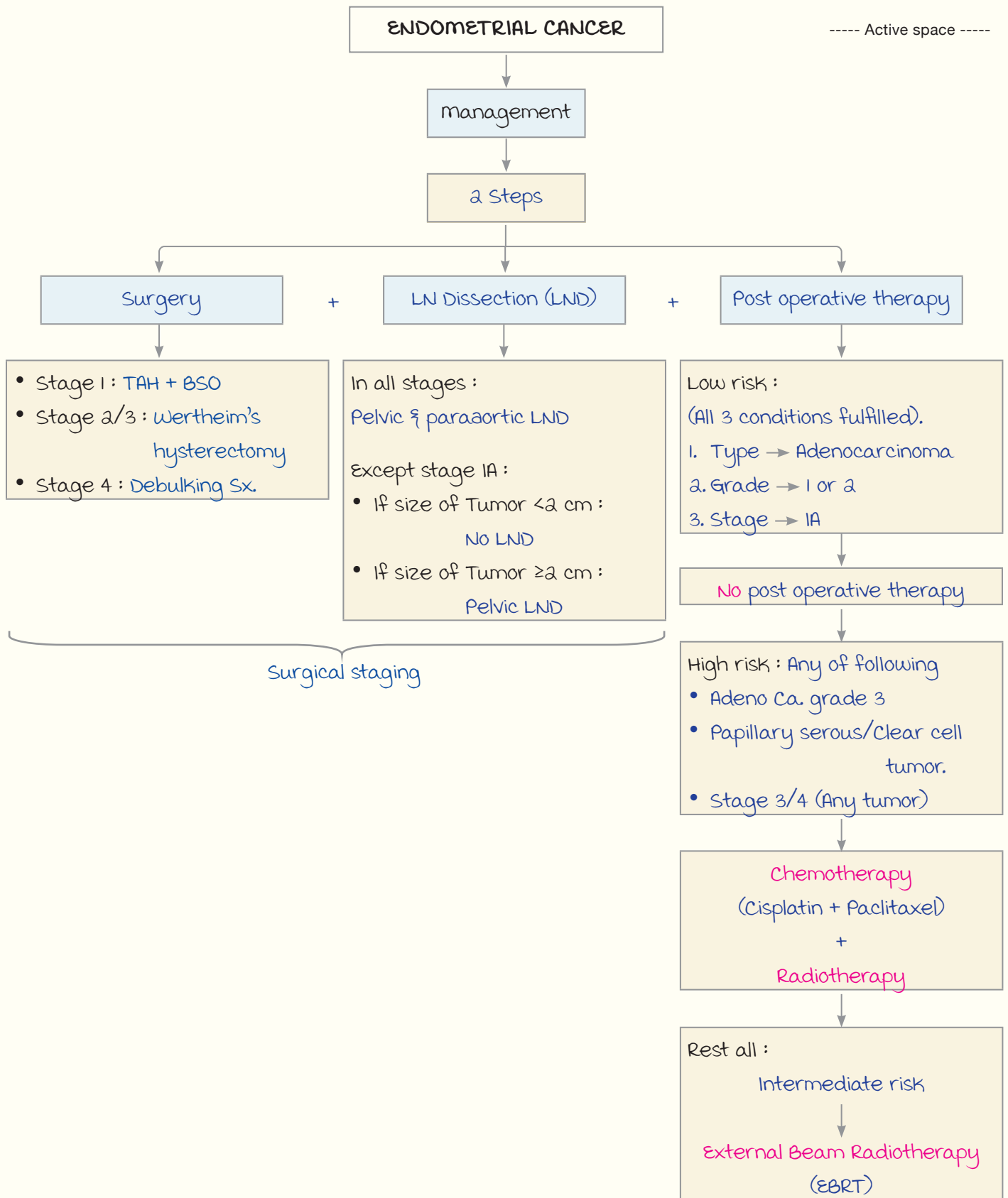
----- Active space -----

GYNAECOLOGY : PART 3

Endometrial Cancer

00:01:10





Cervical Intraepithelial Neoplasia

00:13:15

----- Active space -----

- CIN is a premalignant lesion of cancer cervix
- It indicates the presence of dysplasia
- CIN 1 : Dysplasia involving $<1/3^{\text{rd}}$ Cervical epithelial thickness (1% malignancy risk)
- CIN 2 : Dysplasia involving $1/3^{\text{rd}} - 2/3^{\text{rd}}$ of cervical epithelial thickness. (5% malignancy risk)
- CIN 3 : Dysplasia involving $\geq 2/3^{\text{rd}}$ of cervical epithelial thickness. (But not entire epithelium) (15%-30% malignancy risk)
- Ca-insitu : When entire epithelium is dysplastic but overlying membrane is intact.
- Invasive Ca. cervix : Overlying membrane is disrupted.

Age group :

- CIN : 21-30 years.
- Ca-insitu : 30-35 years.
- Cancer cervix → 35-39 years.
→ 60-65 years.

Please note :

ACOG recommends : Screening from
21-65 years.

WHO recommends : 30-50 years.
(High risk age group)

CIN

LEEP/LLETZ :

- OPD Procedure.
 - No admission needed.
 - 10 mins procedure.
 - A wire loop used which cuts & coagulates at the same time.
 - minimum bleeding.
 - Cuts 10 mm deep epithelium.
 - Adv : Tissue sample obtained for HPE.
- Note : Hysterectomy is **not done** for CIN.

- CIN is diagnosed on : Biopsy
- Pap smear : Cytologic test diagnoses dysplasia, but not CIN (Screening test).

management of CIN :

- CIN 1 : Observation for 2 years
→ unresolved → Cryoablation.
- CIN 2/3 : LEEP/LLETZ

Cryoablation : Only for CIN 1

- Done in OPD.
- Using Cryogun.
- Side effect : Persistent watery discharge.
- No bleeding.
- Removes 5 mm deep epithelium.

Note :

LEEP → Loop Electro Excisional Procedures.

LLETZ → Large Loop Excision of Transformation Zone

Risk Factors

00:19:40

----- Active space -----

Note : Cancer Cervix

- m/c : SCC > Adeno Ca.
- m/c site
 - Ca. Cervix : Transformation zone (At external OS)
 - Adeno Ca. : Endocervix.
- Cervavac :
 - First Indian vaccine against Ca. Cervix.
 - Prepared in Serum Institute of India, Pune.

Risk Factors :

1. HPV
2. Early coitarche (<18 years)
3. Early age of 1st pregnancy (<20 years)
4. Multiple partners
5. Multiparity
6. HIV
7. Low socio-economic status
8. Smoking
9. OCP :
10. No role of :
 - a. Early menarche/Late menopause
 - b. Familial inheritance
 - c. HRT : Does not ↑ risk of Ca. cervix.

HPV :

- It is epitheliotropic.
- Brings about koilocytosis **Biopsy** → Shows CIN I.
- Low risk subtype :
 - a. HPV 6
 - b. HPV 11
- Leads to :
 1. Genital warts (DOC in pregnancy : Trichloroacetic acid)
 2. Laryngeal papillomas
- High risk subtype :

16, 18, 31, 33, 45, 52, 58
- Leads to female cancers : Cervix, vulva, vagina.
- Leads to male cancers : Penis, anus, oral.

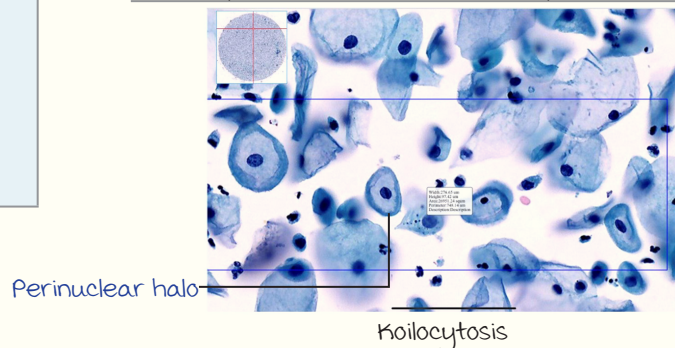
RISK FACTORS FOR CIN & CANCER CERVIX

HPV vaccines :

- Types :
 - Nonavalent : Gardasil 9 (m/c in USA).
 - Quadrivalent : Gardasil/Cervavac.
 - Bivalent : Cervarix.
- Ideal age : 11-12 years.
- Age group : 9-26 years.
- High risk : 27-45 years.
- C/I : Pregnancy.
- most common side effect : Syncope.
- HPV vaccine can be given to :
 - a. HPV Positive females
 - b. HIV Positive females
 - c. Sexually active females
 - d. Boys
- HPV testing before vaccine : Not recommended.

Important PYQs (57) :

- Sage recommendations for HPV vaccine :
 - 9 to 20 years old : 1/2 doses.
 - ≥21 years old : 2 doses.
 - HIV +ve : 3 doses.
- HPV vaccines made from : L1 capsid proteins.
- HPV proteins for malignant transformation :
 - E6 : Knocks out p53 gene.
 - E7 : Knocks out Retinoblastoma gene.
- HPV proteins needed for viral replication : E1 & E2.

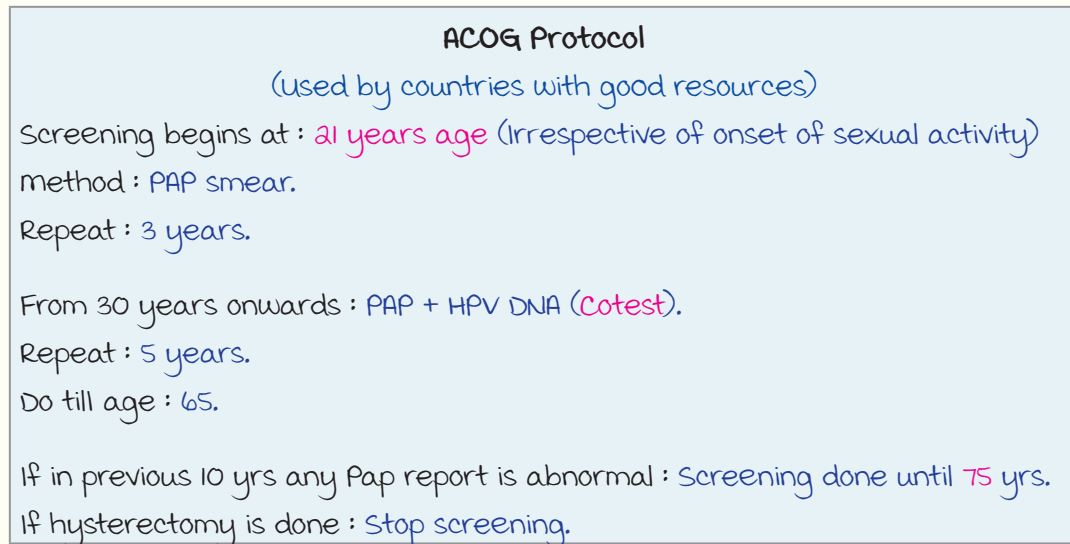


----- Active space ----- **HPV Vaccines :**

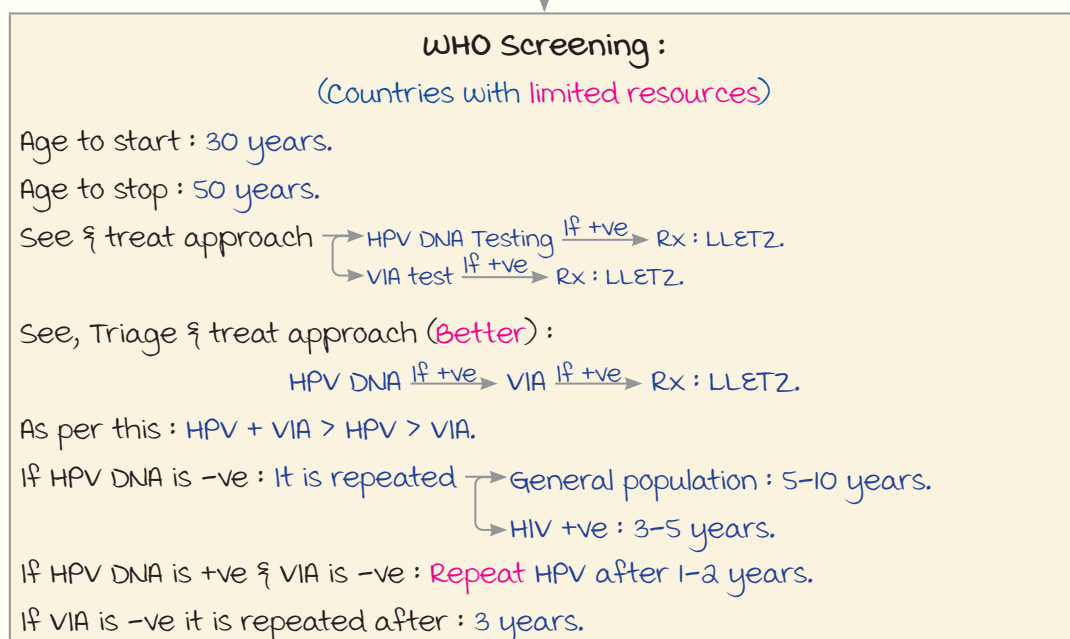
	Active against HPV	Protect against
Nonavalent	6, 11, 16, 18, 31, 33, 45, 52, 58	Genital warts + all 6 Ca. a/w HPV
Bivalent	16, 18	Ca. Cervix
Quadrivalent	6, 11, 16, 18	Genital warts & Ca. cervix

ACOG Protocol

00:28:28



SCREENING FOR CANCER CERVIX



WHO Goals for 2030 :

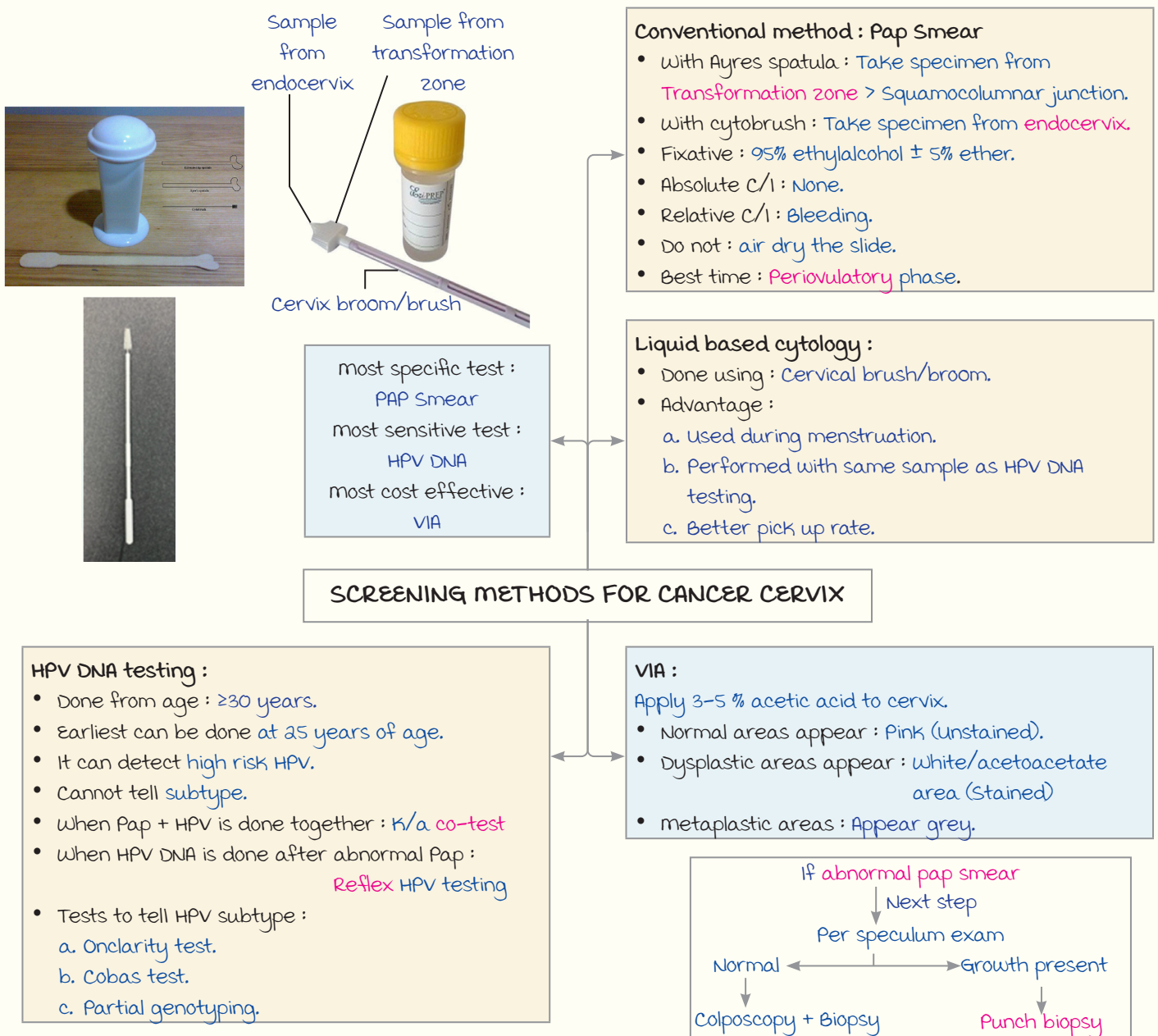
----- Active space -----

- 90% girls to be vaccinated by age 15.
- 70% females ≥30 years of age to be screened for Ca. Cervix.
- 90% of those with positive test to be treated.

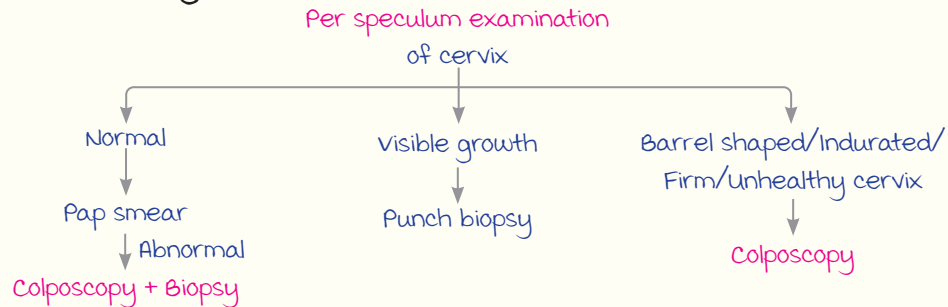
WHO recommended Rx : LLETZ/LEEP.

Screening Methods for Cancer Cervix

00:32:30



----- Active space -----

MANAGEMENT**Post-Coital Bleeding Protocol :****Pap Smear Reporting :**

Pap smear report	Next step
LSIL ≥25 years	Colposcopy + Biopsy
ASC-H	Colposcopy + Biopsy + Endocervical curettage (ECC) Can visualize endocervix for adenocarcinoma.
HSIL	
ASCUS <25 years	Repeat pap smear in 1-2 yrs.
ASCUS ≥25 years	Colposcopy/HPV DNA testing $\xrightarrow{\text{If positive}}$ Colposcopy (Reflex HPV testing)
AGCUS	Colposcopy + Biopsy + ECC + Endometrial biopsy

Note :

- ASC-H : Atypical squamous cells - HSIL cannot be ruled out.
- ASCUS : Atypical squamous cells of undetermined significance.
- AGCUS : Atypical glandular cells of undetermined significance $\xrightarrow{\text{Possibilities}}$
 - Adenocarcinoma of cervix.
 - Endometrial cancer spread to cervix.

Colposcopy :

- magnification power : 30 times.
- visualizes exocervix & TZ (Cannot visualize endocervix).

Procedures :

Apply 3-5% acetic acid → Biopsy areas that look white.

Switch on green filter → Biopsy from abnormal blood vessels (Reticular/mosaic/punctate areas).

HSIL with colposcopy report of CIN I/Normal :

Cone biopsy/Conization :

- Done in OT under GA.
- Indication : Suspicion of adenoCa.

ECC Positive :

mx : Cone Biopsy → Adeno Ca in situ (+) → Hysterectomy.

Cancer Cervix

00:48:40

----- Active space -----

Important Points :

- most common type of Cancer Cervix : Squamous cell Ca.
- 2nd most common type of cancer cervix : Adeno Ca.
- most common site for cancer cervix : T2.
- most common site for adenocarcinoma of cervix : Endocervix.
- most common symptom : AUB.
- most specific Symptom : Post coital bleeding.
- most common cause of death : Renal failure.
- most common age for cancer cervix : 35-39 yrs
- most common route of spread : 60-65 yrs
Direct > Lymphatic > Hematogenous.

Lymphatic drainage of cervix :

- H : Hypogastric/Internal iliac LN
- O : Obturator LN
- P : Paracervical LN
- E : External iliac
- Sentinel LN of cancer cervix : Paracervical.
- Cervix does not drain into : Superficial inguinal LN.
- The most important prognostic factor in cancer cervix : Stage > LN involvement.
- most important cancer in females : Breast Ca.

CANCER CERVIX

management Principles :

Surgery :

- Can be done till stage : II A (Tumor size <4 cm)
- Except : If tumor size ≥ 4cms (I B3 & II A 2)

Chemoradiation : Can be done in all stages

Treatment of choice for stages :

- II B to IV
- I B3 & II A2

Radiosensitizer used in cancer cervix :

Cisplatin > 5 Fluorouracil.

Note : Radical trachelectomy

- Removal of cervix + 80% parametrium.
- uterus stitched to vagina.
- C/I : Tumor size ≥ 2 cms .
- Subsequent labor only through LSCS.

Surgery

Young

Stage	Surgery	LN dissection
I A1	Conization	⊖
I A2	Radical Trachelectomy Type 3 Hysterectomy	Pelvic + Paraaortic LND
I B1		
I B2		
II A1		

Older

I A1	Type 1 hysterectomy (TAH + BSO)	⊖
I A2	Type 2 hysterectomy (Wertheim)	Pelvic + Paraaortic LND
I B1	Type 3/Radical hysterectomy	
I B2		
II A1		

----- Active space ----- FIGO Staging:

Stage	Description
Stage I	Ca limited to cervix
IA	microscopic Ca (≤ 5 mm deep)
IA1	≤ 3 mm deep
IA2	4-5 mm deep
IB	macroscopic Ca (> 5 mm deep)
IB1	Tumor Size ≤ 2 cms
IB2	Tumor Size ≤ 4 cms
IB3	Tumor Size > 4 cms
Stage II	Cancer spread to upper vagina
IIA	Parametrium not involved
IIA1	Tumor Size ≤ 4 cms
IIA2	Tumor Size > 4 cms
IIB	Parametrium involved
Stage III	Cancer spread to lower vagina
III A	No involvement of pelvic side wall
III B	Involvement of pelvic side wall/ hydroureter/hydronephrosis
III C	LN Involvement
III C1	Pelvic LN involvement
III C2	Paraaortic LN involvement
Stage IV	metastatic
IV A	Regional : Bladder/rectum
IV B	Distant : Superficial inguinal LN involvement

Note :

- IOC → myometrial involvement } MRI
- IOC → Parametrium involvement } MRI
- IOC → LN involvement : PET CT.
- metastasis to ovaries is rare.

GYNAECOLOGY : PART 4

----- Active space -----

Introduction to Ovarian Carcinoma

00:00:27

Types of Ovarian Cancer (WHO Classification) :

Epithelial ovarian tumor	Germ cell tumor	Sex cord stromal tumor	metastatic tumor
<ul style="list-style-type: none"> m/c : 90% m/c : Serous tumor Mucinous tumor Brenner tumor Endometrioid tumor Clear cell Ca 	1a. m/c teratoma : Benign/ mature cystic 1b. Teratoma/dermoid cyst 2. Malignant/immature 3. Teratoma 4. Dysgerminoma 5. Yolk sac tumor 6. Embryonal cancer 7. Choriocarcinoma	<ul style="list-style-type: none"> Estrogen secreting : Granulosa cell tumor Androgen secreting/ Arrhenoblastoma/Adenoblastoma <ul style="list-style-type: none"> - Sertoli cell - Leydig cell - Hilus cell tumor Stromal tumor : <ul style="list-style-type: none"> - Fibroma - Thecoma - Fibrothecoma 	<ul style="list-style-type: none"> Krukenberg tumor

Screening of Ovarian Cancer :

- Not done universally.
- Indication : H/o familial ovarian Ca (10%).
 - Family history (1st degree relative).
 - Occurs a decade earlier (5th decade)

BRCA gene 1/2 testing

If +ve

Perform **TAH + BSO** once family is complete/patient >40 years of age

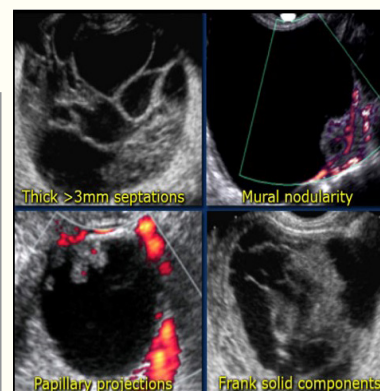
Screening with TVS + CA 125 **annually**.

Protocol for Adnexal mass on P/V :

TVS (Next step)

Features suggestive of malignancy :

- Solid component.
- B/L.
- Papillary excrescences.
- Thick septa.
- Increased vascularity in septa.
- Ascites/LN involvement/matted bowel loop.



TVS

----- Active space -----

Protocol for USG ⊕ Ovarian Cyst with no Features of malignancy :

Post-menopausal female :

- Check CA-125.
- If ≥ 35 IU : Further evaluation & surgery.

Reproductive age :

- Check size of cyst.
- If ≥ 7 cms : Surgery (D/t high risk of torsion).

Types of Ovarian Tumors

00:04:34

Epithelial Ovarian Tumors :

- m/c ovarian tumors.
- m/c type : Serous cystadenoma Ca.
- Seen in ≥ 60 years.
- mostly w/L.
- mutations :
 - Low grade tumors : KRAS/PTEN.
 - High grade tumors : p53.
- Ovarian Ca a/w pseudomyxoma peritonei : mucinous tumor.

Pseudomyxoma peritonei

Causes :

- Appendix Ca (m/c).
- mucinous ovarian tumor.
- mucocele of appendix.

↑↑ Recurrence rate : Bad prognosis

Prognosis :

- Not good.
- Non-specific signs & symptoms initially.
- Present in advanced stage directly.

Syndromes a/w Ascites & Right Side Pleural Effusion :

meig's syndrome :

- Any 1 of the following (mnemonic : Government Banned Tobacco Forever).
 - Granulosa cell tumor.
 - Brenner tumor (Solid benign tumor).
 - Thecoma.
 - Fibroma.

Pseudo meig syndrome :

When a/w any other condition (Eg : Fibroids, mucinous ovarian tumors).

m/c ovarian tumor a/w :

- Endometriosis : Clear cell Ca > endometrioid tumor.
- Endometrial Ca : Endometrioid tumor > Granulosa cell tumor.

🏷️ Ovarian Tumor & Tumor markers :

----- Active space -----

Tumor	Tm marker
Epithelial tumor	CA 125
Mucinous tumor	CA 19-9
Dysgerminoma (Dysgenetic gonads)	<ul style="list-style-type: none"> • main : LDH • Others : hCG • Never produce Alpha-fetoprotein (AFP)
Yolk sac tumor (Endodermal sinus tumor)	<ul style="list-style-type: none"> • main : AFP • Others : LDH • Never produce hCG
Embryonal cancer	AFP + hCG
Choriocarcinoma	hCG
Granulosa cell tumor	Inhibin-B & Anti-mullerian hormone

Brenner's Tumor :

Features : Epithelial cell, solid, **u/L**, benign tumor.

HPE : **Walthard cell nest + coffee bean nucleus.**

Epithelium : Transitional epithelium.

Germ Cell Tumor (GCT) :

m/c age group : 10-30 years.

Laterality : mostly **u/L**.

- Always **u/L** : **Yolk sac tumor.**
- 2-10% dermoid cyst are **B/L**.
- 15-20% dysgerminoma are **B/L**.

m/c : Dermoid cyst/mature teratoma.

m/c malignant GCT : Immature teratoma.

Prognosis : Good d/t detection at early age.

- Best : **Dysgerminoma.**
- Worst : Yolk sac tumor.

Rapid progression : Yolk sac tumor (Presents with acute abdomen).

Only radiosensitive ovarian tumor : **Dysgerminoma.**

Note :

- most radiosensitive organ : Ovaries.
- Ovarian Ca are radioresistant.

----- Active space -----

Dermoid Cyst :

Features :

- m/c ovarian tumor in reproductive age & pregnancy.
- Laterality : u/L mostly, B/L in 10%.
- mostly benign.

Components :

- All 3 germ layers.
- m/c : **Ectodermal.**

malignancy :

- Risk : 0.2-2%
- m/c site : **Rokitansky protuberance.**
- m/c type : **Squamous cell Ca.**

USG :

- Tip of iceberg appearance.
- Dot & dash appearance.
- Rokitansky protuberance.

mx :

- Cystectomy d/t **maximum risk of torsion.**
- Oophorectomy if family is complete.

Dysgerminoma :

Features : Solid, fleshy, lobulated, tan in color

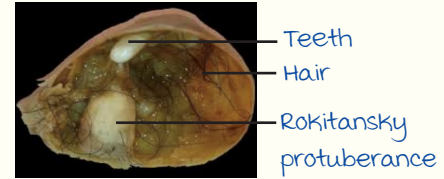
- usually u/L.
- GCT with **highest risk of bilaterality** : 15-20% cases.

Characteristics on HPE :

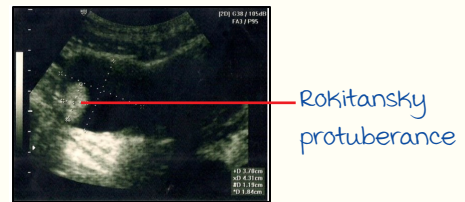
- Nest of cells separated by fibrous septa.
- Septa is infiltrated by lymphocytes.

Yolk Sac Tumor/Endodermal Sinus Tumor :

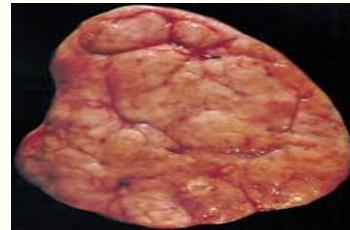
- most malignant GCT.
- most rapidly progressing tumor.
- Can present as acute abdomen.
- **100% u/L.**
- GCT with **worst prognosis.**

HPE : **Schiller duval bodies** (Similar to glomeruloid bodies).

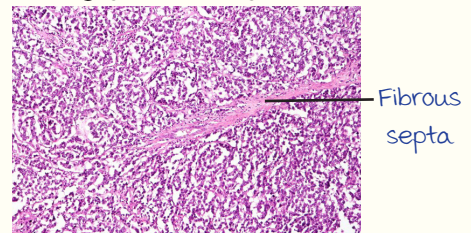
Dermoid cyst/mature teratoma



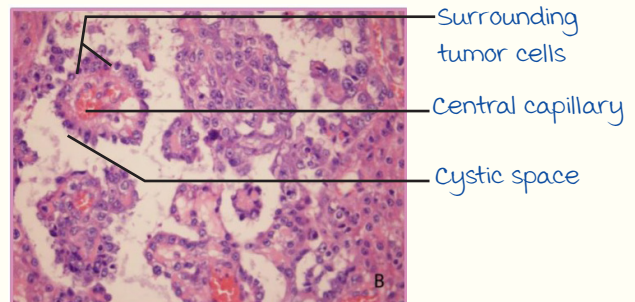
USG : Dermoid cyst



Dysgerminoma gross



Dysgerminoma HPE

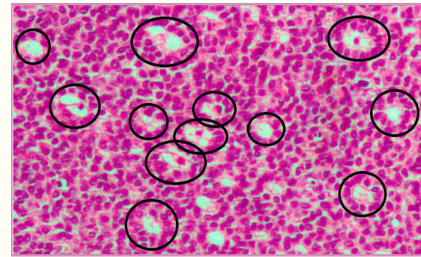


Yolk sac tumor

Sex Cord Stromal Tumors :

Granulosa cell tumor :

- Presents at any age.
- Gene defect : **Fox L2 gene**.
- Estrogen producing tumor :
 ↑ Risk of **endometrial Ca** → Endometrial biopsy.
- Presentation
 - Puberty : Puberty menorrhagia.
 - Reproductive/perimenopausal age : AUB.
 - menopausal : Post menopausal bleeding.



HPE of granulosa cell tumor :
Call-Exner bodies

----- Active space -----

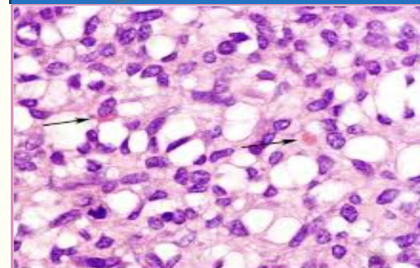
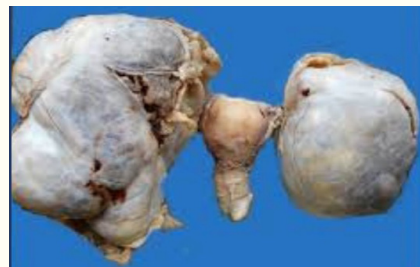Krukenberg Tumor :

- **metastatic tumor** of ovary.
- m/c primary Ca : Stomach Ca (Pyloric end).
- Route of spread : **Retrograde lymphatics**.
- B/L in **80%** cases.

Characteristics of tumor :

- Leads to symmetrical ovarian enlargement with its shape retained.
- Waxy, mobile.
- Intact capsule.

On HPE : **Signet ring cells** (Filled with mucin & nuclei pushed to periphery).



HPE of Krukenburg tumor :
Signet ring cells

Management of Ovarian Cancer

00:19:58

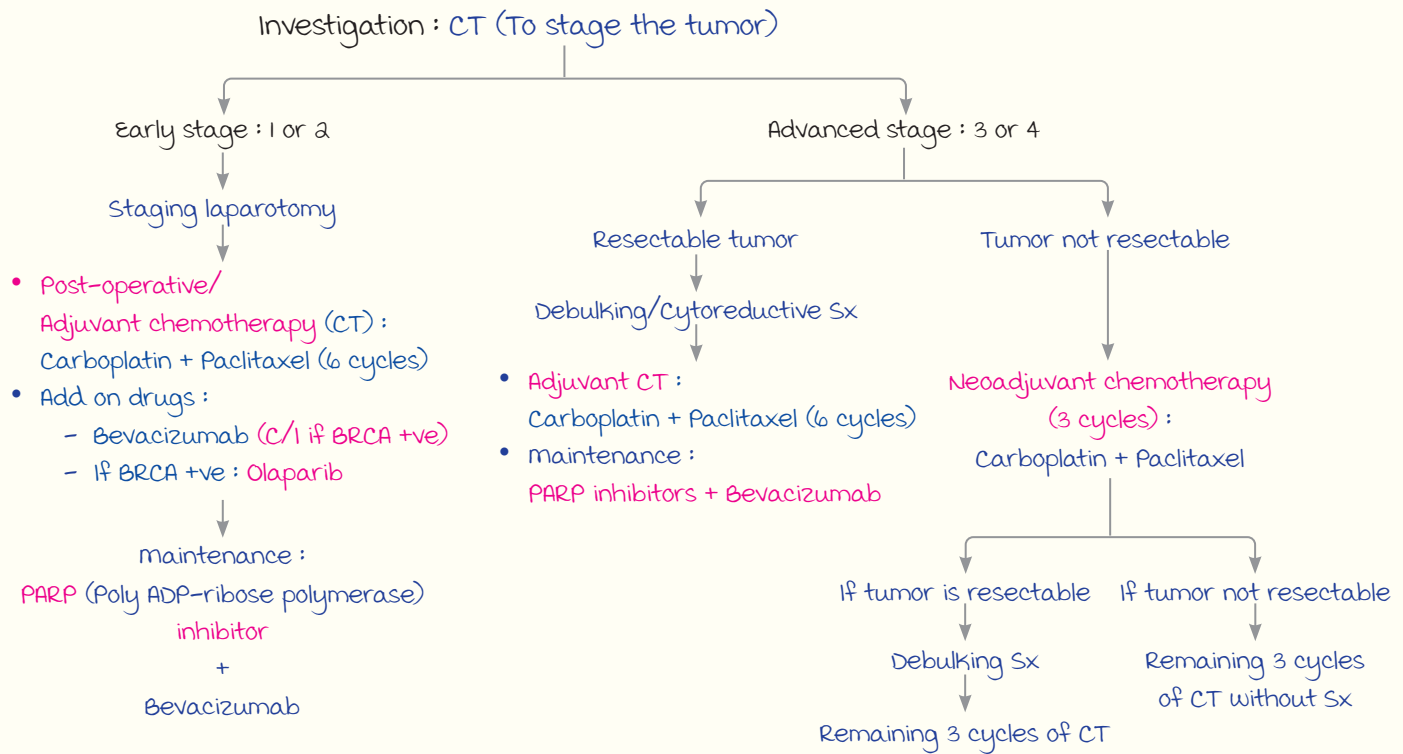
Staging Laparotomy/Surgical Staging :

Done in all cases

Steps :

1. Ascitic fluid/peritoneal wash sample.
2. TAH + BSO.
3. multiple peritoneal biopsies.
4. **Infracolic omentectomy** (Not omental biopsy).
5. Pelvic + Paraaortic LND.

----- Active space ----- **97?** mx of Epithelial Ovarian Ca :



Note :

Features of **Non-resectable tumors** :

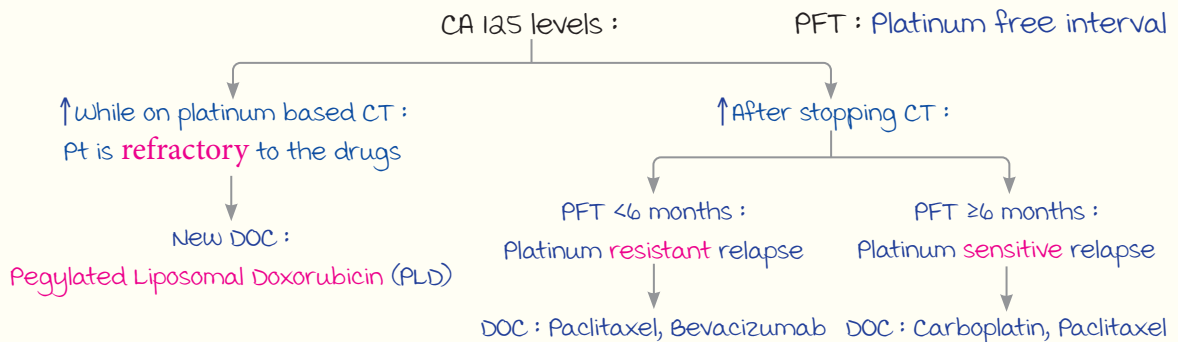
- Peritoneal caking.
- Involves vital organs : Stomach, liver, great vessels, intestine, mesentery.

management of Germ Cell Tumors :

u/L salpingo-oophorectomy (Young female) → Chemotherapy (All stages)
Exception : **Dysgerminoma stage I.**

CT Drugs : Bleomycin, Etoposide, Cisplatin.

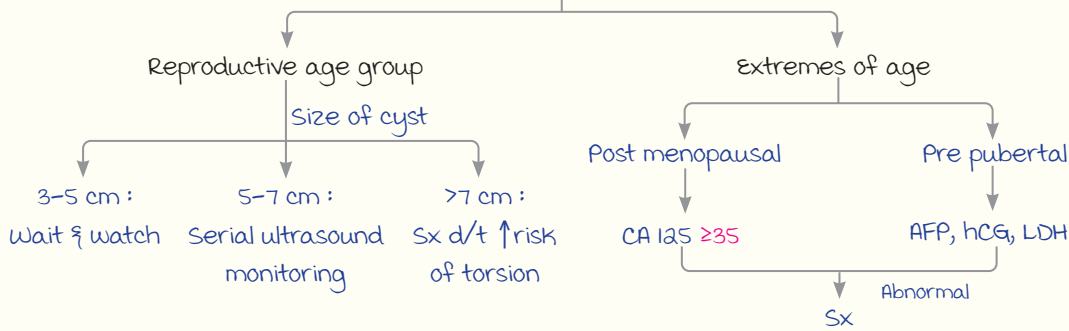
97? Surveillance During Rx :



Note : Partial platinum resistance does not exist.

Ovarian Cysts Without Features of malignancy on Ultrasound :

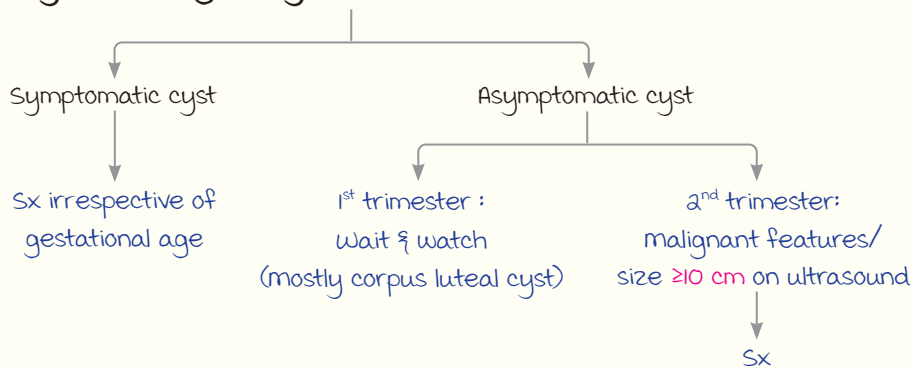
----- Active space -----



Note :

- malignant transformation of ovarian masses — 30% in post menopausal.
7% in pre menopausal.
- In reproductive age group : CA 125 — ↑ In benign conditions (Fibroid, PID, cervical TB).
≥ 200 IU : Significant.

Ovarian Cysts in Pregnancy :



- m/c benign tumor in pregnancy.
 - m/c to undergo torsion in pregnancy.
 - m/c at end of 1st trimester/during puerperium.
 - m/c ovarian Ca in pregnancy : Dysgerminoma.
- } Dermoid cyst.

Female External Genitalia/Pudendum/Vulva

00:35:24

Lymphatic drainage :

Superficial inguinal LN → Deep inguinal/femoral LN.

Vulval Ca :

Lymph node dissection (LND) : Inguinofemoral LN (Pelvic LN not dissected).

Sentinel LN : Superficial inguinal LN.

exception → Glans of clitoris : Direct drainage into deep inguinal/Cloquet/Rosenmuller's LN.

B/L inguinofemoral LND :

Structures located within 2 cms of midline drain B/L.

Important One Liners :

- most common type : Squamous cell Ca
- 2nd most common type :
melanoma > Adeno Ca
- Age group :
50-70 years (mean : 65 years)
- most common symptom : Pruritis.
- most common site :
Labia majora > Labia minora.
- It had 2 common varieties :
a. Keratinizing (m/c).
b. Warty.

Risk Factors :

H : HPV (HPV 16).

P : → Paget's disease.
→ p53 mutation.

V :

- Vulval intraepithelial neoplasia (VIN).
- Vulval dystrophy/atrophy.
- Vulval warts (Condyloma acuminata).

S : Smoking.

Also Know :

- Important points on staging :
 - Stage IA : Size <2 cm & depth <1 mm.
 - Stage IB : size ≥2cm & depth ≥ 1mm
 - LN involved in : Stage III & IV.

VULVAL CANCER**Management :**

- Stage 1, 2 :
 - Sx : mx of Ca + LND.
- Stage 3, 4 :
 - Chemoradiation.

Surgery :

- Tumor excision : Simple partial vulvectomy in stage IA.
- IB/II : Radical vulvectomy.

Lymphatic Dissection :

- In stage IA : No LND.
- If LN are palpable : B/L inguinofemoral LND.
- If LN are positive : B/L inguinofemoral LND.
- If LN are not palpable :
 - Stage IA : No LND.
 - In all other stages : Inguinofemoral LND.
 - Always : Do B/L inguinofemoral LN dissection.
 - Except if all following conditions are fulfilled :
 - Size : <2 cms
+
 - Tumor should be : >2 cms away from midline
+
 - Local extension : Absent.

Note :

- Condyloma lata.
 - Herpes simplex virus.
 - Gravida/parity.
 - Vulval hamartoma.
- } Not risk factors for vulval cancer.

Associations of Estrogen Dependent Conditions

00:47:29

----- Active space -----

Estrogen dependent conditions :

- Fibroid.
- Endometriosis.
- Endometrial Ca.
- Ovarian Ca.

Risk factor	Protective factors
Nulliparity	multiparity
Obesity	Pregnancy
Early menarche	Physical exercise
Late menopause	Smoking (D/t inhibition of aromatase)

Theory of incessant ovulation : \uparrow Ovulation \rightarrow \uparrow Risk of ovarian Ca.

- | | | | |
|--|------------|---|----------------------|
| <ul style="list-style-type: none"> • PCOS • Ovulation inducing drugs | } +/- risk | <ul style="list-style-type: none"> • OCP • Breast feeding | } Protective factors |
|--|------------|---|----------------------|

Note :

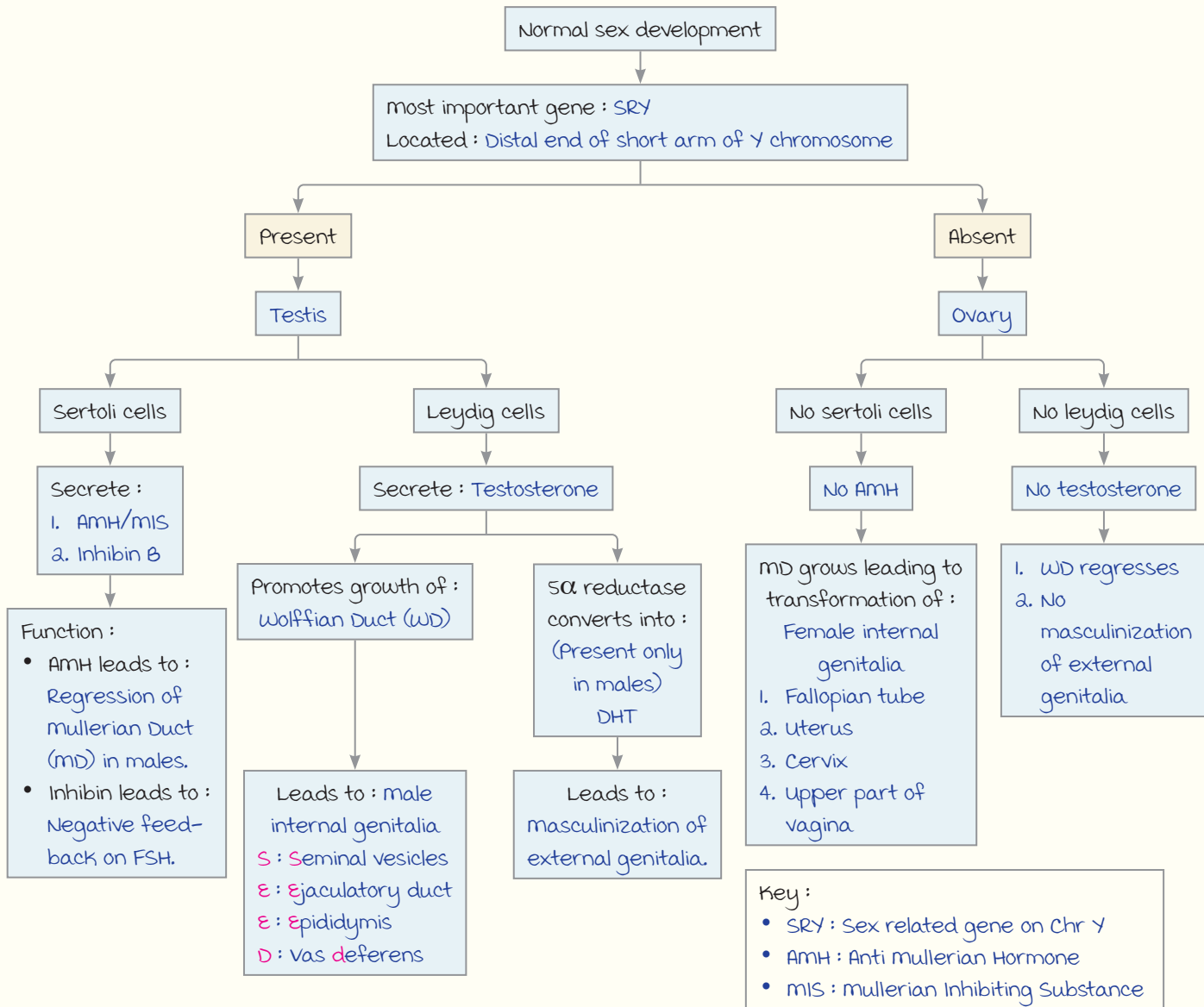
- virilizing tumor of ovary : Arrhenoblastoma.
- m/c post menopausal bleeding : Polyp.
- Presentation : Post-menopausal bleeding with h/o DM & hypertension (HTN)
 - TVS \geq 4 mm \rightarrow Endometrial sampling.
 - Corpus cancer syndrome :
 - \uparrow risk of endometrial Ca in obese female + DM + HTN.

GYNAECOLOGY : PART 5

----- Active space -----

Sexual Development

00:01:20



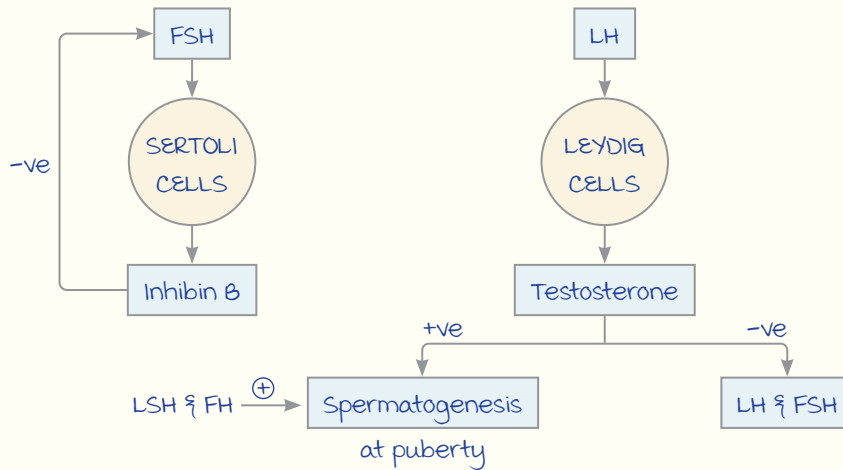
Note :

- Gene for testes formation : **SRY gene** > SOX gene.
- mineral needed for SRY gene function : **Zinc**.

IMPORTANT ONE LINERS

----- Active space -----

1. 1st stimulus for testes to secrete testosterone : hCG
2. In males :



3. Remnants of :

mullerian duct in males	Wolffian duct in females
1. Appendix of testes (Hydatid of morgagni) 2. Prostatic utricle	1. Epoophoron (Proximal end of mesonephric tubule) 2. Paraoophoron (Distal end of mesonephric tubule) 3. Gartner's duct (mesonephric duct) : Present in anterolateral wall of vagina. <div style="text-align: right; margin-top: -10px;">} Present in broad ligament</div>

4. Gonads develop from : Genital ridge (5 weeks of intrauterine life, testes before ovary).
5. upper part of vagina develops from : mullerian duct.
 Lower part of vagina develops from : Sinovaginal bulb of urogenital sinus.

Development of External Genitalia

00:10:23

Develop from the same anlage in both males & females.

Homologous Organs :

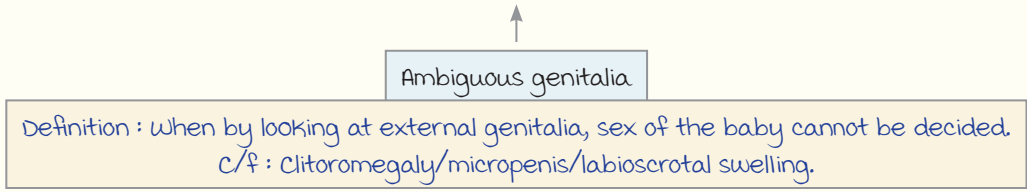
Same embryological origin.

	Testosterone ⊕/XY	Testosterone ⊖/XX
Genital tubercle	Penis	Clitoris
Labioscrotal swelling	Scrotum	Labia majora
Genital fold/urethral fold	Penile urethra	Labia minora

----- Active space ----- **AMBIGUOUS GENITALIA**

If Testosterone or DHT is present in sufficient quantity in intrauterine life : male external genitalia.
 If Testosterone or DHT is present but in insufficient quantity : Ambiguous genitalia.
 If Testosterone or DHT is absent in intrauterine life : Female external genitalia.

	XY karyotype	XX karyotype
Testosterone in sufficient quantity	male external genitalia	⊖
Testosterone present but less	Ambiguous	Ambiguous
Testosterone absent	Female external genitalia	Female external genitalia



```

    graph TD
      A[Child born with ambiguous genitalia] --> B[Next step]
      B --> C[Physical examination]
      C --> D[If gonads are palpable]
      C --> E[If gonads are NOT palpable]
      D --> F["Undescended testes : 46 XY  
• m/c cause : Partial Androgen Insensitivity Syndrome (AIS)"]
      E --> G["46 XX  
• m/c cause : Congenital Adrenal Hyperplasia (CAH)"]
    
```

PYQS Ⓢ

Barr body

- Calculation : No. of X chromosomes - 1
- $\textcircled{N} \rightarrow F = 1, m = 0.$

1. False positive Barr body seen in : Klinefelter's syndrome.
2. False negative Barr body seen in : Turner's syndrome.
3. male pseudohermaphrodite :
 - Genotype : 46 XY.
 - Ext. genitalia : Female.
 - Eg :
 - Complete AIS (m/c).
 - Swyer's syndrome.
 - 5 α reductase deficiency.
4. Female pseudohermaphrodite :
 - Genotype : 46 XX.
 - Ext. genitalia : Ambiguous.
 - Eg : CAH.

IOC in ambiguous genitalia : karyotyping.

Note :

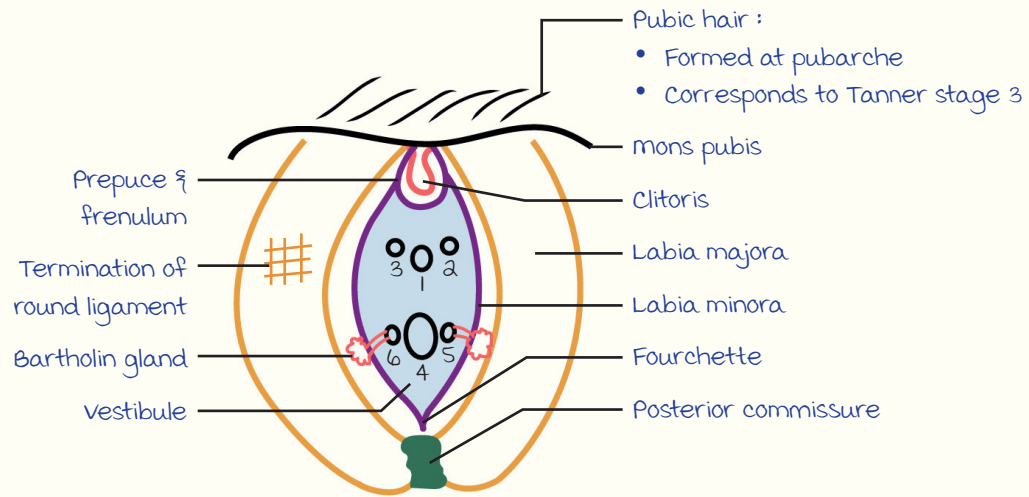
- m/c cause of female looking external genitalia in XY karyotype : Complete AIS.
- Best method for sex determination in a child :
 - Karyotyping $\rightarrow Y \oplus$: male (Eg : Klinefelter's 47 xxY)
 - $\rightarrow Y \ominus$: Female (Eg : Turner's 45 xO)

Anatomy of Female External Genitalia

00:26:15

----- Active space -----

Vulva/Pudendum :

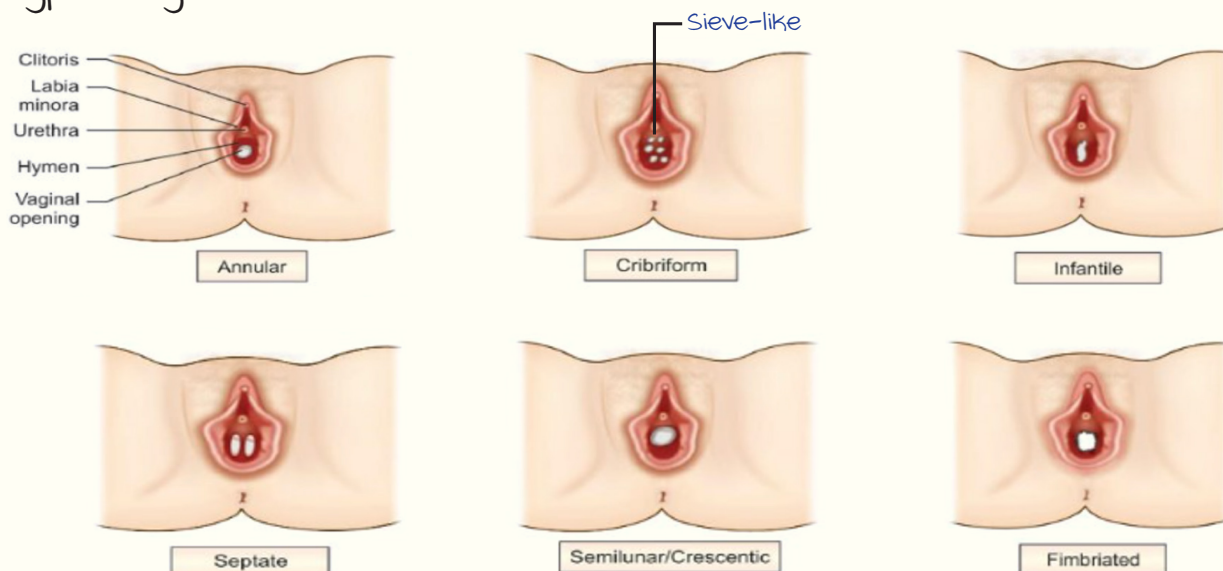


VESTIBULE
Area bounded :
Anteriorly : Clitoris
Posteriorly : Fourchette
Laterally : Labia minora
Area bounded :
1 : urethral opening
2, 3 : Paraurethral (Skene) gland opening
4 : Introitus (Vaginal opening) → Covered by hymen
5, 6 : Openings of ducts of Bartholin glands

PYQs (97) :

- Hair appears on mons pubis in : Tanner stage 3.
- Pubic hair is d/t : Androgen.
- Clitoromegaly is : Length of clitoris ≥ 4 cm.
- Prostate glands : Homologous to Skene gland in females.
- Cowper's gland : Homologous to Bartholin gland in females.

Types of Hymen :

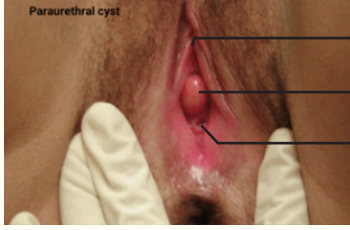

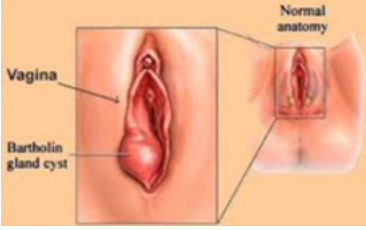


----- Active space -----

Imperforate hymen :

- No opening in hymen.
- Complication : Cryptomenorrhea.

vulval Cysts :

Cyst	Location
Paraurethral/Skene gland cyst	<p>Adjacent to urethra</p>  <p>Labels: urethra, Paraurethral cyst, Introitus</p>
Gartner's cyst	<p>Antero-lateral wall of vagina</p>  <p>Label: Gartner's cyst</p>
<p>Bartholin cyst :</p> <ul style="list-style-type: none"> • Small & asymptomatic • Symptomatic : vulval pain during physical activity • O/E : unilateral, round/oval, fluctuant • management : <ul style="list-style-type: none"> - <3 cm : Conservative management. - Asymptomatic, ≥3 cm } I & D f/b - Symptomatic } insertion of - Bartholin abscess } Word catheter - Recurrent cyst : marsupialization. 	<ul style="list-style-type: none"> • B/w labia majora & minora (Gland) or • In vestibule, outside introitus (Duct opening)  <p>Labels: Vagina, Bartholin gland cyst, Normal anatomy</p>

Bartholin Gland :

- AKA Greater vestibular gland.
- Location : B/w labia majora & minora (At 5 o' clock/7 o' clock position).
- Normally not palpable.

Genital Ulcers

00:38:45

----- Active space -----

	Genital herpes	Syphilitic chancre	Soft chancre	Donovanosis	LGv
Incubation period	2-7 days	10-90 days	1-14 days	1-12 weeks	3 days - 6 weeks
Causative agent	HSV 2 > HSV 1	Treponema pallidum	Haemophilus ducreyi	Klebsiella granulomatis	Chlamydia trachomatis
Clinical presentation	Vesicles on erythematous base in clusters	Single painless ulcer with : • Clear base • Firm, raised border	Painful ulcer with undermined edges	Painless papule/nodule ↓ Beefy red granulomatous ulcers with rolled edges	Painless ulcers
Lymphadenopathy	Painful & pruritic	Painless	Painful	Pseudobuboes	Painful
Diagnosis	• Tzanck smear : multinucleated giant cells • PCR	• Serology • Dark field microscopy	Culture	Biopsy : Donovan bodies	NAAT
Rx	Acyclovir/ Famciclovir	Penicillin/ Ceftriaxone	Azithromycin/ Ceftriaxone	Azithromycin	Doxycycline

LGv : Lymphogranuloma venereum.

Puberty :

Ⓝ Age → ♀ = 10.5 years
 → ♂ = 11.5 years

1st sign of puberty in females :

Growth spurt.

(most specific : Thelarche)

1st sign of puberty in males :

Testicular enlargement.

Sequence of puberty in females :

Growth spurt > Thelarche > Pubarche

> Peak height velocity > menarche.

Estrogen has the following actions during puberty :

1. Breast development.
2. Development of reproductive tract :
Uterus development.
3. Starting of menstruation.
4. Pubertal growth spurt.
5. Vaginal cornification.
6. Cervical mucus production.
7. Epiphyseal closure.
8. Bone mass.
9. Increased clotting factors : OCP C/I in
 - H/o thrombosis/CAD/CVA.
 - Puerperium < 21 days.

PUBERTY**Delayed Puberty :**

- Females : 13 yrs.
- males (m/c) : 14 yrs.
- m/c cause : Constitutional delay.
- DOC : **Pulsatile GnRH.**

Hormones Responsible :

- main hormone responsible for breast development : **Estrogen**
- main hormone responsible for pubic hair & axillary hair development : **Androgen**

Central Precocious Puberty:

- D/t : Premature activation of HPO axis.
- LH : ↑
- FSH : ↑
- ε : ↑
- m/c cause : Idiopathic. (80%)
- 2nd m/c cause : Brain hamartoma. (10%)
- It is always : Isosexual. (2^o sexual characteristics : Breast development ⊕)
- DOC : **Continuous GnRH.**
- A/w : Precocious menstruation. (menarche ≤ 10 years)

Peripheral Precocious Puberty :

- D/t : Exogenous source of estrogen/androgen.
- Can be : Isosexual/heterosexual.
- LH : ↓
- FSH : ↓
- Estrogen/androgen : ↑
- Isosexual (Cause) :
 1. Estrogen secreting ovarian tumor.
 2. Hypothyroidism.
 3. McCune Albright syndrome.
- Heterosexual (Cause) :
 1. Androgen secreting tumor.
 2. CAH.
- Not a/w : Precocious menstruation.

Precocious puberty :

- Females (m/c) : Thelarche < 8 yrs of age.
 males : Testicular enlargement ≤ 9 yrs of age.
- m/c cause : Central precocious puberty
- m/c in : Females > males.

Note :

1. McCune Albright syndrome (☺):
 - a. Precocious puberty.
 - b. Polyostotic fibrous dysplasia.
 - c. Cafe au lait spots.
2. Significant neurotransmitters :
 - GABA : maintain dormancy of hypothalamus before puberty.
 - Kisspeptin : Pulsatile release of GnRH at puberty.
 - Leptin : Permissive role in puberty.

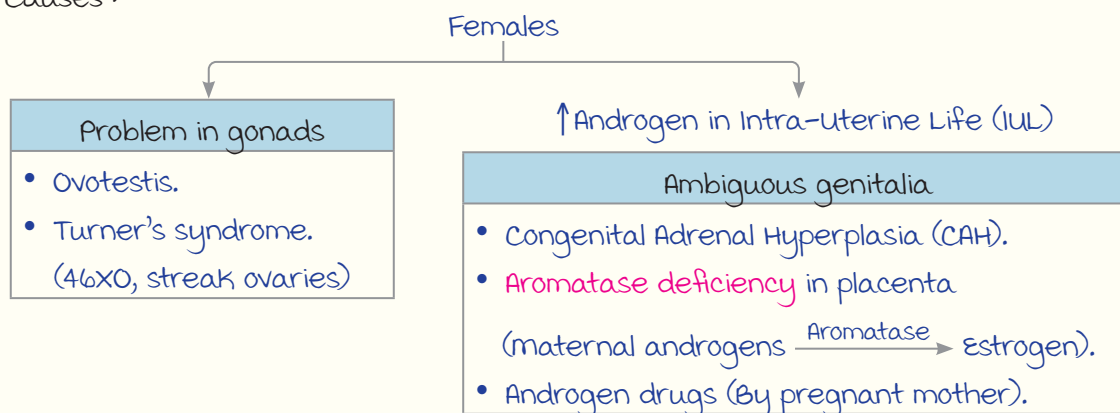
GYNAECOLOGY : PART 6

----- Active space -----

Disorders of Sexual Development (DSD) in 46 XX

00:00:07

Causes :



OVOTESTIS

- Earlier called as true hermaphrodite.
- Individual with male + female gonads.

Phenotype :

- m/c : Testis on one side + ovary on other side.
- B/L testicular & ovarian tissue.

Karyotype : 46 XX (m/c) > 46 XY.

Genital Organs Development :

Internal genitalia :

- Side of ovary : Mullerian Duct (MD) → Female internal genitalia.
- Side of testis : Wolffian Duct (WD) → male internal genitalia.

External genitalia :

- Ambiguous genitalia (more resemblance to male external genitalia).
- Taken as : male child at birth.

Presentation :

3/4th : Ovary on one side → Estrogen → Breast development (Gynaecomastia).

1/4th : menstruation.

----- Active space -----

Congenital Adrenal Hyperplasia

00:06:18

most common cause of :

- Ambiguous genitalia in ♀.
- ♀ pseudohermaphrodite.

m/c enzyme deficiency :

1st α hydroxylase.2nd most common enzyme deficiency :11 β hydroxylase.Presentation with 21 α hydroxylase deficiency or 11 β hydroxylase :

Hormones decreased :

a. Aldosterone :

- Hyponatremia.
- Hyperkalemia.
- Salt water wasting.
- metabolic acidosis.
- Hypotension.

b. Cortisol : Hypoglycemia.

Hormone increased :

↑ACTH → Adrenal gland → ↑Androgen.
stimulation

a. Androgen leads to :

♀ : Ambiguous genitalia.

♂ : Normal ♂ genitalia.

CONGENITAL ADRENAL HYPERPLASIA

Screening test

17-OH progesterone levels

<200 ng 200 to 800 ng ≥ 800 ng

Rules out
CAH

Diagnostic test

ACTH
stimulation testConfirms
CAH

Enzyme deficiency which leads to ambiguous genitalia in male (XY) karyotype :

1. 17 α hydroxylase.
2. 17,20-lyase.

Enzyme deficiency which leads to ambiguous genitalia in both XX and XY karyotype :

- 3 β -HSD deficiency.
- P450 Oxido-Reductase (OR) deficiency

A/w skeletal anomalies :

Antley Bixler syndrome.

mx : Begin mx even without waiting for karyotype genetic test.

1. DOC :

Corticosteroids → ⊖ feedback on ACTH

↓ Androgen ← Adrenal gland not stimulated

2. Correct fluid electrolyte imbalance.

3. Later on correct clitoromegaly surgically.

Note :

If child with XX karyotype born with ambiguous genitalia + mother had

hirsutism in pregnancy :

Enzyme deficiency → Aromatase deficiency in placenta.

Investigations : Precocious Puberty and DSD

00:12:32

----- Active space -----

To be done in all cases of precocious puberty :

1. Bone age estimation.
2. LH, FSH, Estrogen levels : **Central** (m/c) vs peripheral type.
3. **MRI** : Rule out brain tumors (Hamartoma).
4. **Pelvic USG** : Rule out estrogen secreting ovarian tumor (Peripheral cause)
5. **TSH** : Rule out hypothyroidism (Peripheral cause).

To be done when a child born with ambiguous genitalia :

1st step : Physical examination.

IOC : **Karyotyping**.

Others : Gonads palpable

46XY

↓ confirmed

Check :

- Testosterone.
- DHT (Dihydrotestosterone).
- LH/FSH.
- Pelvic USG.
- AMH (Anti-mullerian hormone).

INVESTIGATION

To be done in all cases of heterosexual precocious puberty :

Test for precocious puberty

+

1. Testosterone : Rule out androgen secreting tumors.
2. **DHEA sulphate** : Rule out **adrenal** tumors secreting androgen.
3. 17-OH progesterone : CAH.

Also know :

Androgen **Ⓜ** is seen on : **Long arm of X chr.**

Ⓝ levels of androgen in females : **<70 ng.**

To be done in all cases of congenital adrenal hyperplasia (46 XX individual) :

- 17-OH Progesterone.
- Testosterone.
- Serum electrolytes.
- IOC : **Karyotyping**.

If a female gives h/o CAH in previous pregnancy :

DOC in this pregnancy : **Dexamethasone**
(Crosses placenta).

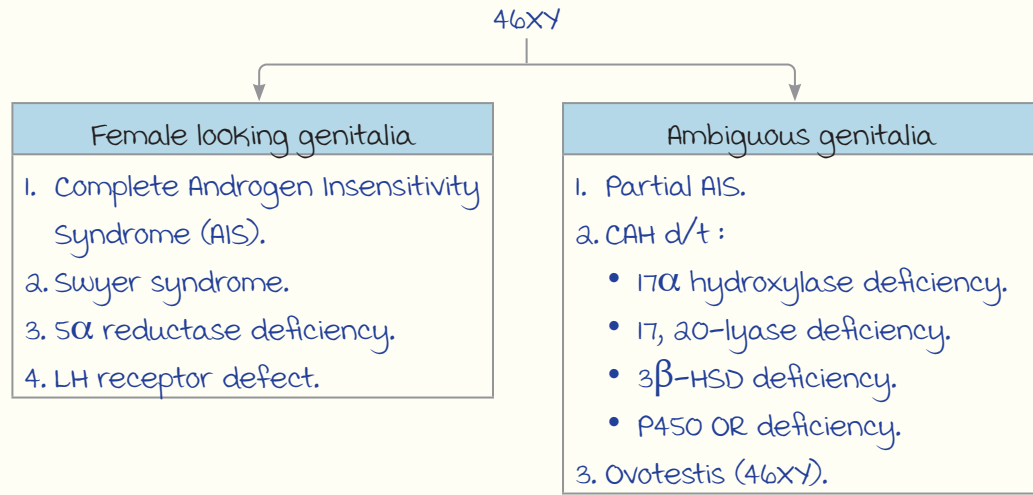
Ⓜ : Receptors

Disorders of Sexual Development in 46XY

00:16:52

----- Active space -----

Causes :



ANDROGEN INSENSITIVITY SYNDROME VS. SWYER SYNDROME

	Complete AIS	Swyer Syndrome
Karyotype	46XY	46XY
Gonad	Testes : Normal	Testes : Dysgenetic
Etiopathogenesis	Completely insensitive to testosterone	Point mutation in SRY gene
Sertoli cells	(N) → AMH → MD regresses ↓ Inhibin	Dysgenetic cells → AMH ⊖ → MD grows
Leydig cells	(N) → Testosterone	Dysgenetic cells → Testosterone ⊖ → WD regress.
Internal genital organs	Absent (Testosterone resistance → WD regression); may have blind ending vagina.	♀ (D/t MD growth)
uterus	⊖	⊕
External genital organs	♀ (D/t DHT resistance)	♀
At puberty	Testosterone $\xrightarrow{\text{Aromatase}}$ Estrogen	Dysgenetic testes → Testosterone absent
Breast	Fully developed (D/t estrogen) : Tanner stage 4 or 5	⊖
Pubic hair	Scanty (Androgen resistance) : Tanner stage 1 or 2	Scanty/⊖
Presentation	<ul style="list-style-type: none"> • 1° amenorrhea • B/L Inguinal hernia : D/t undescended testes (↑ Risk of malignancy). 	

	Complete AIS		Swyer syndrome
LH	↑	Like PCOS	↑
FSH	Normal		↑
Androgens	↑ (Corresponds to ♂ androgen levels)		↓
mx (To retain ♀ phenotype)	Gonadectomy (B/w 14-16 years : wait for full breast development) ↓ Estrogen replacement therapy ↓ Vaginoplasty		Gonadectomy (At the time of diagnosis) ↓ Estrogen replacement therapy x 1 year (For breast development) ↓ Life long estrogen + progesterone

----- Active space -----

Note :

1. Vaginoplasty :

- Timing : Just before/just after marriage.
- Technique : mcIndoe technique or Laparoscopic Vecchiotti technique.

2. Dysgenetic or undescended testis

- ↑ Chances of malignancy → mx : Gonadectomy.
- m/c gonadal tumour : **Gonadoblastoma**.
- m/c gonadal malignancy : **Dysgerminoma/seminoma**.

3. Streak ovaries → Do not become malignant → **No** gonadectomy

Complete vs. Partial AIS :

Complete AIS	Partial AIS
Complete insensitivity to testosterone	Partial sensitivity to testosterone
Female looking external genitalia	Ambiguous genitalia
Internal genital organs ⊖	male internal genitalia ⊕ (Partially developed)

D/D for AIS (Absent uterus) :

mullerian agenesis : Mayer-Rokitansky-Kuster-Hauser (MRKH) syndrome.

	Features
Karyotype	46XX (IOC : Karyotyping → Rule out AIS)
Anomalies	Both mullerian ducts (MD) : Absent • Fallopian tube, uterus, cervix, upper vagina : ⊖ • A/w renal anomalies : IVP done. • Skeletal anomalies ⊕
Ovaries	Ⓝ → Ovulation
Breast development	Normal (D/t estrogen) → Tanner stage 4/5
Pubic/Axillary hair	Normal → Tanner stage 4/5
LH, FSH, estrogen	Normal
Symptoms	1° amenorrhea, coital difficulties

----- Active space -----

5 α REDUCTASE DEFICIENCYFunction : Testosterone $\xrightarrow{5\alpha\text{-reductase}}$ DHT.

	Features
Genotype	46 XY
Gonads	Testes : Normal but undescended
Sertoli cells	Normal (AMH \rightarrow MD regression)
Leydig cells	Normal (Testosterone \rightarrow WD growth \rightarrow σ internal organs)
external genitalia	♀ at birth (Testosterone ---X--- \rightarrow DHT); Note : Undescended testes \oplus
Pubic/axillary hair	Scanty (D/t absent DHT)
At puberty	Virilization (2 $^{\circ}$ sexual characteristics of σ develops) : <ul style="list-style-type: none"> • Deepening of voice • \uparrow muscle mass • Clitoromegaly (Absent at birth) • Breast development \ominus (Testosterone ---X--- \rightarrow Estrogen) • Hirsutism
FSH, LH, Testosterone	Normal

Partial AIS vs. 5 α Reductase Deficiency :

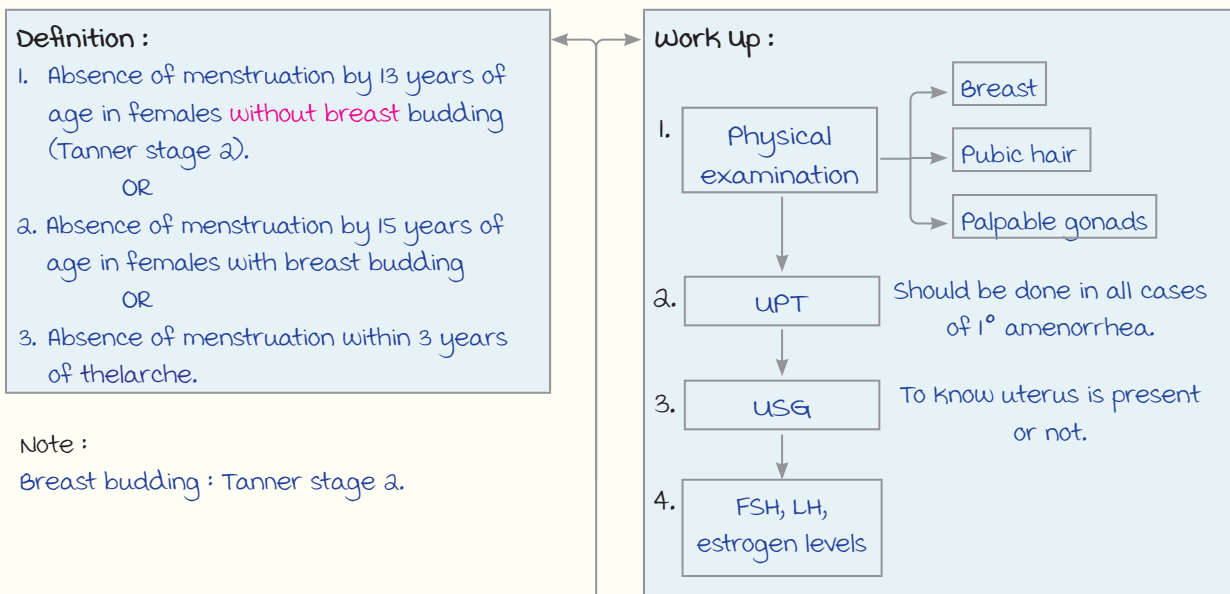
	Partial AIS	5 α reductase deficiency
Onset of clitoromegaly	Since birth	At puberty
Internal genital organs	σ (Partially developed)	σ (Well developed)
Breast development	Tanner stage : 4/5 (Well developed)	Tanner stage : 1 (Absent)

GYNAECOLOGY : PART 7

----- Active space -----

Primary Amenorrhoea : Overview

00:00:10



Note :
Breast budding : Tanner stage 2.

PRIMARY AMENORRHOEA IOC : Karyotyping

Compartment wise causes			
	Organ	Cause	LH, FSH, Estrogen (E)
1	Hypothalamus	Kallmann syndrome (GnRH↓)	FSH : ↓
			LH : ↓
2	Pituitary gland	Craniopharyngioma	E : ↓
			FSH : ↓
3	Ovary	Gonadal dysgenesis : • Turner's syndrome (45 XO) • Swyer's syndrome (46 XY)	LH : ↓
			E/Androgen : ↓
4	uterus absent	• mullerian agenesis (46 XX)	FSH } ⊕
		• Androgen insensitivity Syndrome (46 XY)	LH } ⊕
			E } ⊕
			FSH : ⊕
			LH : ↑
			Androgen : ↑

Hypogonadotropic hypogonadism

Hypergonadotropic hypogonadism

Same as PCOS & cryptomenorrhoea

----- Active space -----

Cryptomenorrhoea & Mullerian Agnesis

D/D : CRYPTOMENORRHEA

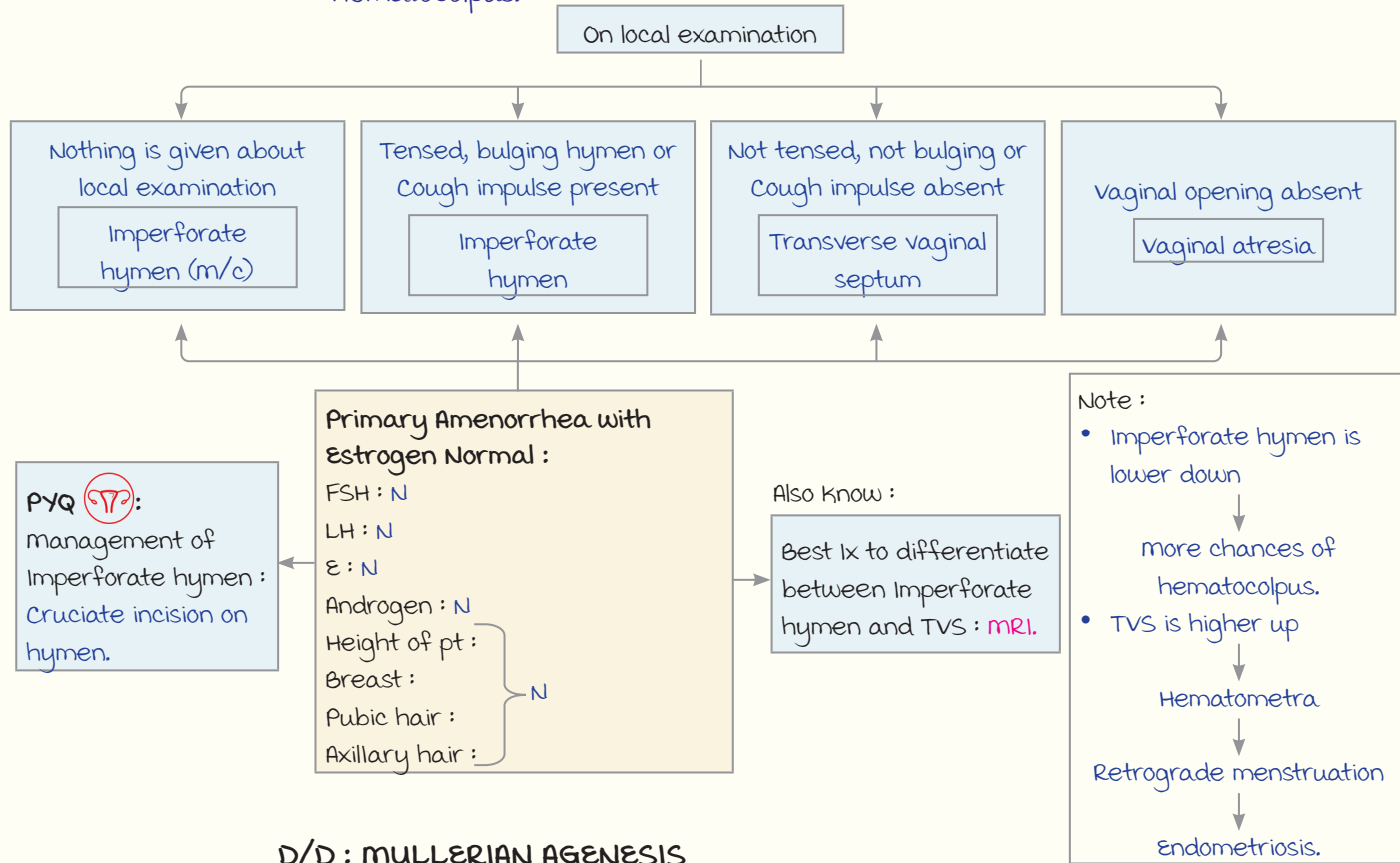
c/f : Pt c/o cyclical pain in abdomen every month.

It means hidden menstruation

- Imperforate hymen.
- Transverse vaginal Septum (TVS).
- vaginal atresia.

On PR examination :

- Bulky uterus (Hematometra).
- Hematocolpus.



D/D : MULLERIAN AGNESIS

Defect : Both mullerian ducts are absent

Ovaries : } (N)

Ovulation, E : } (N)

Ext genitalia : } (N)

Breast : } (N)

Pubic hair : } (N)

Internal genitalia (uterus) : Absent

Sometimes :

- Distal part of fallopian tube (+)
- Entire vagina absent (vaginal atresia)

Ideally :

- Upper vagina : Absent
- Lower vagina : Present

Associated failure :

- Renal anomaly
- Skeletal anomaly

Pt c/o :

1. Primary amenorrhea
2. Difficulty in coitus

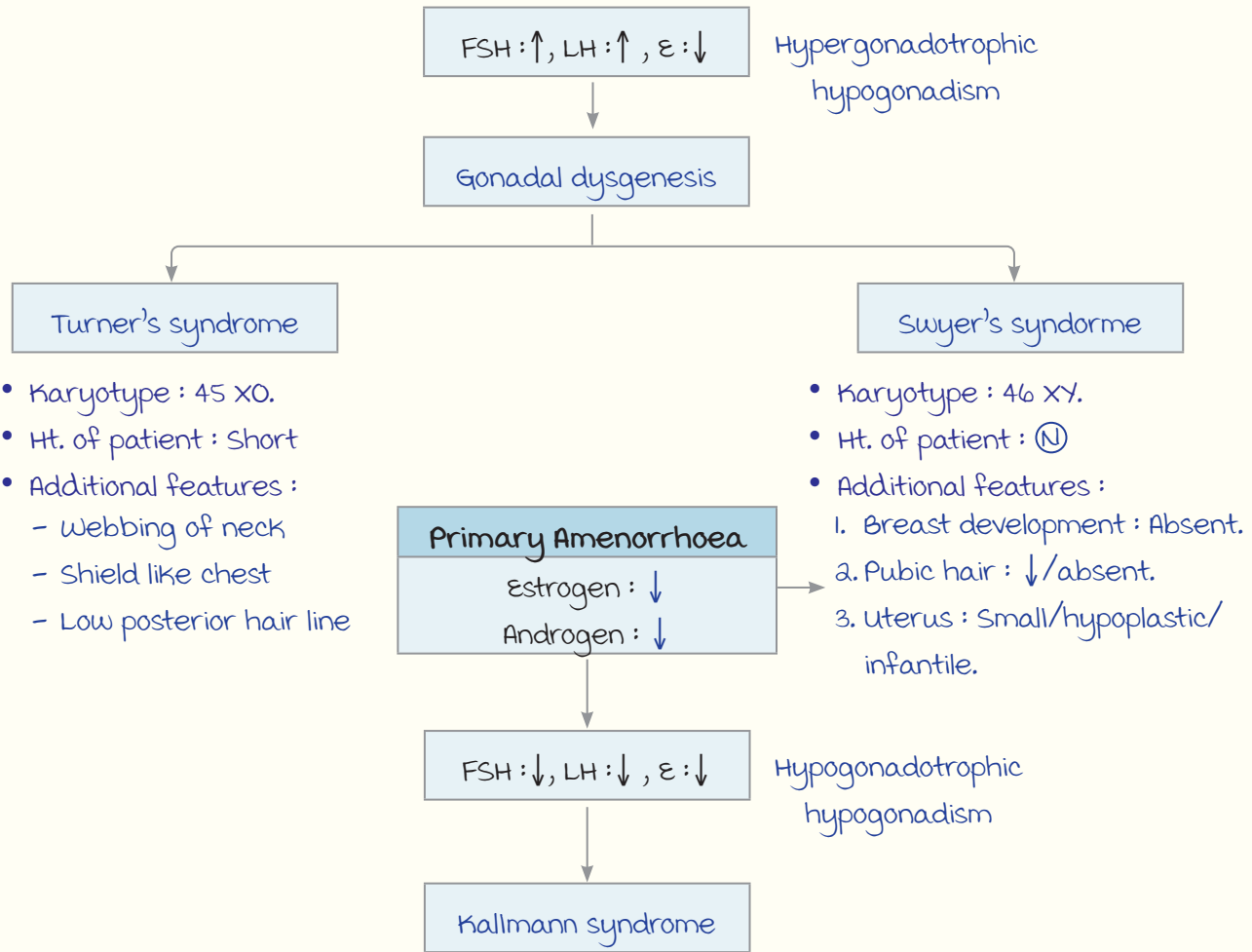
management :

- vaginoplasty technique :
 1. mc Indoe
 2. vecchietti
- Time :
 1. Just before marriage
 2. Just after marriage

Gonadal Dysgenesis & Kallmann's Syndrome

00:17:18

----- Active space -----



- Karyotype : 45 XO.
- Ht. of patient : Short
- Additional features :
 - Webbing of neck
 - Shield like chest
 - Low posterior hair line

- Karyotype : 46 XY.
- Ht. of patient : (N)
- Additional features :
 1. Breast development : Absent.
 2. Pubic hair : ↓/absent.
 3. uterus : Small/hypoplastic/infantile.

Defect : GnRH neurons in olfactory epithelium fail to migrate to Hypothalamus

Pt c/o :

- Primary amenorrhoea.
- Infertility.
- Delayed puberty.

Associated feature : Anosmia.

Can be seen in both : m & F.

m/c : males.

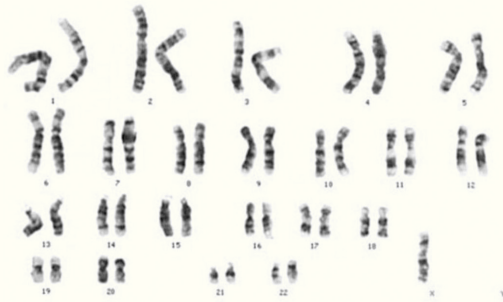
Gene involved : Kal 1 gene.

Stature : (N)

Mx : Pulsatile GnRH.

----- Active space -----

Turner's Syndrome



Karyotyping

- Karyotype : 45 XO, monosomy X
- In some cases : **mosaic**
Turner's seen in 2 cell lines are present :
45XO/46XY
- Gonads : In mosaic
 - One side : Streak ovary.
 - Other side : Dysgenetic testis.
- Remember :
 - Streak ovaries. (Not premalignant)
 - Dysgenetic testes or undescended testes :
↑ Risk of malignancy → Gonadectomy.

TURNER'S SYNDROME

Remember in all cases
of suspected Turners :
Do **Karyotyping**.

Associated features

- Short : mutation in SHOX gene.
- Webbing of neck.
- Low posterior hair line.
- Shield shaped chest.
- Widely spaced nipples.
- SNHL : Sensorineural hearing loss.
- Autoimmune disease :
 - Diabetes.
 - Hashimoto's thyroiditis.
 - Celiac disease.
- Cubitus valgus.
- Heart disease : **Bicuspid aortic valve** > Coarctation of Aorta.

- m/c tumor seen in dysgenetic gonads :
Gonadoblastoma
- m/c malignancy :
Dysgerminoma

Ix :

1. Echo.
2. Renal USG (Turners is associated with **horseshoe shaped kidney**)
3. TSH, T3, T4
4. CBC, Lipid profile, Fasting glucose
5. RFT, LFT
6. Audiometry
7. Anti-endomysial Abs (D/t ↑ risk of celiac disease)

Mx :

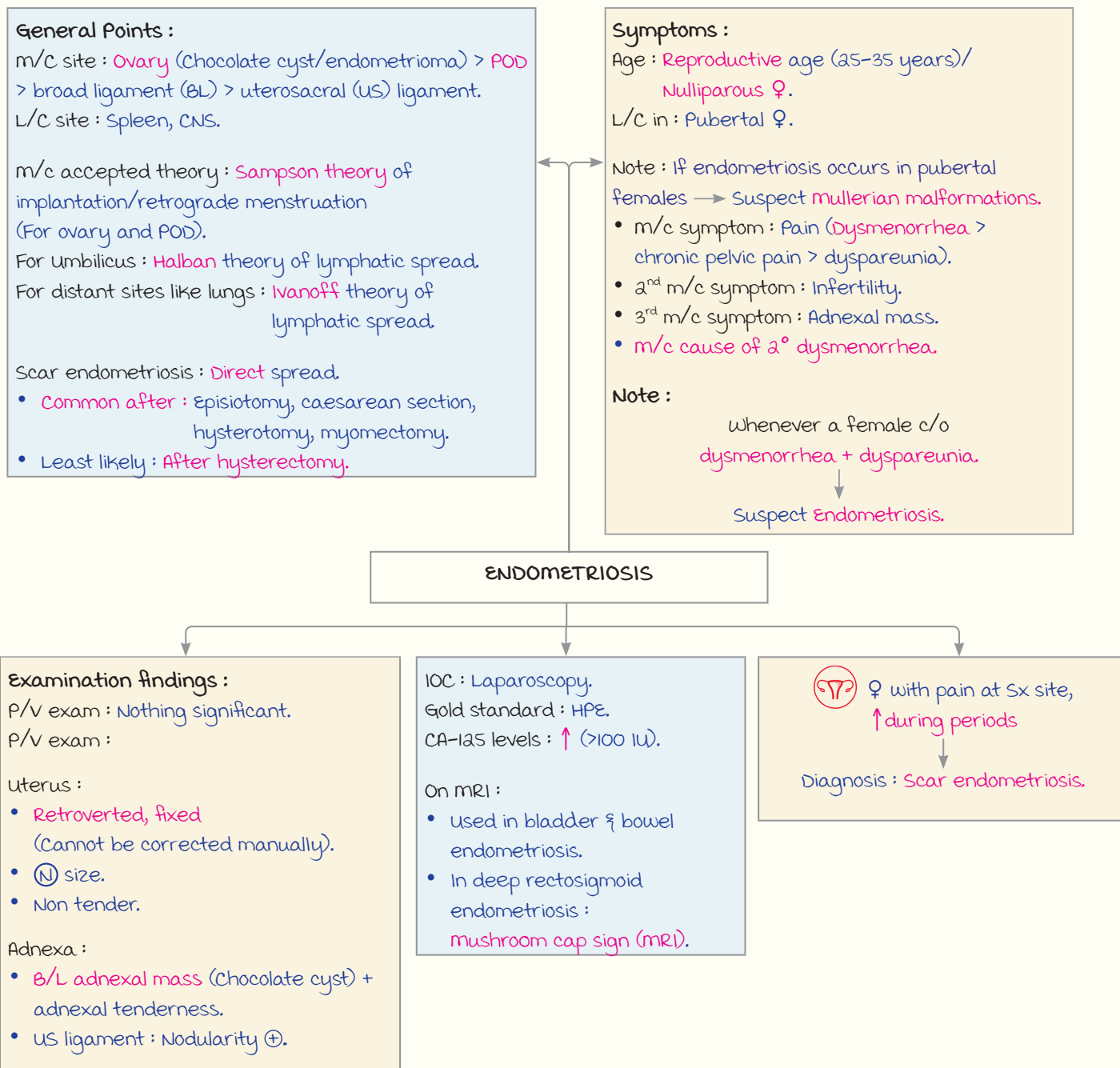
1. GH only till 8 year old.
 2. E alone for 1 yr → E+P : Till normal age of menopause.
- Pregnancy : Relative contraindication.
(D/t cardiac disease)

GYNAECOLOGY : PART 8

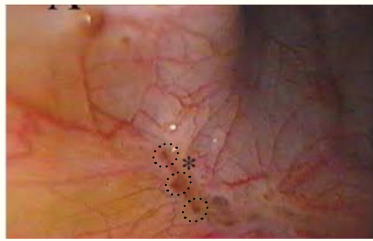
----- Active space -----

Endometriosis

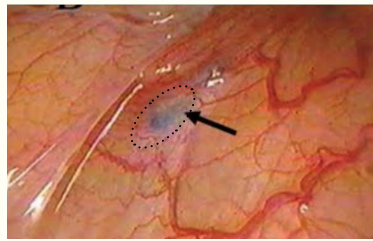
00:00:33



Laparoscopic findings :



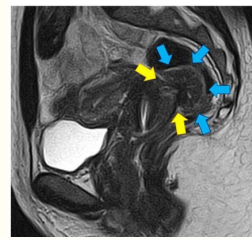
Red flame lesions (New lesions)



Gunshot/powder burn appearance (Older lesions)

Imaging :


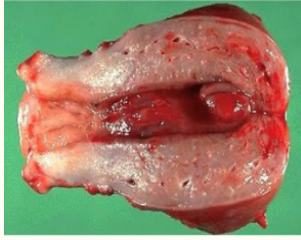
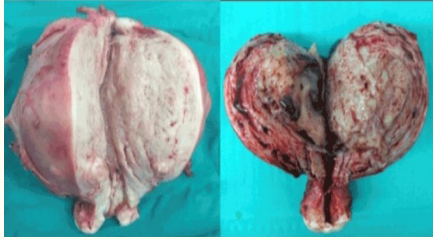
----- Active space -----

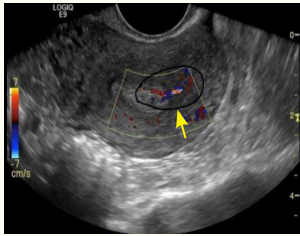
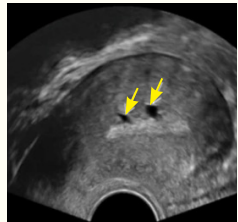


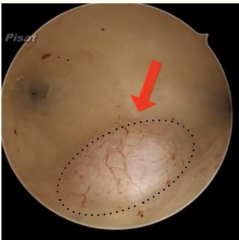
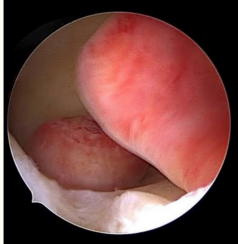


mushroom cap sign (MRI)

Fibroid, Polyp & Adenomyosis

00:16:29

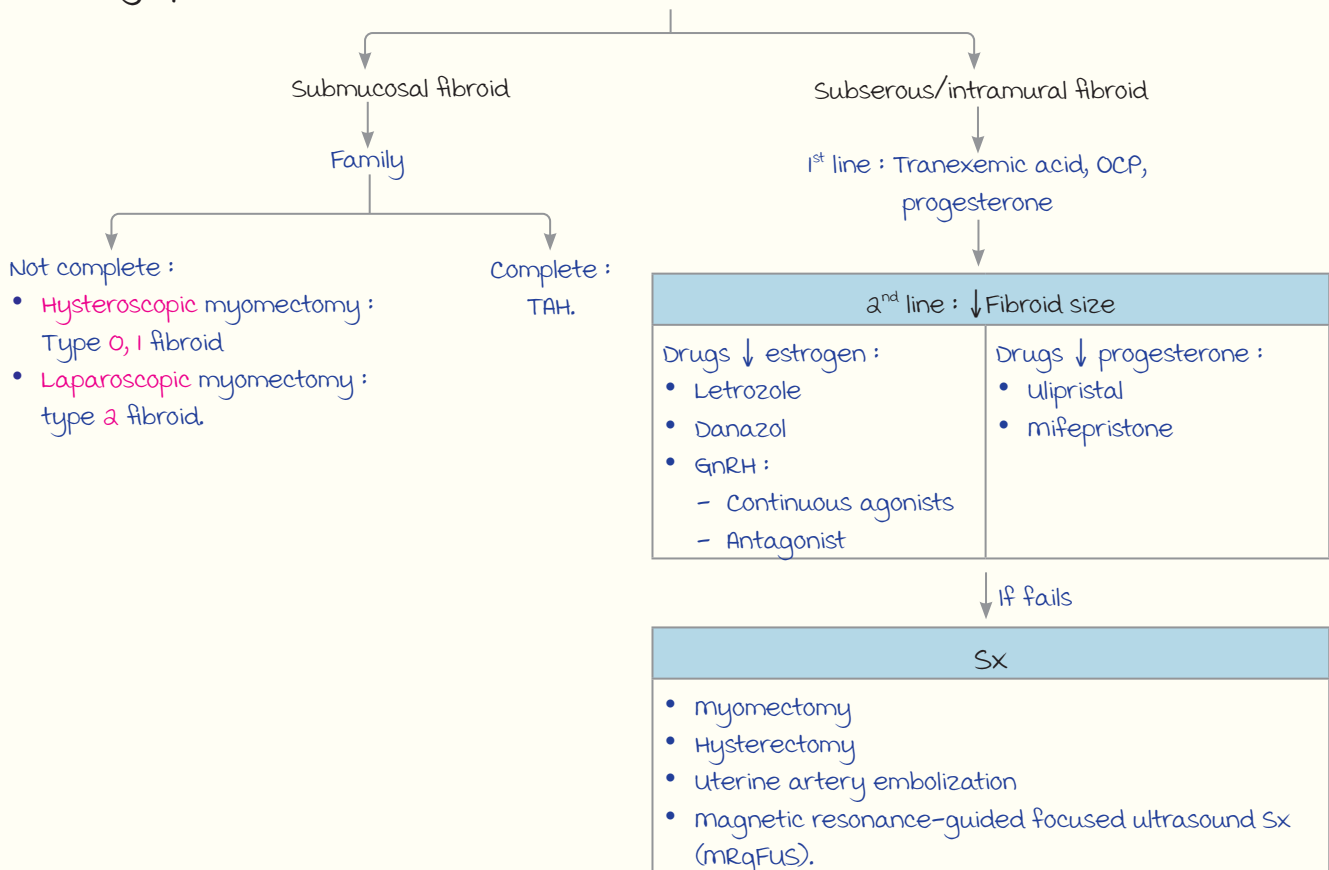
	Fibroid	Polyp	Adenomyosis
Introduction	<ul style="list-style-type: none"> Aka leiomyoma Smooth muscle tumour from myometrium 	Localized outgrowth of endometrium	Endometrial tissue in myometrium
Incidence	<ul style="list-style-type: none"> m/c in reproductive age ♀ (25-35 years) + nulliparous (Hyperestrogenic condition) 	<ul style="list-style-type: none"> Seen : All age groups ↑Age : ↑Polyp chances m/c age : 40-49 years 	<ul style="list-style-type: none"> ≥40 years ♀, multiparous ♀ (m/c)
Association	Estrogen + progesterone dependent tumor	↑Incidence with tamoxifen	Endometriosis and fibroids
Symptoms	<ul style="list-style-type: none"> Heavy menstrual bleeding (HMB)/menorrhagia (Regular cycles) : m/c symptom Other symptoms: <ul style="list-style-type: none"> - 2° dysmenorrhea - Infertility - Pressure symptoms - Pregnancy complications 	<ul style="list-style-type: none"> Reproductive or perimenopausal age : Irregular/intermenstrual bleeding Postmenopausal ♀ : m/c cause of postmenopausal bleed 	<ul style="list-style-type: none"> m/c symptom : menorrhagia + 2° dysmenorrhea Other symptoms : Chronic pelvic pain (CPP)
Gross appearance	 <ul style="list-style-type: none"> Whorled appearance Off-white color Pseudocapsule covering : Contains blood vessels (Center : Least vascular; Periphery : most vascular) Arises from broad base 	 <ul style="list-style-type: none"> Red, mucosal outgrowth Smooth Narrow base Hanging in uterine cavity 	 <ul style="list-style-type: none"> Globular, symmetrically enlarged Cut section : multiple petechial hemorrhages (D/t menstrual bleeding of endometrial tissue)

	Fibroid	Polyp	Adenomyosis
Per abdominal (P/A) examination	<p>Abdominopelvic lump :</p> <ul style="list-style-type: none"> • Unable to converge fingers below lump. • mobile, firm midline mass • Size : upto 20 weeks pregnant uterus 	-	-
Per vaginal (P/V) examination	<p>Bimanual palpation :</p> <ul style="list-style-type: none"> • Abdominopelvic mass : Firm, mobile, cannot be separated from uterus • Asymmetrically enlarged, non-tender uterus • movement of mass : Transmitted to cervix 	Normal	<ul style="list-style-type: none"> • uterus : <ul style="list-style-type: none"> - Globular, symmetrically enlarged - Tender (Halban sign) - Size : 10-12 weeks pregnant uterus (Never ≥ 14 weeks) • Adnexal tenderness \oplus/\ominus
ultrasound findings	<p>On doppler : \uparrow vascularity around periphery</p>	<p>On doppler :</p>  <p>Feeder vessel sign (m/c seen in endometrial polyp)</p>	 <p>myometrial cyst</p>  <p>Venetian blind appearance (Alternating dark & light bands)</p>
Hysterosalpingography (HSG)	<p>Filling defect with regular + smooth outlines</p>		-
On hysteroscopy	<p>Submucosal fibroid : Pale coloured + surface blood vessels</p> 	<ul style="list-style-type: none"> • Red + smooth contour • No surface blood vessels 	-

----- Active space -----

	Fibroid	Polyp	Adenomyosis
Ix	Abnormal uterine bleeding (AUB) : • UPT • TVS	} → >40 years → Endometrial biopsy → Normal (Clinical diagnosis) (Rule out hyperplasia & Ca)	
	• IOC : TVS • Submucosal fibroid : Saline Infusion Sonography (SIS) ↓ IOC • MRI : Not done routinely • Hysteroscopy : Diagnostic	IOC : Hysteroscopy ↓ Diagnostic + therapeutic	• IOC : mRI (Usually not required) ↓ If done Transition zone (Ta) : - ≥12 mm : Adenomyosis - <8 mm : Rules out adenomyosis • Gold Standard Ix : HPE (Post hysterectomy)
management	• Asymptomatic : - Observation - Sx : Large subserous fibroid or infertility • Symptomatic : Depends on type of fibroid	• Endometrial polyp : Hysteroscopic polypectomy • Endocervical polyp : Polypectomy hook	Best : Total abdominal hysterectomy (TAH) ↓ Patient refuses LNG-IUCD (mirena)

mx of Symptomatic Fibroid :



----- Active space -----

Degenerations of Fibroid :

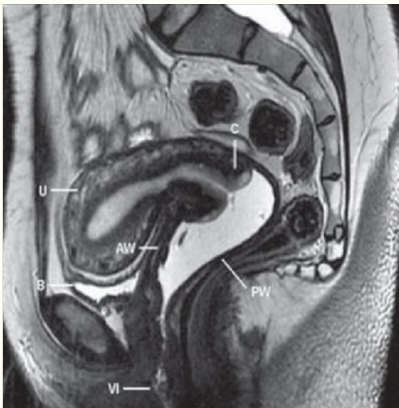- m/c degeneration : **Hyaline** degeneration.
- L/c degeneration : **malignant transformation**.

Red degeneration :

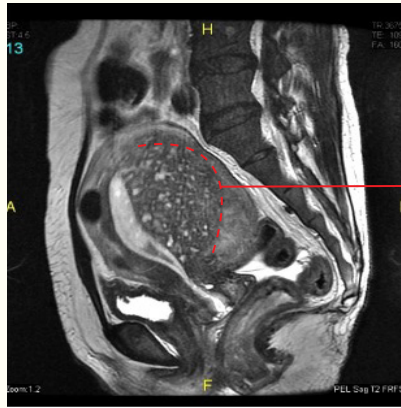
- Seen in **pregnant ♀** (m/c : **2nd trimester** > 3rd trimester).
- Due to : **Aseptic thrombosis** in blood vessels supplying fibroid → **Necrosis** of fibroid.
- C/f : Abdominal pain, nausea, vomiting ± fever.
- Ix : ↑ ESR, ↑ WBC.
- Rx : **Conservatively** (Analgesics, anti-emetics) → if orally not tolerating → IV fluids.

Note :

- Never give antibiotics.
- Never terminate pregnancy.
- Never do myomectomy.

MRI Finding of Adenomyosis :

Normal MRI



Adenomyosis

Transition zone (TZ) : ≥12 mm

Pelvic Inflammatory Disease (PID)

00:42:44

----- Active space -----

Definition : Inflammation of upper female genital tract
(uterus, fallopian tubes, ovaries and peritoneum).

- PID is sexually transmitted.
- m/c cause of PID : Polymicrobial.
- 2nd m/c cause : Chlamydial > Gonococcal.
- m/c cause of acute PID : Gonorrhoea.
- m/c cause of PID in virgin female : Genital TB (Hematogenous spread).
- m/c cause of PID in IUCD users : Actinomyces.
- NACO : Syndromic mx of PID

DOC for chlamydia :

Azithromycin 2 g single dose
OR

Doxycycline 100 mg BD x 7 days
+

Treat symptomatic partner.

DOC for gonorrhoea :

Inj ceftriaxone 500 mg I/m single dose
OR

T. Cefixime 800 mg single dose
+

Treat symptomatic partner.

CDC Criteria for diagnosis of PID :

minimum criteria :

Lower abdominal pain (m/c Symptom) + any of following :

- Cervical movement tenderness.
- Adnexal tenderness.
- uterine tenderness.

Additional Criteria :

- Fever.
- mucopurulent discharge.
- microscopy of discharge : Shows abundant WBC.
- Raised ESR.
- Raised CRP.
- Lab test for chlamydia/gonorrhoea.

Specific Criteria :

- Endometrial biopsy : Endometritis.
- TVS/MRI
- Laparoscopy : Pus oozing from fimbrial end.

PID

Note : Always rule out ectopic pregnancy.

Signs on USG :

- Adhesions inside tube.
- Adhesions in peritoneal cavity.
- Hydrosalpinx.
- Beads on string appearance.
- Waist sign.
- Cogwheel sign.

Note : Beaded appearance on
HSG → Genital TB

Laparoscopy in PID :

- Gold standard investigation.
- With laparoscopy tubes, adnexa can be visualized directly.
- Scoring for conception can be done : BOER-MEISEL Score.
- Specimen can be collected.

Staging of PID :

Gainesville staging.

Stage 1 : No peritonitis.

Stage 2 : Peritonitis present.

Stage 3 : Tubo ovarian mass/
abscess.

Stage 4 : Ruptured tubo ovarian
mass.

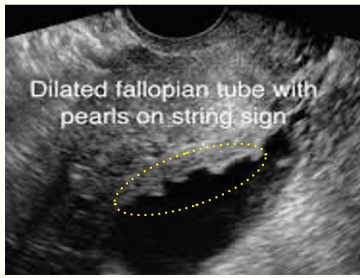
Fitz Hugh Curtis syndrome :

- Adhesions are formed between liver and anterior abdomen which have violin string appearance.
- m/c in Chlamydia > Gonorrhoea.

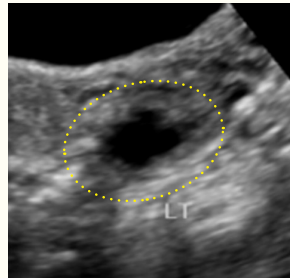
Long-term Consequences :

- Infertility (m/c).
- Ectopic pregnancy.
- Hydrosalpinx.
- Chronic pelvic pain.
- Recurrent PID.
- Fitz Hugh Curtis syndrome.

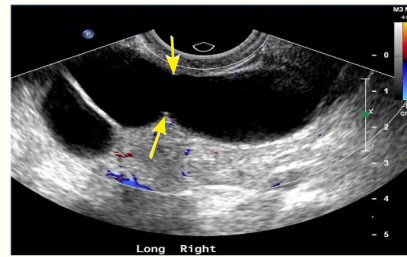
----- Active space ----- USG Findings of PID :



Beads on string appearance

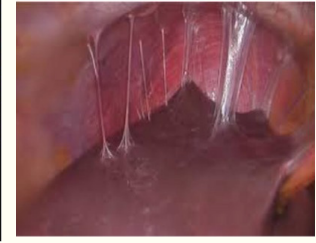

Cogwheel sign



Waist sign

Fitz Hugh Curtis syndrome :



Violin string adhesions

Genital TB

00:50:10

m/c secondary infection.

m/c 1^o site : Lungs > lymph nodes.

m/c route of spread : Hematogenous.

m/c site : Fallopian tube (Ampulla) > uterus.

L/c site : vulva, vagina.

m/c route of spread for endometrial TB : Direct spread.

Symptoms :

- Infertility (m/c) : D/t bilateral cornual block.
- Pain (2nd m/c) : Chronic pelvic pain/dysmenorrhea.
- menstrual irregularity : metrorrhagia $\xrightarrow{f/b}$ Amenorrhea
(D/t endometritis) (D/t Asherman syndrome)
- Systemic symptoms : weight loss, fatigue, evening \uparrow of temperature, \downarrow appetite.

On Examination :

- P/A : Doughy abdomen + ascites.
- P/V :
 - Reproductive age ♀ : Normal.
 - Pubertal ♀ : B/L adnexal mass.

Ix:

IOC : Endometrial biopsy (In pre-menstrual phase).

In virgin ♀ \rightarrow Collect day 1 of menstrual blood (Endometrial biopsy not done).

Treatment :

- Rx for genital TB : ATT x 6 months (Can improve fertility).
- Rx for infertility in genital TB : In-vitro fertilization
(In distorted pelvic anatomy).

Note :

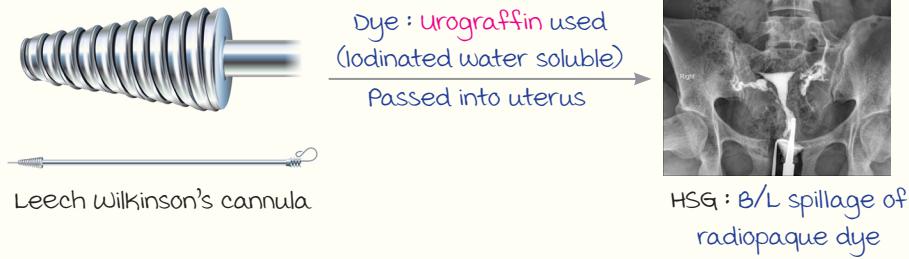
Give ATT $\frac{f}{b}$ → HSG (In patients with active genital TB to avoid infection spread).

----- Active space -----

Hysterosalpingography (HSG)

00:55:33

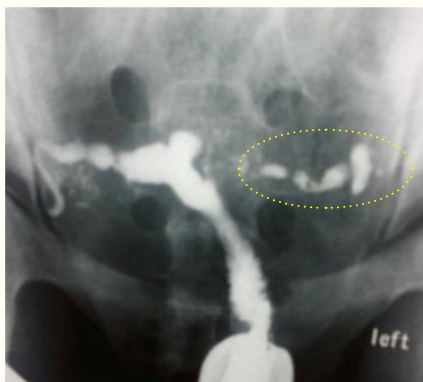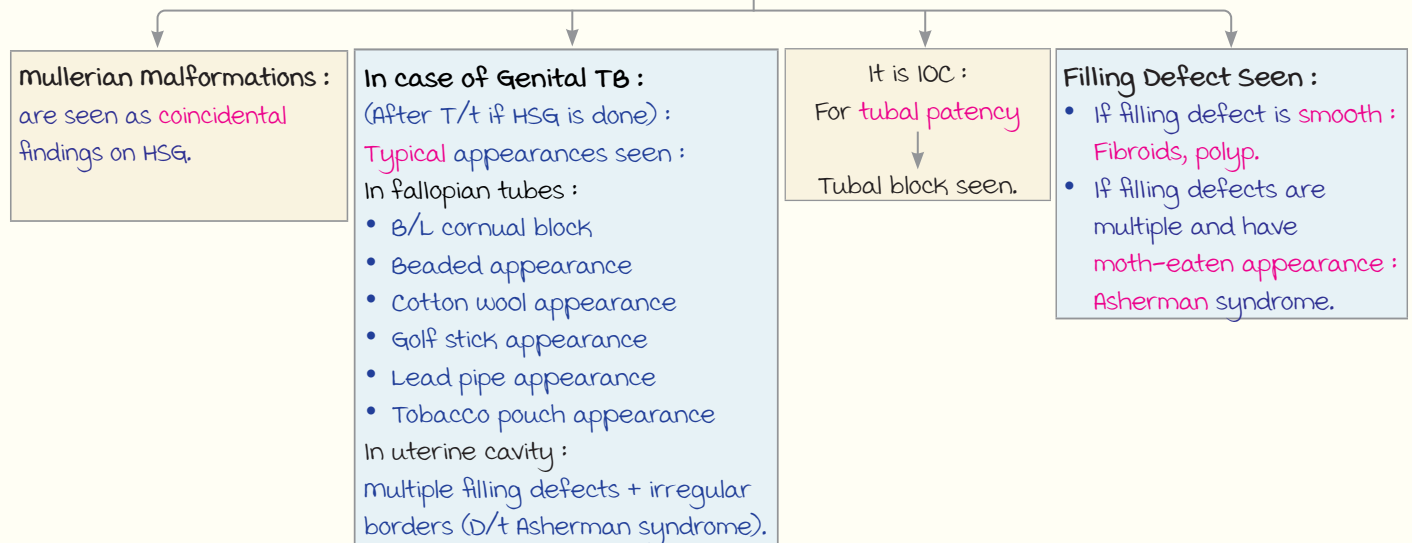
Procedure :



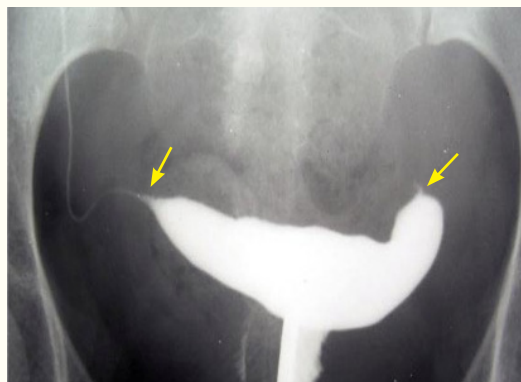
Timing : Done in pre-ovulatory phase : Day 7-10.

C/I : Pregnancy, active PID, active genital TB.

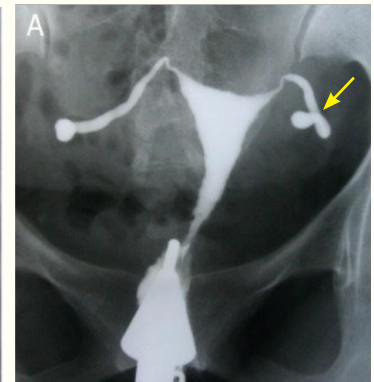
USES OF HSG



Beaded appearance

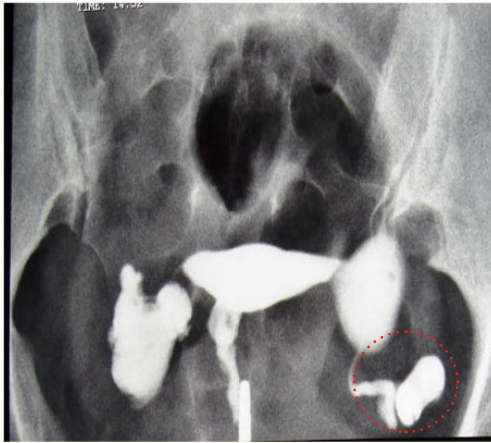

B/L Cornual block

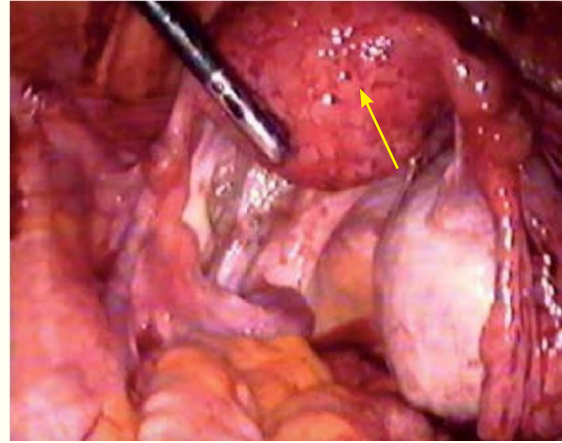


Golfstick appearance

----- Active space -----



Tobacco pouch appearance



Genital TB on laparoscopy

Vaginitis

01:00:12

Features of Normal Vaginal Discharge :

Normal pH of vagina : 4-4.5.

2 requirements for acidic vaginal pH :

- **Estrogen** → Presence of glycogen in epithelium.
- **Doderlein bacilli** : Convert glycogen → Lactic acid.

Note : vagina has no glands, cervical pH : 6-8.

pH of vagina in different age groups :

Age	pH
Before puberty	Alkaline (6-8)
At puberty (Doderlein bacilli appear)	Alkaline → Acidic
Reproductive age	Acidic (4-4.5)
Pregnancy (Doderlein bacilli ↑)	more acidic (3.5-4)
menstruation	Alkaline (6-8)
After menopause (Doderlein bacilli disappear at menopause)	

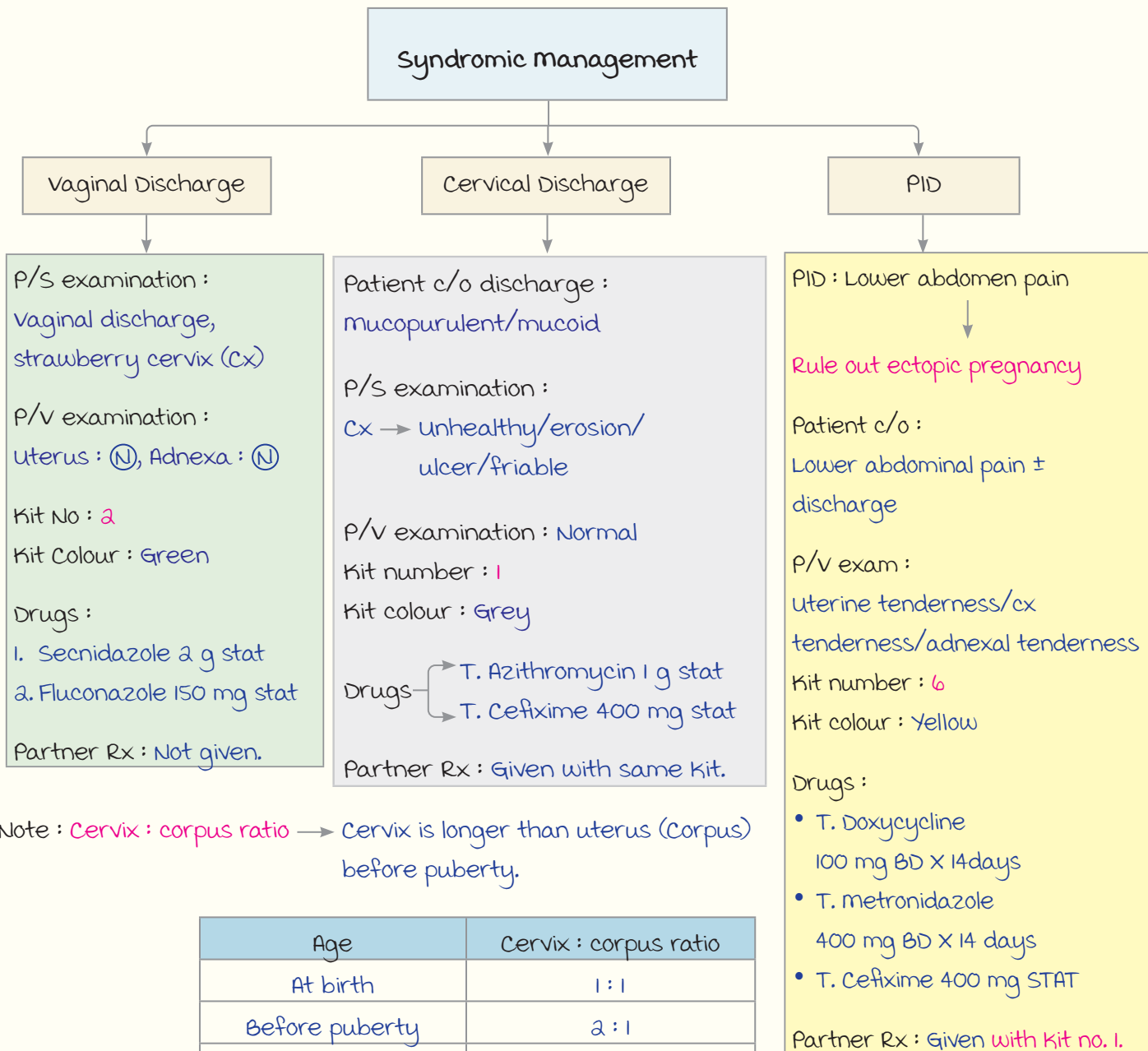
Vaginal Discharge D/D :

----- Active space -----

	Physiological leucorrhoea	Bacterial vaginosis	Trichomonas vaginitis	Candidiasis
Organism	-	<ul style="list-style-type: none"> Gardnerella Mobilincus 	Trichomonas vaginalis (Flagellated protozoa)	Candida albicans
Discharge	Colourless + odourless	Colourless + fishy odour (D/t alteration in vaginal flora)	Yellowish-green in colour + foul smell	Cottage cheese like/ curdy white
pH	4-4.5	≥4.5		< 4
Pruritis	⊖	⊖	⊕	Intense pruritus (main complaint)
IOC : Saline microscopy	-	Clue cells (Vaginal epithelial cells + adherent bacteria)	motility ⊕	Pseudohyphae ⊕
Gold standard	-	Gram staining ↓ Nugent score	Culture	Culture
Other features	-	<ul style="list-style-type: none"> Amsel criteria ⊕. Whiff test ⊕. 	On P/S : Strawberry cervix	<ul style="list-style-type: none"> c/f : splash dysuria m/c vaginitis in pregnancy, DM, HIV, OCP & steroid users.
management	-	Oral metronidazole 500 mg TDS x 5-7 days (DOC) ↓ Avoided in 1 st trimester of pregnancy		<ul style="list-style-type: none"> DOC in non-pregnant ♀ : Oral fluconazole DOC in pregnancy : Clotrimazole (Topical imidazole)
Partner Rx	-	Not done (Not sexually transmitted)	Done (Sexually transmitted)	Not done unless symptomatic

Amsel's criteria in bacterial vaginosis :

- Thin homogeneous discharge.
 - ≥20% clue cells.
 - pH ≥4.5.
 - Whiff test ⊕ :
10% KOH added to vaginal discharge
↓
Fishy/amine odour
- Any 3 out of 4 present : ⊕



GYNAECOLOGY : PART 9

----- Active space -----

Infertility

00:00:08

Definition : Inability to conceive even after 1 year of unprotected intercourse.


Investigations (Following Unprotected Intercourse) :

Age of female	Ix timing
<35 years	1 year
≥35 years	6 months
≥45 years	3 months

Basic Ix :

- Semen analysis.
- Test for ovulation : S. Progesterone in female on Day 22 of cycle (D22).
- Test for tubal patency : Hysterosalpingography b/w D7 - D10.

Causes of Female Infertility :



Note : male infertility.

- m/c cause : Testicular causes → Abnormal spermatogenesis.
- m/c reversible cause : Varicocele.

WHO classification of ovarian causes :

	FSH	Estrogen	Condition	Example
Class I	↓	↓	Hypogonadotrophic hypogonadism	Kallmann syndrome
Class II	Ⓝ	Ⓝ	Normogonadotrophic normogonadism	Anovulation/PCOS
Class III	↑	↓	Hypergonadotrophic hypogonadism	Premature ovarian insufficiency

Not classified : Hyperprolactinemia.

----- Active space -----

Tests for Ovulation

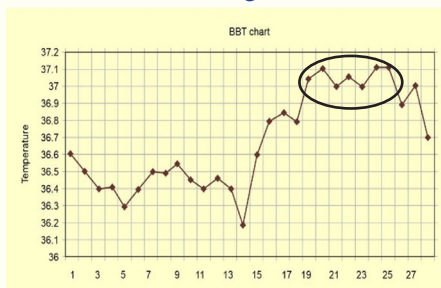
00:04:58

History :

Ovulatory cycles	Anovulatory cycles
<ul style="list-style-type: none"> Regular cycles. Mittelschmerz syndrome (C/O midcycle pain). Dysmenorrhea. Premenstrual syndrome. 	<ul style="list-style-type: none"> Painless, irregular, heavy bleeding. <p>Note : Due to estrogen breakthrough, not progesterone withdrawal.</p>

Basal Body Temperature :

midcycle ↑ temperature
(Biphasic graph).

**Cervical mucous Study :**

	Estrogen	Progesterone
Consistency	Profuse, watery, elastic	Thick, scanty, viscous
Known as	Spinnbarkeit (Stretching ⊕)	Known as Tack (Stretching ⊖)
Ferning	Seen under microscope on D ₈	Disappears by D ₈ of cycle

Hormonal Study :

Progesterone levels D₂₂ of cycle : >10 ng/mL (Best & easiest).

Vaginal Epithelial Study :

- Sample : Lateral wall of vagina.
- Epithelium : Stratified squamous (3 cell types).

	Superficial cells	Intermediate cells	Parabasal cells
microscopy			
Appearance	Pink, polygonal	<ul style="list-style-type: none"> Blue, polygonal Regular outline 	<ul style="list-style-type: none"> Blue Hazy outline
Nuclei	Pyknotic nuclei	Small nuclei	Big nuclei
Hormone	Estrogen	Progesterone	No hormone
Condition	Follicular phase	Luteal phase	Prepubertal, menopause, puerperium

maturation index : 100 cells counted, written as A/B/C.

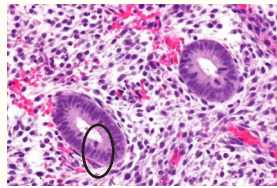
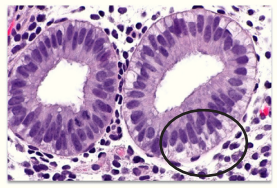
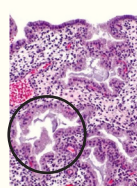
----- Active space -----

A : No. of parabasal cells.
 B : No. of intermediate cells.
 C : No. of superficial cells.

- 100/0/0 : menopause.
- 0/40/60 : 1st half of menstrual cycle (mc).
- 0/60/40 : 2nd half of mc/pregnancy.

Endometrial Biopsy :

- Not commonly done for ovulation.
- Timing : D₂₆ (Pre-menstrual phase).

	Early proliferative	Early secretory	Late secretory
microscopy			
Features	<ul style="list-style-type: none"> • Simple tubular glands • Telescoping of gland • Pseudostratification (Nuclei at different levels) 	<p>Subnuclear vacuolation : First sign of ovulation on biopsy (D₁₇ - D₁₈)</p>	<ul style="list-style-type: none"> • Corkscrew glands • Sawtooth appearance • Secretions in gland

TEST TO PREDICT OVULATION

Urinary LH Surge :

Occurs 24 hrs before ovulation (Blood LH surge occurs 32-36 hrs before ovulation).

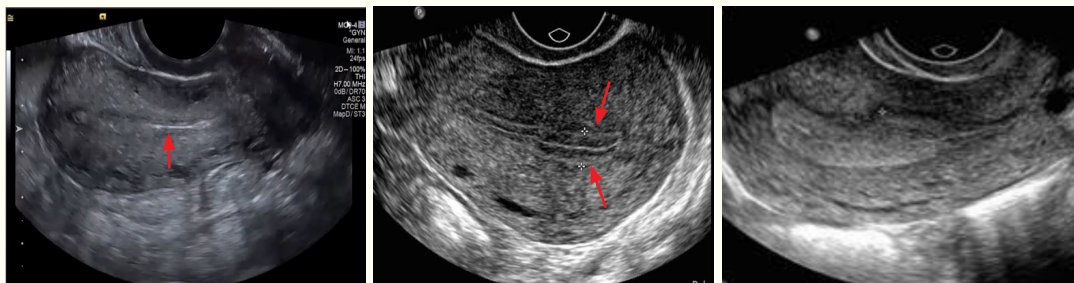
Follicular monitoring :

- m/c done.
- TVS done from D₁₀ on alternate days.

Ovulation (+) : ≥17 mm follicular size $\xrightarrow{F/b}$ Sudden decrease + Fluid in POD ξ
 Triple layered endometrium

Note : Follicle grows 1-2 mm/day.

USG :



Early proliferative phase :
 Single white line in endometrium

Late proliferative >
 Ovulatory phase :
 Trilaminar endometrium

Secretory phase :
 • Thick endometrium
 • Posterior enhancement

----- Active space -----

Management for Anovulation

00:20:35

	Condition	DOC
HPO axis : Normal	Anovulation (Overall)	Clomiphene citrate (CC)
	PCOS	Letrozole > CC
HPO axis : Abnormal	Pituitary ablation	Synthetic LH + FSH
	IVF-related hyperovulation	HMG (Human menopausal Gonadotropin)
	Kallmann syndrome	Pulsatile GnRH

Premature Ovarian Insufficiency (POI)

00:22:20

Physiology :

- FSH → Granulosa cells → Inhibin B, Estrogen & AMH.
⊖ ↑
- LH → Theca cells → Androgens.

Tests for Ovarian Reserve :

D2 - D3 of cycle :

- Inhibin B : ↓.
- FSH : ↑.
- Antral follicle count : ↓ (<10 in both ovaries).

Any day :

AMH : ↓ (Best).

Anti-mullerian hormone
Glycoprotein, produced by granulosa cells of preantral and small antral follicles.
• Normal value of AMH : 1-3.
• Less AMH (<1) : Seen in poor ovarian reserve.
• High AMH (>3) : PCOS.

Note :

- Outdated test : Clomiphene citrate challenge.
- Test not done for ovarian reserve :
 - S. progesterone levels.
 - S. estradiol levels.

Indications for Ovarian Reserve Testing :

- Age of female ≥35 years.
- Family h/o POI.
- H/o radiotherapy/chemotherapy.
- Unexplained infertility.

management :

Donor eggs + IVF.

Tubal Causes of Infertility

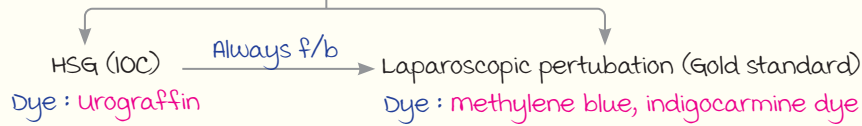
00:26:36

----- Active space -----

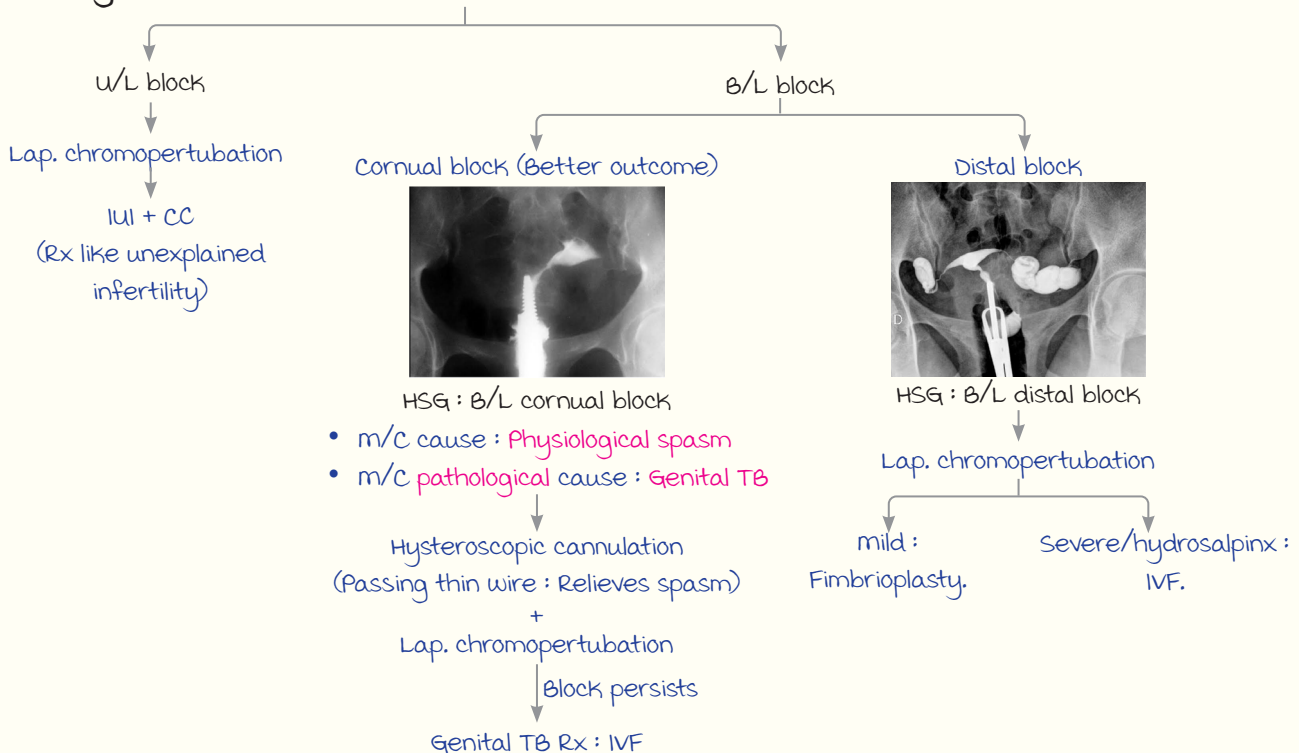
Causes :

- Genital TB
 - Pelvic inflammatory disease
 - Endometriosis
- Tubal blocks.

Investigations :



management :



Note :

Fluid in hydrosalpinx is embryotoxic : Salpingectomy $\xrightarrow{F/b}$ IVF.

Cervical & Uterine Causes of Infertility

00:33:10

Cervical/Immunological Cause :

Etiology : Antisperm Abs in cervix.

Ix :

- Sims test/post coital test/Huhner test : D₁₂ - D₁₄ of cycle.
- Outdated as treatment is same as unexplained infertility.

mx : CC + IUI (3 cycles).

----- Active space -----

Uterine Causes :

- m/c cause : Submucosal fibroid
 - Type 0, 1 ^{mx} → Hysteroscopic myomectomy.
 - Type 2 → Laparoscopic myomectomy.
- mullerian malformation : **Septate uterus** (m/c).
- Asherman's syndrome.

Note : Timing of tests.

Test	Day of cycle
<ul style="list-style-type: none"> • All tests for ovulation except follicular monitoring 	<ul style="list-style-type: none"> • D₂₂ (1 wk before menstruation) • D₁₀
<ul style="list-style-type: none"> • Tests for ovarian reserve except AMH 	<ul style="list-style-type: none"> • D₂ - D₃ • Any day
HSG	D ₇ - D ₁₀
Post coital test	D ₁₂ - D ₁₄

Rx of Infertility

00:37:30

Technique	Pre-requisite	Process	Indications & C/I
Intrauterine Insemination (IUI)	Sperm count minimum : 10 million/mL	Processed sperm (↑ quality) injected into female uterus with catheter	Indications : <ul style="list-style-type: none"> • mild oligospermia (≥10 million/mL) • minimum to mild endometriosis • unexplained infertility • Female vaginismus • Cervical factor infertility • Failure of erection in males
In vitro fertilization (IVF)	Sperm count : <ul style="list-style-type: none"> • minimum : 5 million/mL • Per oocyte : 50,000 - 1 lakh 	Drugs used for hyper ovulation : HMG	• Indications : <ul style="list-style-type: none"> - B/L tubal block - mullerian agenesis (mx : IVF & surrogacy) - ↓ Ovarian reserve - Severe endometriosis - Genital TB : Distorted anatomy - male : Oligospermia & sperm count → 5-10 million/mL • C/I : <ul style="list-style-type: none"> - Sperm count < 5 million/mL - Azoospermia - Asthenospermia
Intracytoplasmic sperm injection (ICSI)	Sperm needed per oocyte : 1	-	Indications : <ul style="list-style-type: none"> • Indications + C/I of IVF • Severe oligospermia

mx of testicular azoospermia :

Surgical procedures to retrieve sperm :

- TESA : Testicular sperm aspiration.
- TESE : Testicular sperm extraction.
- PESA : Percutaneous epididymal sperm aspiration.
- MESA : microsurgical epididymal sperm aspiration.

F/b → ICSI.

----- Active space -----

Semen Analysis

00:42:10

- Done after 2-7 days of abstinence.
- Sample should reach lab within 1 hr.
- Analysis done on liquified sperm (Liquefaction time : 20-30 mins).

Note :

- Sperms attain maturity : Proximal part of epididymis.
- Sperms attain motility : Distal part of epididymis.

Updated WHO Criteria for Analysis (2022) :

WHO semen analysis gives minimum criteria for **conception** (Not average values).

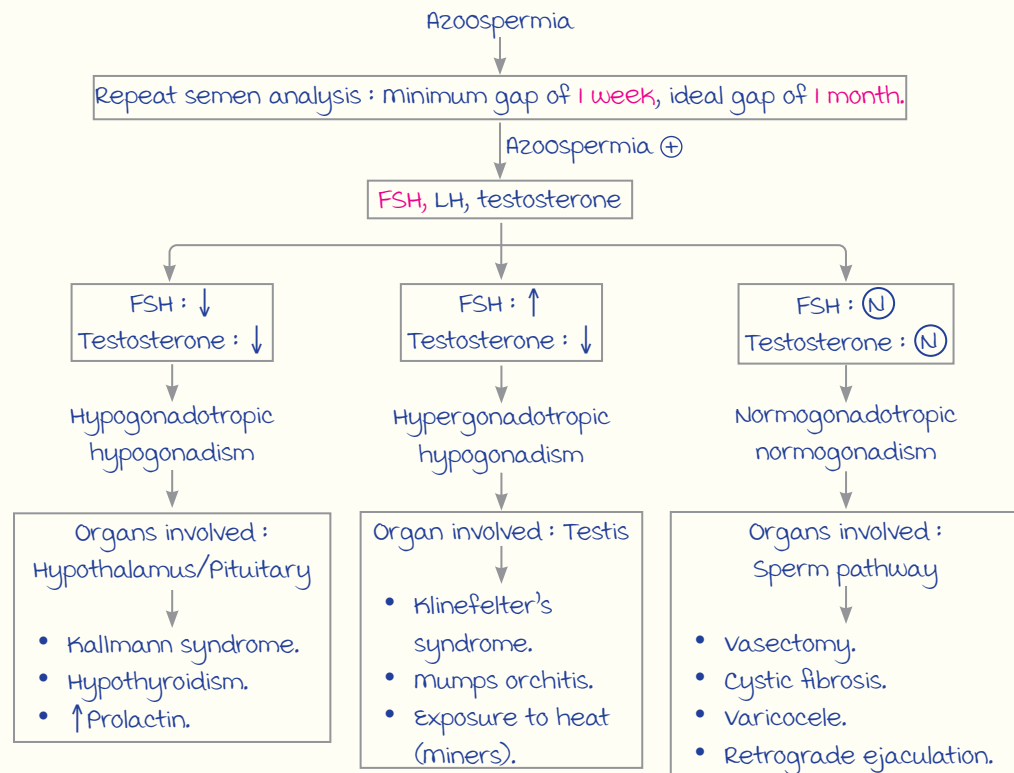
most important semen analysis parameter : morphology > motility > concentration.

Parameters that remain unchanged in new criteria :

- Total sperm count : 39 million/ejaculate.
- Sperm morphology : 4% according to strict Tygerberg criteria.

Parameter	New value	Abnormal semen analysis
Semen volume	1.4 mL	Absent semen : Aspermia
Total sperm no. (million/ejaculate)	39	-
Sperm concentration	16 million/ mL	<ul style="list-style-type: none"> • <16 million/mL : Oligospermia • <5 million/mL : Severe oligospermia • No sperm in semen : Azoospermia
Total motility	42%	↓ : Asthenospermia
Progressive motility	30%	-
Non-progressive motility	1%	
Immotile sperm	20%	
Viability	54%	↑ non-viable sperms : Necrozoospermia
morphology pH = >7.2	4%	Abnormal : Teratozoospermia

----- Active space ----- **management of Abnormal Semen Analysis :**



Note : Sperm pathway

- Testis : Spermatogenesis.
- Epididymis.
- Vas deferens.
- **Seminal vesicle (SV)** : Secretions → majority of semen, **fructose**.
- Ejaculatory duct.
- **Prostate** : Secretions make semen **acidic**.
- **Bulbourethral/Cowper's gland** : Secretions released only during **intercourse**.

Sperm Disorders

00:48:40

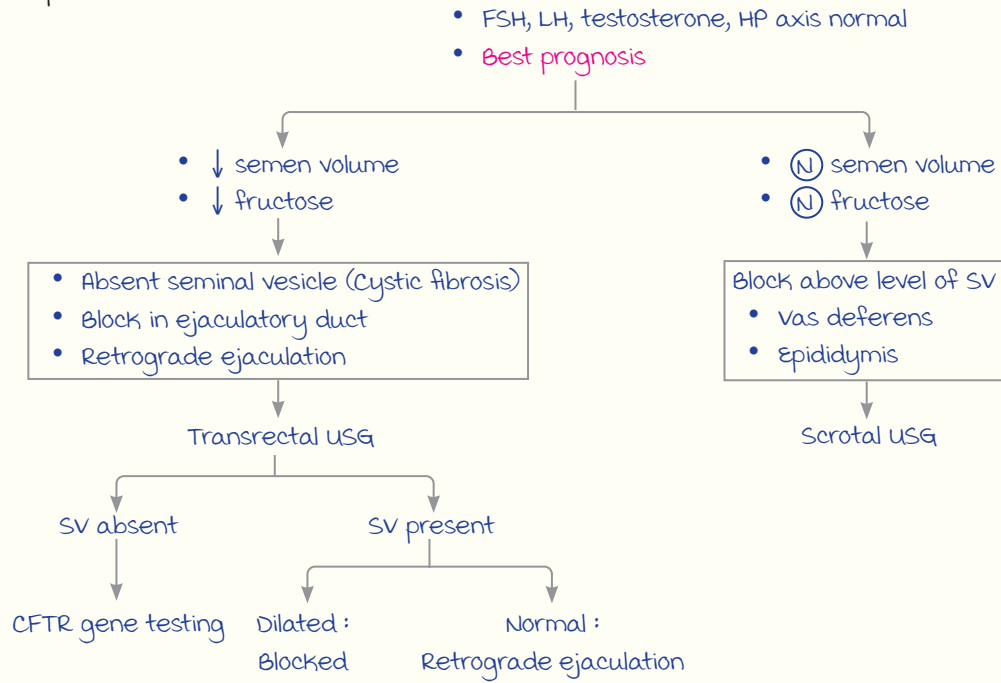
Causes :

Azoospermia	Asthenospermia	OATS (Oligospermia/ Asthenospermia/ Teratozoospermia)
<ul style="list-style-type: none"> • Cystic fibrosis : B/L absence of vas deferens & seminal vesicles. • Klinefelter's syndrome : <ul style="list-style-type: none"> - Testes : Small & hypoplastic - Tall men, long limbs - Gynaecomastia 	<ul style="list-style-type: none"> • Kartagener's syndrome : Immobile cilia syndrome • Varicocele 	<ul style="list-style-type: none"> • Smokers • Varicocele

Obstructive azoospermia :

----- Active space -----

Work-up :



Management of Male Infertility

00:53:26

Condition	mx
Oligospermia (10-15 million/mL)	IUI
Oligospermia (5-10 million/mL)	IVF
Severe oligospermia	ICSI
Azoospermia non-obstructive	
Azoospermia obstructive	Resection & anastomosis
Erectile dysfunction	Sildenafil
Premature ejaculation	SSRI : Fluoxetine
Ejaculatory dysfunction (Hypospadias)	IUI
Retrograde ejaculation	

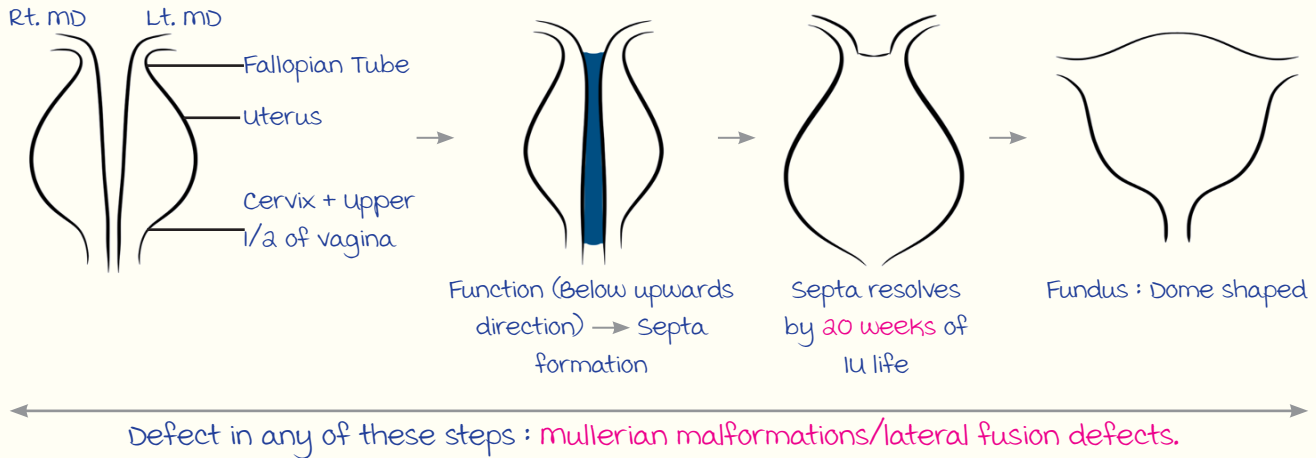
GYNAECOLOGY : PART 10

----- Active space -----

Mullerian Malformations

00:00:37

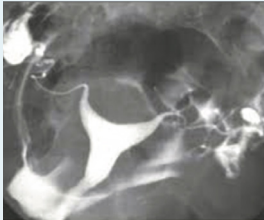
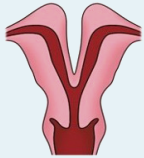

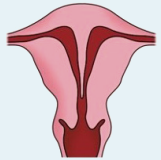

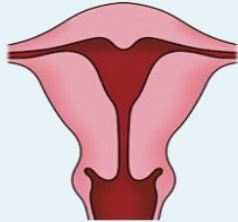
Female internal genital organs : Formed by mullerian ducts (MD).



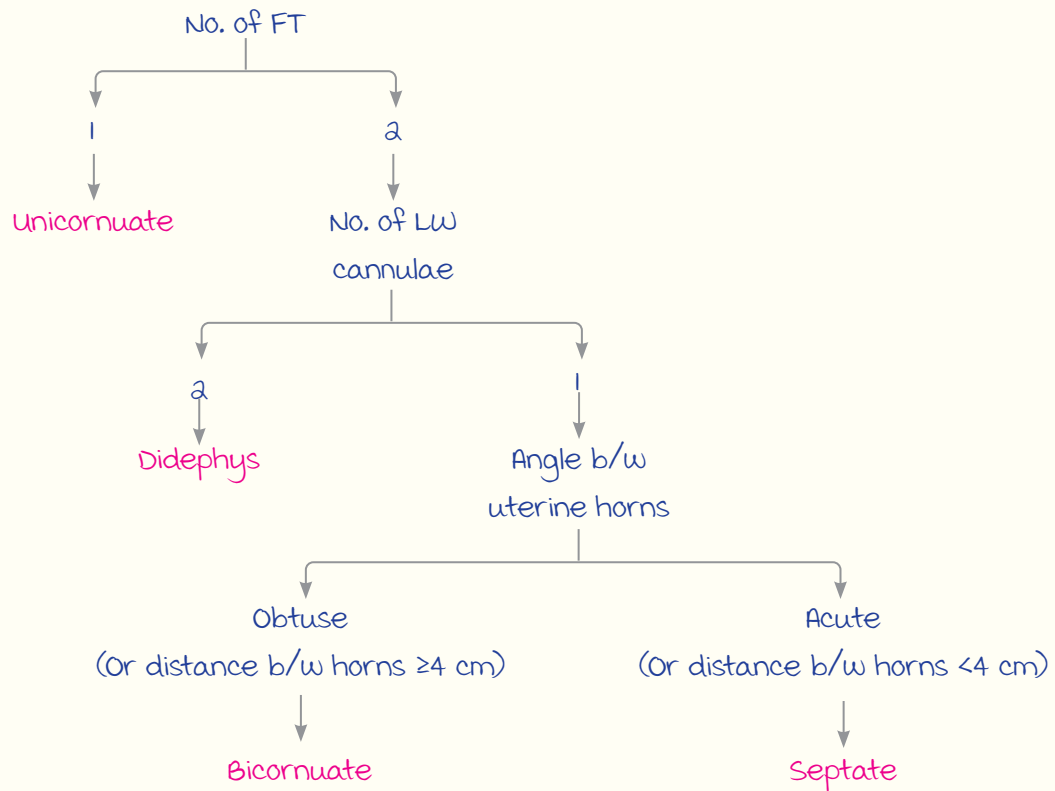
MULLERIAN MALFORMATIONS

	HSG Image	Comment
Class I : mullerian agenesis (Both mullerian ducts absent)	—	<ul style="list-style-type: none"> Ovary : (N) Ovulation : (N) Estrogen : (N)
Class II : unicornuate uterus <ul style="list-style-type: none"> A/w : <ul style="list-style-type: none"> Ectopic ovary Ectopic pregnancy Rupture uterus u/L dysmenorrhea Not seen : Transverse lie 	<p>Leech-wilkinson cannula</p> <p>Unicornuate uterus</p>	<ul style="list-style-type: none"> Only one MD present ± rudimentary horn <ul style="list-style-type: none"> FT : 1 uterus : 1/2 cervix : 1/2 upper vagina : 1/2 On HSG = <ol style="list-style-type: none"> Single fallopian tube (FT) Banana shaped uterus m/c uterine malformation a/w renal anomalies.
Class III : uterus didelphys <ul style="list-style-type: none"> If both MD are present but <ol style="list-style-type: none"> Either fail to fuse or Fuse only in vagina Not seen : Transverse lie 	<p>uterus didelphys</p>	<ul style="list-style-type: none"> FT : 2 uterus : 2 Cervix : 2 (Distinguishing feature) vagina : 2 (Or 1 if only vagina is fused) On HSG : 2 Leech Wilkinsons's cannulas

----- Active space -----

	HSG Image	Comment
<p>Class IV : Bicornuate uterus</p> <p>Both MD fuse in vagina and cervix but not in uterus</p>	 <p>HSG of bicornuate uterus</p> <ul style="list-style-type: none"> • Angle between uterine horns : Obtuse • Distance between horns ≥ 4cm 	<ul style="list-style-type: none"> • FT : 2 • Uterus : 2 • Cervix : 1 • Vagina : 1 • Distinguishing feature : Fundus of uterus is divided (Separate vs. bicornuate) <p>Note : On HSG \rightarrow Fundus of uterus cannot be seen (Cannot differentiate from septate uterus)</p> 
<p>Class V : Septate uterus</p> <ul style="list-style-type: none"> • Both MD fuse septa is formed • But septa fails to resolve in uterus <p>Note : Fundus of uterus fused in septate uterus.</p>	 <p>Septate uterus</p> <ul style="list-style-type: none"> • Angle between uterine horns : Acute • Distance between horns < 4 cm 	<ul style="list-style-type: none"> • From outside : uterus appears (N) ; • From inside : Septa (+) • Structures present : <ul style="list-style-type: none"> - FT : 2 - uterus : 2 - Cervix : 1 - Vagina : 1 • To differentiate b/w septate and bicornuate uterus : Fundus of uterus (Undivided) 
<p>Class VI : Arcuate uterus</p> <ul style="list-style-type: none"> • Everything is normal • MD fuse septa forms and septa resolves. <p>Problem : Fundus of uterus is flat.</p>	 <p>Arcuate uterus</p>	<p>Best reproductive outcome</p> 
<p>Class VII : In utero exposure to Diethylstilbestrol (DES)</p> <ul style="list-style-type: none"> • Synthetic estrogen given to pregnant women. • Teratogenic • Now discontinued. 	-	<ul style="list-style-type: none"> • m/c malignancy a/w DES : Clear cell cancer of cervix and vagina • m/c uterine malformation a/w DES : Hypoplastic uterus • most specific uterine malformation a/w DES : T shaped uterus • DES exposure does not lead to renal anomalies in female fetuses

----- Active space ----- HSG based diagnosis :



Important PYQs

00:15:09

----- Active space -----

Important PYQs :

3. m/c mullerian anomaly : **Septate** > bicornuate uterus
4. m/c clinical features : **Recurrent abortion** (m/c uterine malformation a/w 2nd trimester abortions > 1st trimester : Septate uterus)
5. Infertility a/w : **Septate uterus**
6. Best outcome : **Arcuate uterus** > didelphys uterus
7. Worst reproductive outcome : **Septate uterus**
8. Uncommon in Didelphys : **Transverse lie**
9. Maximum associated with renal anomalies : **Unicornuate uterus** > mullerian agenesis
10. Surgery for septate uterus : **Hysteroscopic resection of septum**
11. Indications for surgery : **Recurrent abortion**
12. Outdated surgery : **Jones metroplasty**
13. Outdated surgery for bicornuate uterus : **Strausman metroplasty**
14. Surgery for didelphys uterus and bicornuate uterus : **Unification surgery**

MALPRESENTATIONS SEEN IN CONGENITAL MALFORMATION

Transverse lie :

mnemonic : **SSB**

- **Septate uterus**
- **Sub-septate uterus**
- **Bicornuate uterus**

Breech :

- **uterus didelphys**

Investigations for mullerian malformation :

1st Investigation → **Recurrent abortion : TVS**→ **Infertility : HSG**IOC : **3D ultrasound**Gold standard investigation : **MRI**Last Resort : **Laparoscopy + hysteroscopy**

Gynaecological complication with mullerian malformation :

- **Infertility (Rare).**
- **Outflow tract obstruction** → **Hematometra.**
- **Endometriosis** : If pubertal ♀ has endometriosis → **Rule out mullerian malformation.**
- **Dysmenorrhea.**

Obstetric complication with mullerian malformation :

- **Recurrent pregnancy loss (RPL).**
- **Preterm labor.**
- **malpresentation.**

m/c complication overall : **RPL.**

Specific complain in unicornuate uterus :

- **unilateral dysmenorrhea.**
- **Ectopic pregnancy.**
- **Ectopic ovary.**
- **u/L renal anomalies.**

----- Active space -----

Prolapse

00:20:41

Supports of uterus :

- Ligaments which support uterus :
 - Cardinal/mackenrodt's/transverse cervical ligament
 - Pubocervical ligament
 - uterosacral ligament
- Together k/a : **Triradiate ligament**
- muscles which support uterus :

mnemonic : **BLSD**

 - Bulbospongiosis
 - Levator ani (most important support)
 - Superficial } Transverse perineii
 - Deep }
- mechanical support : (Prevents prolapse)

Angle of anteversion : 90° (B/w cervix and vagina)

Angle of ante flexion : 130° (B/w uterus and cervix)
- On P/V examination :
 - In anteverted uterus : Fundus > anterior lip of cervix
 - Retroverted uterus : Posterior lip of Cx felt first

PYQ'S (??) :

- First step for prolapse : Retroversion of uterus (Can be manually corrected)
- Fixed retroverted uterus seen in : Endometriosis
- Ligament which keeps uterus in anteverted position : **Round ligament (RL)** > uterosacral (US) ligament
- Ligament which prevents retro version : **US ligament** > RL
- Ligament which is secondary support : **RL**
- Ligament which doesn't support uterus : Broad ligament
- Which part of levator ani if damaged has maximum chances of causing prolapse : **Puborectalis** > pubococcygeus

PROLAPSE**Decubitus Ulcer :**

Cause : Venous congestion
 Management : **Packing** with Acriflavine (Antiseptic) and glycerine.

Risk Factors :

- Elderly menopausal females
- Birth trauma**
- Multi gravida
- Instrumental delivery

Classification of prolapse :

POP-Q Classification
 Reference point : **Hymen**

Best method to Prevent Prolapse :

Keigel's exercise/
 perineal exercise

Vaginal De Lancey Support :

LEVEL 1 (Supports upper 1/3rd of vagina) :

Supporting structures :

- uterosacral ligament
- Cardinal ligament

Defect leads to :

- Apical prolapse
- Vault prolapse
- Elongation of cervix : **Supravaginal part**
- Enterocoele

LEVEL 2 (middle 1/3rd of vagina) :

Supporting structures :

- Paravaginal tissue

Defect leads to :

- Rectocoele
- Cystocoele

LEVEL 3 (Supports lower 1/3rd of vagina) :

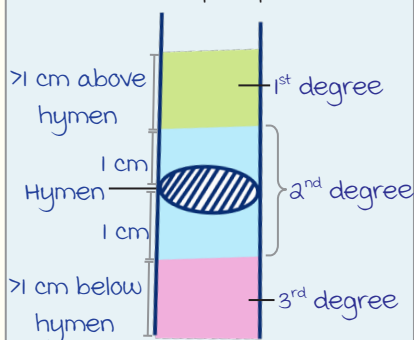
Supporting structures :

- Perineal body and muscles attached to it.

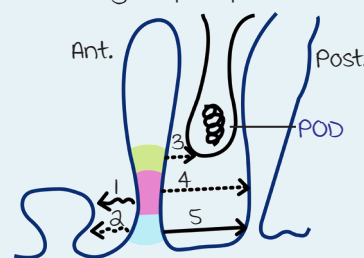
Defect leads to :

- urethrocele
- Laxed perineum

Note : Congenital Cx elongation → **Portio vaginalis** part of Cx elongated

uterine prolapse :

Procidentia : whole Cx & uterus lies outside vagina

vaginal prolapse :

- 1 : Cystocoele
 2 : urethrocele
 3 : Enterocoele
 4 : Recto cele
 5 : Laxed perineum

----- Active space -----

VAGINAL PROLAPSE

Anterior vaginal wall :

- Upper 2/3rd = **Cystocele**
 - management : Anterior colporrhaphy.
- Lower 1/3rd = **urethrocele**.
 - management : Anterior colporrhaphy.

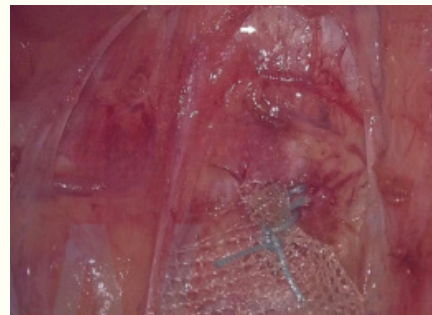
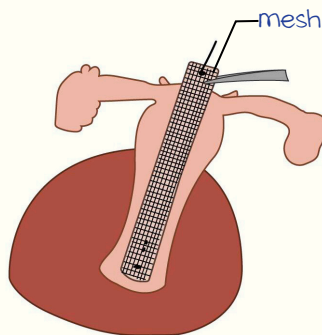
Posterior vaginal wall :

- Upper 1/3rd = **enterocele**.
 - management : McCall culdoplasty.
- middle 1/3rd = **Rectocele**.
- Lower 1/3rd = **Laxed perineum**.
 - management : Posterior colpoperineorrhaphy (Same mx for rectocele).

Note : management for vaginal prolapse → **Same for all age groups and parity.**

Outdated surgery for enterocele :

- moscowitz repair.
- Halban repair.



Sacral colpopexy

VAULT PROLAPSE

Prolapse of vaginal stump after hysterectomy.

To prevent vault prolapse after hysterectomy : **uterosacral suspension** is done prophylactically.

management of vault Prolapse :

vaginal surgery :

1. uterosacral suspension (Both **prophylactic and therapeutic**).
2. Sacrospinous fixation.
3. Le Fort colpocleisis.

Abdominal surgery :

- Sacral colpopexy (Difficult to perform but gives best results) → **mesh attached** : One side on **sacral promontory** and other side to **vault** (vaginal stump).
- m/c done is : **uterosacral suspension**.
- Remember : **Burch colposuspension** is a surgery for SUI and not vault prolapse.

----- Active space -----

MANAGEMENT OF UTERINE PROLAPSE

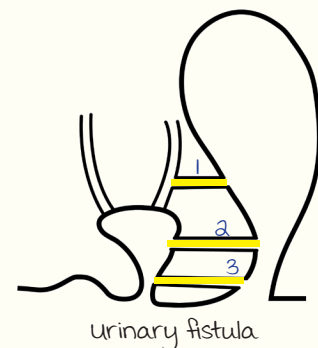
- Depends on age and parity of female.
- Done for second degree and third degree prolapse.

Condition	management
1. uterocervical prolapse in reproductive age females who need future childbearing	<ul style="list-style-type: none"> • SLING surgery/colpopexy • Best result : Shirodkar sling surgery (Psoas muscle hook used to prevent complications on the left side) • Least complication : Purandare sling surgery
2. Prolapse in reproductive age female who do not need future childbearing	In ↑ utero-cervical length : FOTHERGILL surgery/manchester surgery : Best Sx (2 steps : 1 st = Cervical amputation, 2 nd = Plication of cardinal ligament) → Leads to → Recurrent abortions (D/t incompetent OS) of 2 nd trimester, Cx stenosis, Cx dystocia
3. Prolapse in menopausal female/ female who has completed childbearing	Vaginal hysterectomy (If there is third degree uterine prolapse + cystocele + rectocele : vaginal hysterectomy + anterior colporrhaphy and posterior colpoperineorrhaphy = Together called WARD MAYO hysterectomy)
4. Prolapse in ♀ = 60-65 years with some C/I to surgery (Diabetes/↑BP)	Le Forts colpocleisis
5. Prolapse in female ≥65 years with comorbidities or prolapse in pregnant/postpartum female	Ring pessary (Should be changed every 3 months)

Urinary Fistula

00:36:41

Type of fistula	Complaint
1. Ureterovaginal fistula	<ul style="list-style-type: none"> • Continuous urinary dribbling from vagina ⊕ • Normal bladder emptying ⊕
2. Vesicovaginal fistula	<ul style="list-style-type: none"> • Continuous urinary dribbling from vagina ⊕ • Normal bladder emptying ⊖
3. Urethrovaginal fistula	<ul style="list-style-type: none"> • Continuous dribbling of urine from vagina ⊖ • During micturition → urine comes out from vagina + urethra



ureteric injury :

- most common site of ureteric injury during hysterectomies :
water under bridge (2 cm lateral to internal os) > **pelvic brim** (2nd m/c).
- maximum risk of ureteric injury : **Wertheim's hysterectomy**.
- m/c ureteric injury seen with : **TAH** (Simple hysterectomy).

Diagnosis :

----- Active space -----

methylene blue 3 swab test (IOC) :

Observation	Fistula
Uppermost cotton swab : Wet with urine + not blue	Ureterovaginal fistula
Middle + lowermost cotton swab : Wet with urine + blue	Vesicovaginal fistula
Only lowermost cotton swab : Wet with urine + blue	Urethrovaginal fistula

Vesicovaginal Fistula :

Feature	Time of repair	Post-op instructions
<ul style="list-style-type: none"> m/c urinary fistula m/c cause : <ul style="list-style-type: none"> Developed countries : Hysterectomy Developing Countries : Obstructed labour 	<ul style="list-style-type: none"> Diagnosed at the time of Sx/within 24 hours of symptoms : Immediate repair 24 hours of symptoms/post-obstructed labour : Repair after 6 weeks 	<ul style="list-style-type: none"> Continuous bladder drainage 1/2 weeks Antibiotics 1/2 weeks No P/S, P/V exam, intercourse 1/23-6 months No pregnancy 1/21 year
IOC : methylene blue 3 swab test Gold standard : Cystoscopy	Technique : Chassar moir technique, Latzko technique	

Named structures/Criteria/Scores/Sx

00:42:46

Name	Condition	Seen in
1. PEG cells	Normal cells	Fallopian tube
2. Superficial cells	Types of cells seen in vagina	Seen when : Estrogen predominant → 1 st 1/2 of menstrual cycle
3. Intermediate cells		Seen when progesterone predominant → 2 nd 1/2 of menstrual cycle
4. Parabasal cells		Seen when : No hormonal predominance → After menopause/before puberty/in puerperium
5. maturation index	-	Out of 100 cells of vagina No. of = Parabasal/intermediate/superficial a/b/c <ul style="list-style-type: none"> In proliferative phase : 0/40/60 or 0/30/70 In secretory phase : 0/60/40 or 0/70/30 At menopause : 100/0/0
6. Clue cells	Vaginal epithelial cells to which bacteria are adhered	Seen in bacterial vaginosis

----- Active space -----

Name	Condition	Seen in
7. Tanner	Staging	Breast/pubis hair : Total 5 stages
8. Gainesville		Staging of PID
9. Straw		For women's life
10. Ferriman Gallwey	Scores	Hirsutism → No. of sites = 9 Significance each site : Score 0-4
11. Prader		For virilisation
12. Nugent		For bacterial vaginosis (BV) Significance score 7-10 : BV ⊕
13. Boer meisel		For chances of conception in patients of PID (Type of organism not included in score)
14. Rotterdam	Criteria	For diagnosis of PCOS
15. Amsels		For diagnosis of Bacterial vaginosis Out of 4, any 3 should be seen 1. Greyish white discharge 2. pH ≥4.5 3. Clue cells ≥20% 4. Whiff test ⊕
16. Splash dysuria	-	Candidiasis
17. Feeder vessels	Sign seen on doppler	Endometrial polyp
18. Mushroom cap	MRI appearance	Deep rectosigmoid endometriosis
19. Venetian blind	USG appearance	Asherman's syndrome
20. HONAN	Criteria for	Bartholin gland carcinoma
21. HPE findings :		
• Schiller-Duval bodies	-	Yolk sac tumor
• Call exner bodies	-	Granulosa cell tumors
• Psammoma body	-	Epithelial ovarian tumors
• Walthard cell nest	-	Brenner's tumor
• Signet ring cell	-	Krukenberg tumor

Named Surgeries in Gynecology :

----- Active space -----

Condition	Surgery
Vault Prolapse	<ol style="list-style-type: none"> 1. Sacral colpopexy 2. uterosacral suspension 3. Sacrospinous fixation
SUI ↓ Involuntary passage of urine on increasing intraabdominal pressure like coughing, sneezing	<ul style="list-style-type: none"> • Gold Standard : Burch colposuspension <ul style="list-style-type: none"> - Abdominal surgery - Proximal urethra attached to Coopers ligament/ ileopectineal ligament • m/c done : TOT > TVT
VVF	Chassar moir technique Latzko technique
uterine inversion	Haultain Sx Halban Sx
vaginoplasty	<ul style="list-style-type: none"> • mcIndoe vaginoplasty • Lap. Veicheitti technique
Bicornuate uterus outdated Sx	Straussman metroplasty
Septate uterus outdated Sx	Jones metroplasty

----- Active space -----

Contraception

00:43:34

mechanism of Action of Some Important Contraceptives :

Contraceptive	main mechanism	Others
1. OCP's (E+P)	Anovulation (\downarrow FSH \ggg LH)	<ul style="list-style-type: none"> • Thicker cervical mucus • Thinning of endometrium
2. POP	make cervical mucus thick	Progesterone in small quantities : Positive feedback on LH, FSH
3. Prog. implant/prog. injection/cerazette (POP in India)	Anovulation	make cervical mucus thick
4. Cu IUCD	Prevents fertilization (Copper released induces an inflammatory reaction)	Inhibits implantation
5. MIRENA	Prevents implantation (makes endometrium thin)	-
6. Centchroman	makes endometrium out of phase and inhibits implantation	-

CONTRACEPTION**Important Q's**

LARC method (Long acting reversible contraceptives) :

1. Implants
2. IUCD
3. Injections

Permanent methods :

- Female
 1. Tubal ligation (minilaparotomy, laparoscopy)
 2. Hysteroscopic method : Essure
- male : Vasectomy

Important PYQ's (SP)

Natural methods include	<ul style="list-style-type: none"> • Rhythm method (Calendar method) • Cyclobeads/TIRUMALA (used by uneducated females) • Cervical mucus \rightarrow Billing method • Basal body temperature
Barrier methods include	<ul style="list-style-type: none"> • male condom (Included in NFP) : Single ring; one time use only • Female condom (FC-2 distributed by NACO to ♀ sex workers) : 2 rings; generally one time use only (max twice) • Diaphragm (Can be used till 1 year by washing and drying) • Today sponge (1 g nonoxynol 9) \rightarrow Can be used multiple times for 24 hours.

OCP's

00:48:58

----- Active space -----

OCP's Classification :
Dosing of Ethinyl estradiol (EE) :

- High dose :
EE ≥ 50 mcg.
- Low dose :
EE < 50 mcg (30-35 mcg).
- Very low dose :
EE < 20 mcg
- minimum effective dose :
EE = 10 mcg.

Noncontraceptive Uses of OCP's :

1. Irregular cycles : OCP is DOC
2. To decrease blood loss in fibroids, adenomyosis, AUB
3. DOC for primary dysmenorrhea and endometriosis (minimal to mild)
4. DOC for hirsutism, acne and hyperandrogenism.
5. To manage premenstrual syndrome (DOC for PMS : Fluoxetine → SSRI)
6. Progesterone in OCP's makes cervical mucus thick → Decreases chances of PID, STD and ectopic pregnancy.

m/c PID with OCP use : Chlamydia
 m/c vaginitis with OCP use : Candidiasis

OCP'S

OCP's and Cancers
Increases
1. Hepatic adenomas
2. Breast cancer in perimenopausal females
3. Cancer cervix (Reversible risk)
Decreases
1. Endometrial cancer → D/t endometrial thinning & anovulation
2. Ovarian cancer → D/t anovulation
3. Ovarian cyst
4. Benign breast disease
5. Colorectal cancer
No effect
Liver cancer

Table 33 : Absolute Contraindication of OCP's	
WHO Category 4:	
Mnemonic	Banks have various schemes to provide home loans during may
Banks	Known/suspected cases of breast cancer
Have	uncontrolled hypertension : Severe (≥160/110) (medically controlled hypertension, in a female who is nonsmoker, of any age : Not a C/I for OCP's)
Various	undiagnosed vaginal bleeding
Schemes	Smoker ≥35 years of age
To	Known or suspected case of thromboembolism or family history of idiopathic thromboembolism in parent or sibling or h/o CVA/MI, or conditions predisposing to it (Risk factor for thromboembolism, e.g., malignancy, lupus anticoagulant present, prolonged immobility due to trauma or surgery → Absolute contraindication)
Provide	Pregnancy or h/o peripartum cardiomyopathy
Home	Severe hypercholesteremia, hypertriglyceridemia
Loans	Presently impaired liver function/liver cancer/acute or chronic cholestatic liver disease
During	Diabetes with vasculopathy
may	migrane with Aura
OCP	Also C/I in breast feeding and post partum females (<21 days)

----- Active space -----

Method of OCP Consumption :

OCP pack : 21 hormonal pills (In mala-N and mala-D → Additional 7 ferrous fumarate pills).

Dosage :

- 1 pill/day.
- Start between DI-D5 of menstrual cycle.
- maintain high levels of estrogen & progesterone for 21 days.
- Stoppage → Fall in E + P levels → Induces menses → Day of menses is the new DI for the next cycle.

Missed Pills (GOI Guidelines)

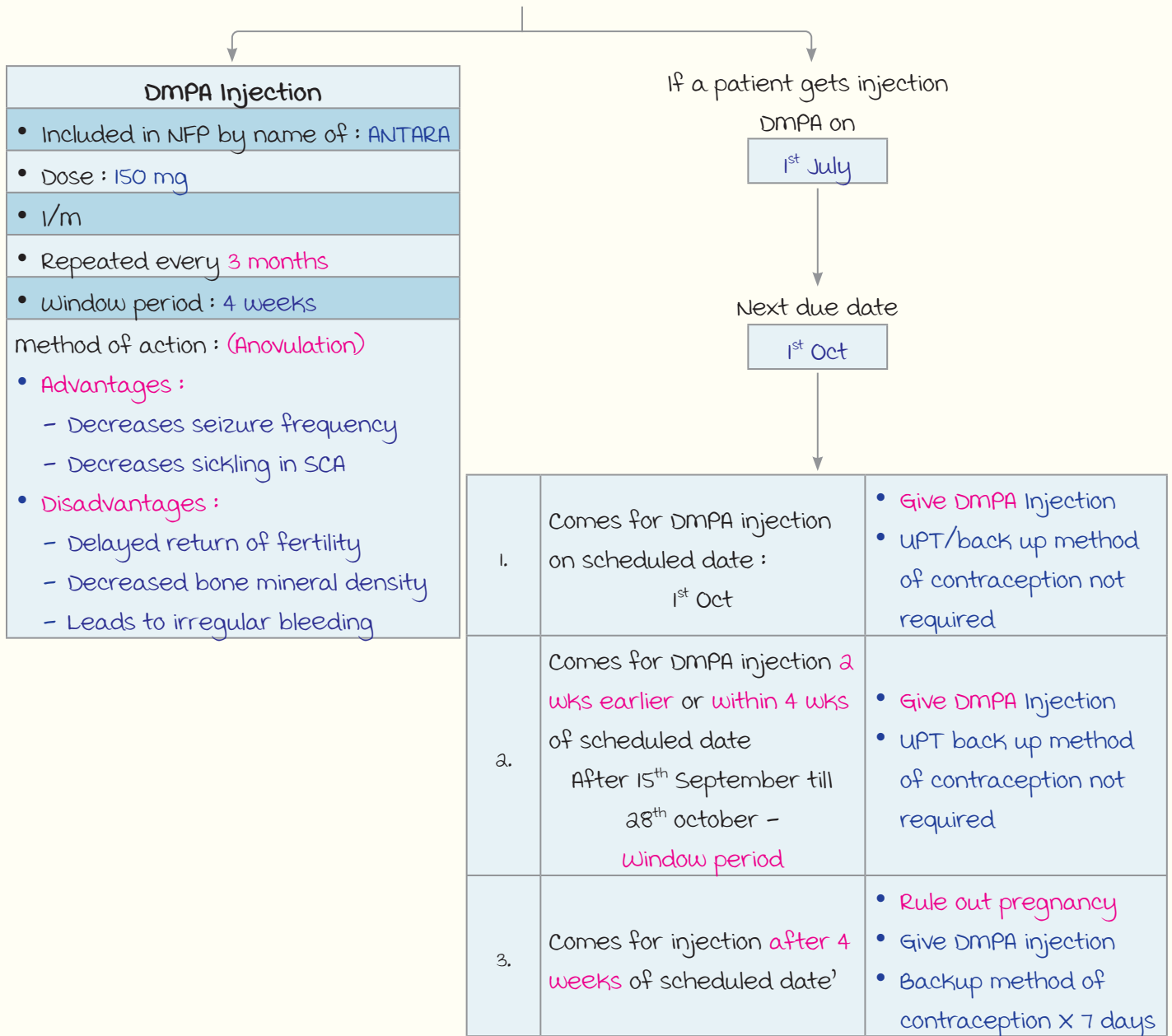
00:55:46

Pills missed		Next step
missed 1-2 pills		<ul style="list-style-type: none"> • 1 pill to be taken ASAP • Normal schedule to be continued • No back up contraceptives required
missed ≥3 pills	1 st /2 nd week	<ul style="list-style-type: none"> • 1 pill to be taken immediately • Complete pack as per schedule • Back up contraception x 7 days • If h/o intercourse in previous 72 hours : Emergency contraception
	3 rd week	<p>In addition to above points :</p> <p>After completing pack as per schedule → Start a new pack immediately (Don't wait for menses; Skip non-hormonal pills)</p>

Injection DMPA

00:58:55

----- Active space -----



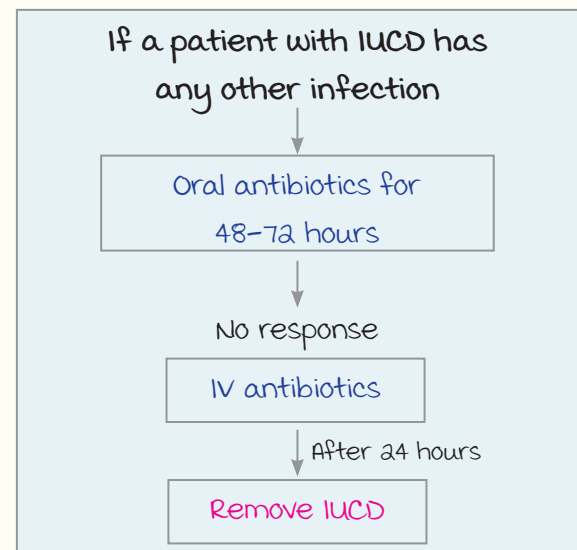
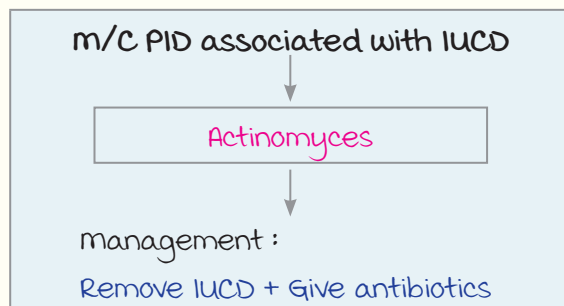
----- Active space -----

Important Points on IUCD

01:02:27

Important Points on IUCD :

CuT 380	Mirena
• Acts by preventing fertilization	• Acts by preventing implantation
• Releases 50 mcg of Cu per day	• Releases 20 mcg of LNG per day
• m/c side effect is bleeding	• It helps in reducing bleeding so in patients of AUB, it is used
• Increased risk of infection (PID) at time of insertion	• makes cervical mucus thick and decreases PID
• Causes ectopic pregnancy in case of failure	• Chances of ectopic pregnancy more if failure occurs
• Can be used as emergency contraceptive	• Cannot be used as an emergency contraceptive

**Contraindications of IUCD :**

For both CuT & mirena

1. Undiagnosed vaginal bleeding (Ca cervix, Ca endometrium)
2. Distorted uterine cavity (Fibroid)
3. Active PID
4. Suspected pregnancy

Only CuT

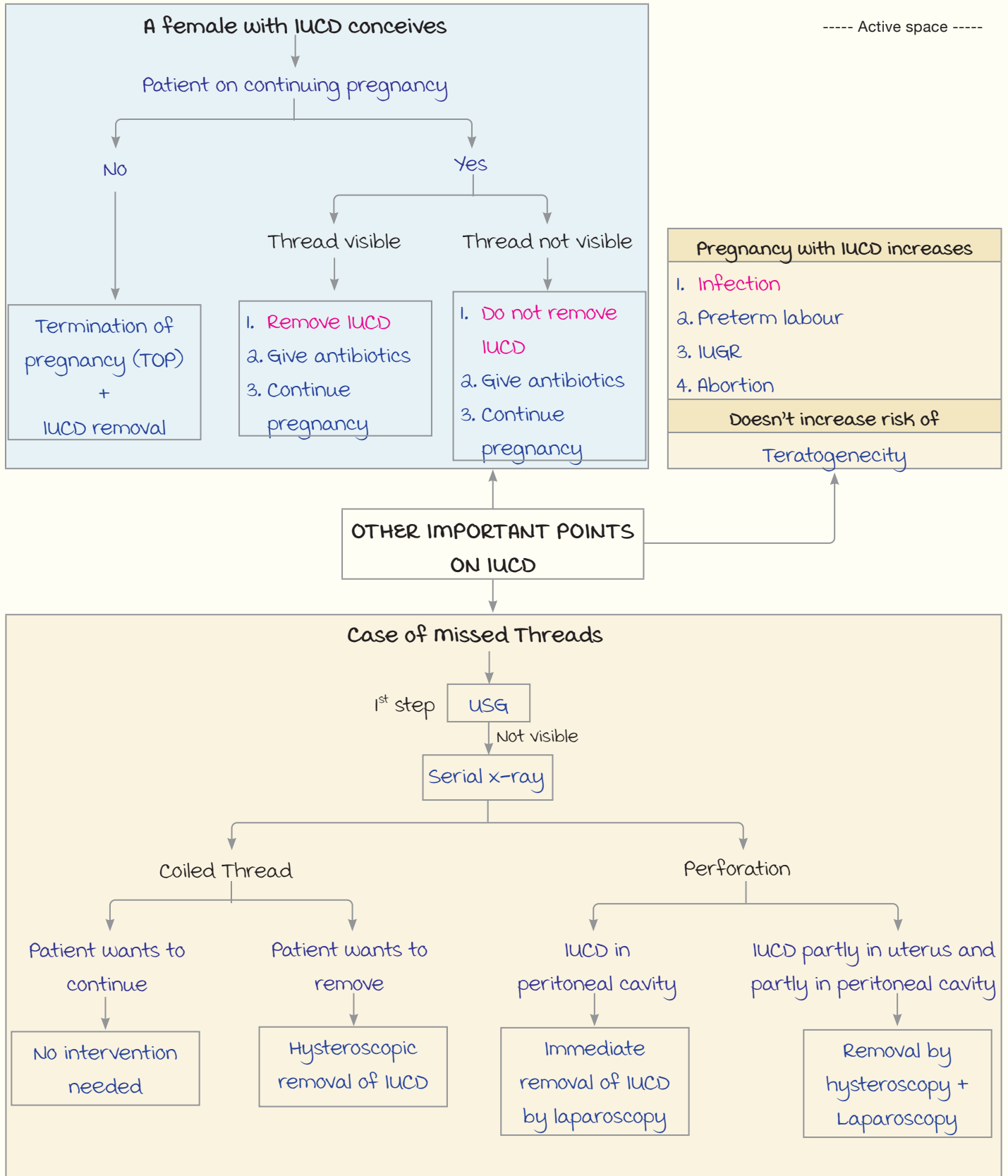
Wilson's disease

Only mirena

- Previous h/o **breast cancer**
- Active **liver disease**

Not a C/I

1. Previous h/o ectopic pregnancy
2. Previous h/o PID



----- Active space -----

Emergency Contraception

01:08:41

Common emergency contraceptives : **LOCUM**.

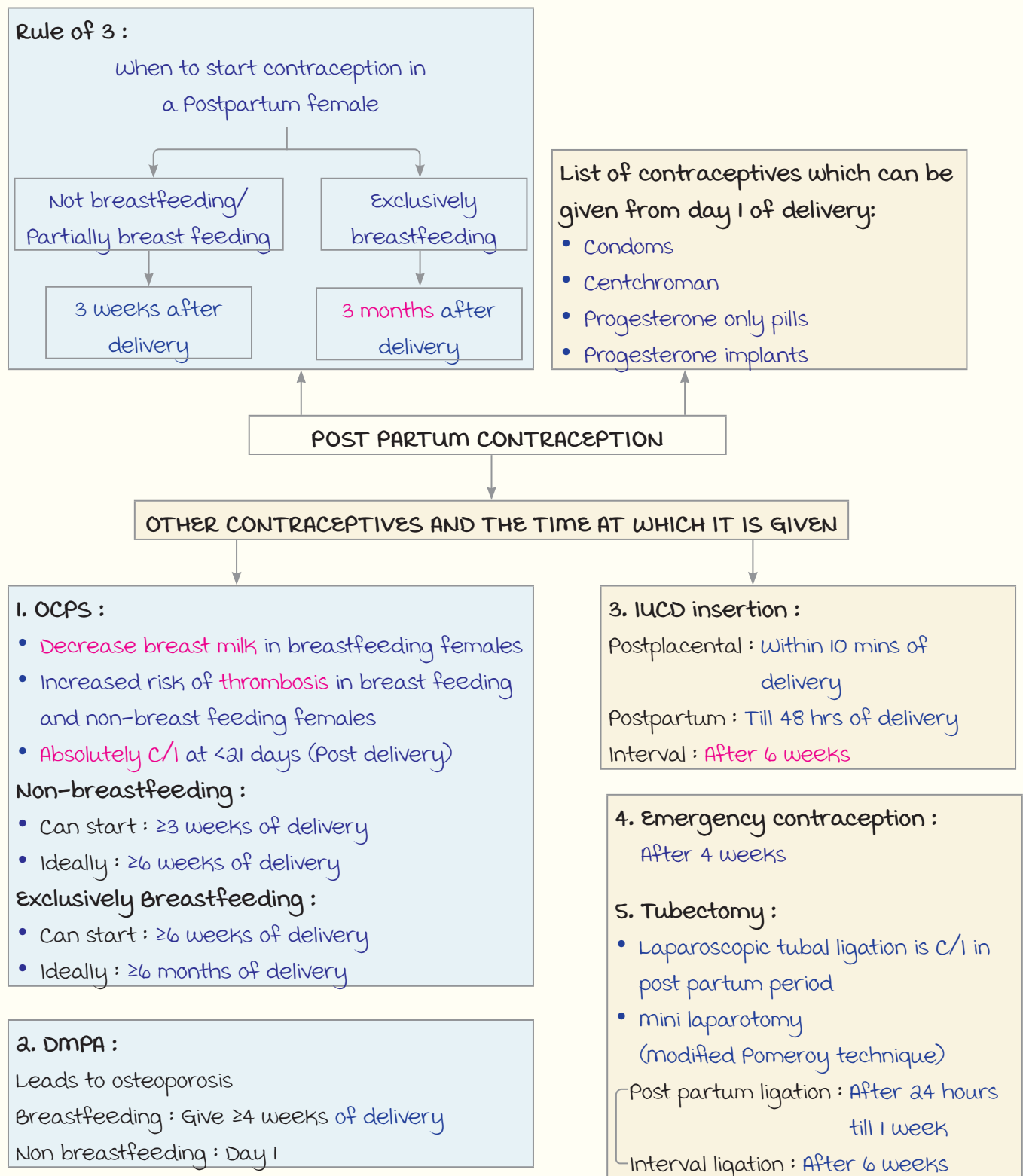
Drug	Dose	Comment
Levonorgestrel (m/c used)	1.5 mg single dose (or) 0.75 mg $\xrightarrow{12 \text{ hrs}}$ 0.75 mg	<ul style="list-style-type: none"> Included in NFP Plan B of emergency contraception
OCP : Ethinyl estradiol (50 mg) & Norgestrel (0.25 mg)	2 tablets $\xrightarrow{12 \text{ hrs}}$ 2 tablets (Stat) (Stat)	Yuzpee method
Copper IUCD	Within 5 days of unprotected intercourse	<ul style="list-style-type: none"> most effective method Not suitable for rape victims
Centchroman	2 tablets (60 mg each) $\xrightarrow{12 \text{ hrs}}$ 2 tablets	-
ulipristal acetate	30 mg single dose	most effective hormonal emergency contraception
mifepristone	10-50 mg single dose	-

- Drugs **not used** as emergency contraceptives : POP, MIRENA & misoprost.
- m/c moA : **Delayed ovulation**.
- moA of IUCD : Inhibits fertilization and implantation.
- Order of effectiveness : **Cu T** (most effective) > ulipristal > mifepristone > LNG.
- most effective hormonal EC : **ulipristal**.
- most effective when given <72 hours of unprotected sexual intercourse (Can be given up to **5 days** after).
- If patient vomits after taking EC : **Repeat EC**.

Postpartum Contraception

01:11:57

----- Active space -----



----- Active space -----

Hysteroscopy

01:15:52

Position of patient : **Lithotomy**

Hysteroscopy → Diagnostic : **Paracervical block.**
 → Therapeutic : **GA/regional anaesthesia.**

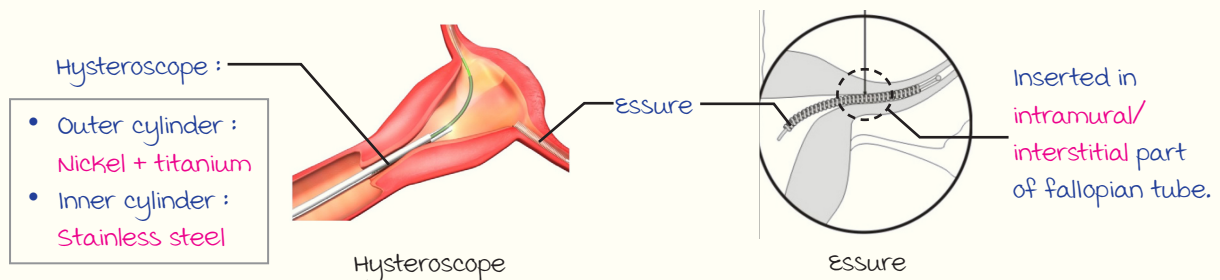
Distention media in hysteroscopy :

Electrolyte rich media	Electrolyte deficient media
Can be used only with bipolar instruments	Can be used with bipolar & unipolar instruments
Can lead to uterine perforation	
	<ul style="list-style-type: none"> • ↑ Chances of water intoxication : c/o nausea, vomiting, headache • All electrolyte deficient media except mannitol are hyposmolar → Hyponatremia (Delirium, confusion)
Stop procedure if fluid deficit ≥ 2.5 Litre	Stop procedure if fluid deficit ≥ 1 Litre
Eg : Ringer's lactate, normal saline	Eg : mannitol, glycine

Fluid deficit = Amount of fluid given - Amount of fluid comes out

uses of hysteroscopy :

- Asherman's syndrome.
- Septate uterus.
- Endometrial polypectomy.
- Type 0, I fibroid.
- **Hysteroscopic tubal ligation using Essure** (Permanent sterilisation).

Hysteroscopic Tubal Ligation by Essure :

mechanism of action :

Irritates fallopian tube → Tissue reaction → **Inflammation** & **blockage** of tube.

Contraceptive efficacy :

- Contraception : **Not immediately effective.**
- Back up contraception necessary for **3 months** post-procedure.
- After 3 months → Do HSG → Confirm B/L blockage → Stop back up contraceptives.
- Success rate : **99%**.

OBSTETRICS : PART 1

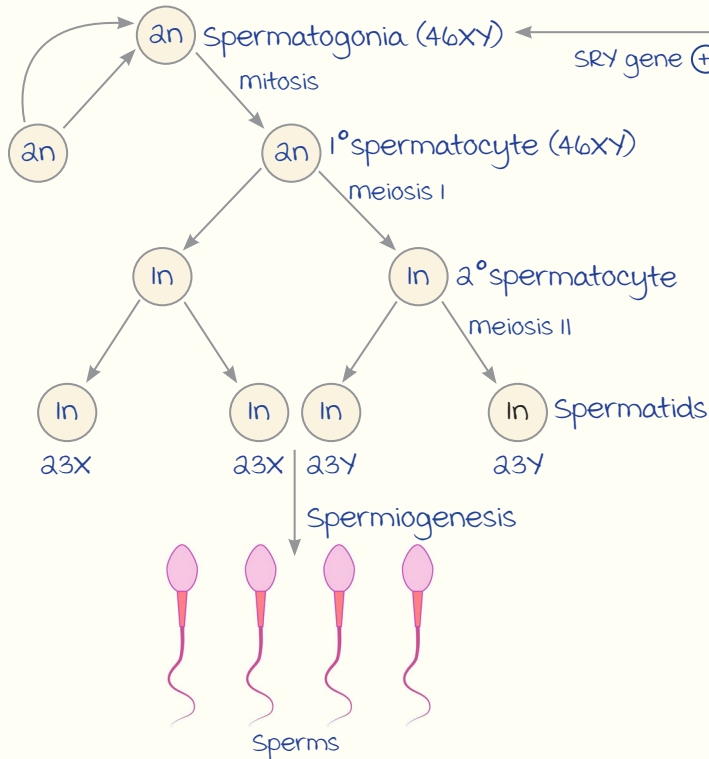
----- Active space -----

Basics of Fertilisation

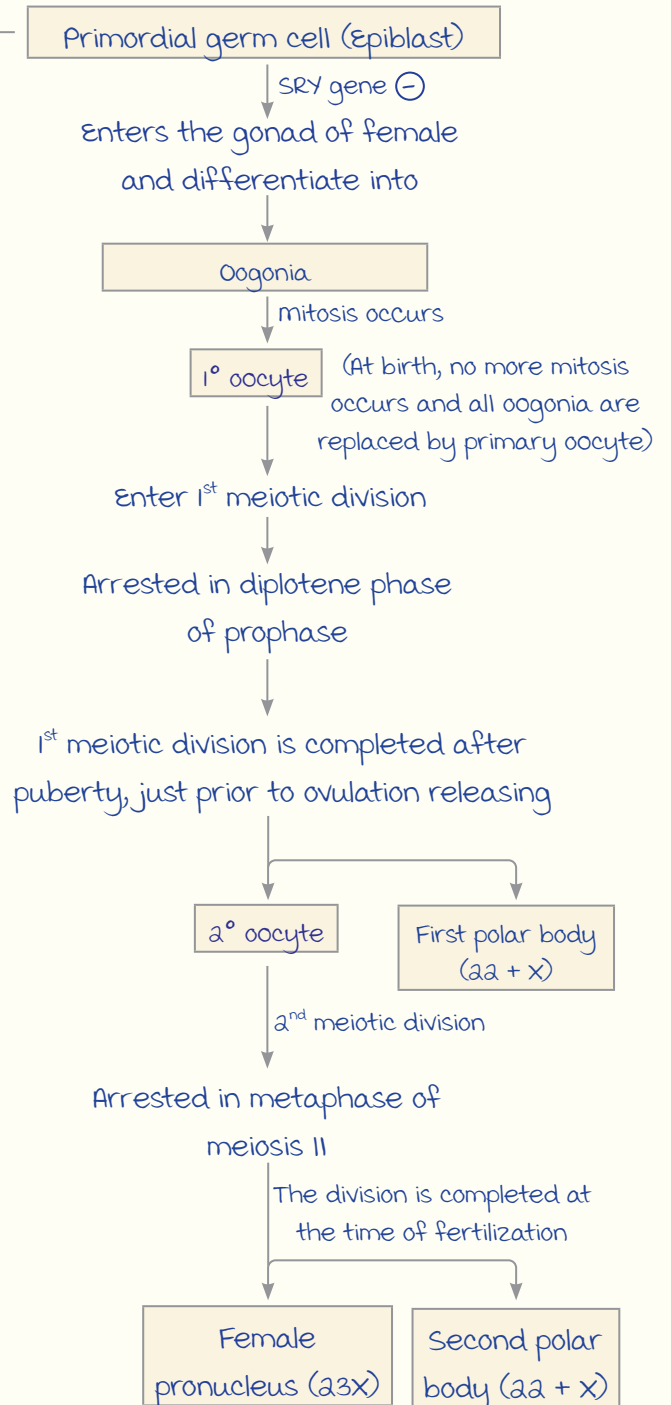
00:00:27

SPERMATOGENESIS AND OOGENESIS

Spermatogenesis



Oogenesis



Important Points :

- Begins at : Puberty.
- Spermatogenesis takes place in : Seminiferous tubules.
- Time taken for spermatogenesis : 72 days (70-74)
- Spermiogenesis : Transformation of spermatids to sperm. There is no mitosis or meiosis.
- Fertilizable life span : 48-72 hours.
- Sperms attain
 - motility : Distal part of epididymis.
 - maturity : Proximal part of epididymis.
- Time for spermiogenesis : 10-14 days.
- Time for capacitation : 6-8 hours.
- Site for capacitation : Female Reproductive tract; Begins in cervix and completed in fallopian tube.

----- Active space ----- Note :

- Size of follicle just before ovulation : 18-20 mm.
- Size of ovum/female pronucleus : 120 microns.
- Fertilisable span of ova : 12-24 hours.

Events Before Fertilisation :

Capacitation (Ability of sperms to fertilise ova)

↓
Acrosomal reaction : Head of sperm enters cortex of 2° oocyte d/t action of **hyaluronidase**

↓ Released by acrosomal cap

Cortical reaction : Release of enzymes by cortex of 2° oocyte

↓

Zona reaction : Zona pellucida made impermeable to other sperms.

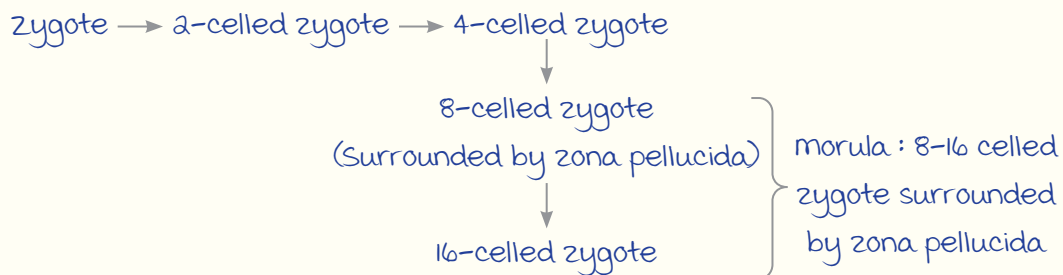
Zona pellucida :

- Acellular layer.
- **ZP₃** : main receptor for sperm.
- Prevents polyspermy.

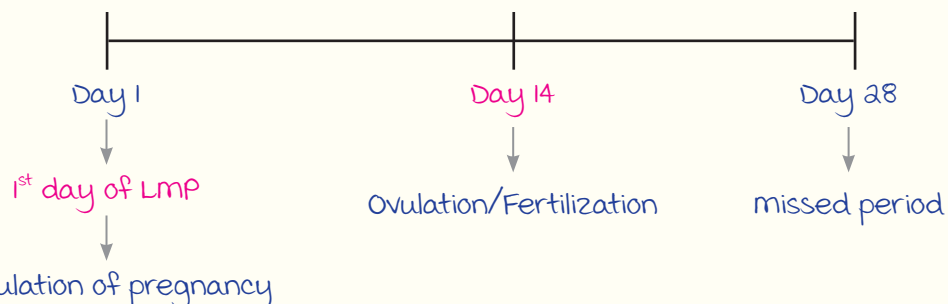
FERTILIZATION

Site : **Ampulla** of fallopian tube.

Division :



Timelines related to pregnancy :



Day 3-4 : morula enters uterine cavity. (Day 18 of cycle).

Day 5 : Zona pellucida lost.

Day 6 : Implantation of blastocyst. (Day 20 of cycle).

Implantation :

- Type : Interstitial.
- Site : upper posterior wall of uterus.
- Implantation window : Day 20-24 of cycle.
- Completed on : Day 10-11.
- Hartmann's/Placental sign : Bleeding at the time of implantation.

----- Active space -----

IMPORTANT TERMINOLOGIES

Total duration of pregnancy : 9 months + 7 days/ 40 weeks/ 280 days.

Parameter	Duration
Preterm pregnancy	<37 weeks
Term	37 to 41 weeks + 6 days
Early term	37 to 38 weeks + 6 days
Full term	39 to 40 weeks + 6 days
Late term	41 weeks to 41 weeks 6 days
Post term	≥42 weeks

Pregnancy Dating & Obstetrical Score

00:13:55

CALCULATION OF ESTIMATED DAY OF DELIVERY (EDD)

1. Regular 28-day cycle :

- EDD by Naegele's formula : 1st day of LMP + 7 days + 9 months.
- LMP in February : 9 months added first f/b + 7 days.

2. Cycle length >28 days :

- Calculate approximate EDD using Naegele's formula.
- Approximate EDD - 28 = 'x'
- Add the difference 'x' to the approximate EDD.

3. Cycle length <28 days :

- Calculate approximate EDD using Naegele's formula.
- 28 - Approximate EDD = 'x'
- Subtract the difference 'x' from the approximate EDD.

4. Irregular cycle/Female on OCP's /Conceived during lactation/Unsure about LMP :

Best method : USG → Crown-Rump Length (CRL).

5. IVF cycles :

- Fresh cycle : Date of oocyte retrieval + 266 days.
- Frozen cycle :
 - D3 transfer : Date of D3 transfer + 263 days.
 - D5 transfer : Date of D5 transfer + 261 days.

----- Active space -----

GRAVIDA & PARITY

Gravida : Total number of times a female has conceived.
(Past + present pregnancies.)

Parity : Number of pregnancies that have crossed period of viability i.e. 28 weeks.
(Present pregnancy **not included**.)

- multipara : ≥ 2 previous births.
- Grand multipara : ≥ 5 previous births.

Note :

Twins/Triplets : Counted as 1 in gravida and parity.

Representation :

1. $G_a P_b$:

a. Gravida

b. Parity

2. $G_a P_{b+c}$:

a. Gravida

b. Parity

c. Number of abortions \rightarrow Pregnancy loss at ≤ 20 weeks which includes :

- Abortion
- mTP
- Ectopic pregnancies
- molar pregnancies

GTPAL : $G_x P_{T+P+A+L}$

x : Gravida

T : Number of **term** deliveries

P : Number of **preterm** deliveries } Twins/Triplets = 1

A : Number of **abortions**

L : Number of **living** children at present (Twins = 2, triplets = 3)

Signs Of Pregnancy

00:21:40

Signs Of Early Pregnancy :

Signs	Description	Seen at
Goodell sign (1 st sign)	Softening of cervix	6 weeks
Chadwick/Jacquemier	Bluish discoloration of cervix/vagina	8 weeks
Osiander sign	Lateral vaginal wall pulsation	
Palmer's sign	Rhythmic uterine contractions	
Piskacek sign	Unequal growth of uterus	
Hegar sign	<ul style="list-style-type: none"> • Softening of isthmus. • Bimanual palpation : Approximation of vaginal & abdominal fingers. 	6-10 weeks

Height of uterus :

----- Active space -----

Period	Level of uterus
12 weeks	Pubic symphysis
22 weeks	umbilicus
Immediately after delivery	Just below umbilicus (~20 weeks of pregnancy)
Day 1 after delivery	No change
Day 2 onwards	uterine height ↓ by 1 finger breadth per day. (1 finger breadth below umbilicus on Day 2)

Quickening : Perception of first fetal movement by the mother.

- Primigravida : 18-20 weeks.
- multigravida : 16-18 weeks.

Lightening/welcome sign :

36 weeks : Respiratory discomfort as uterus reaches the level of xiphisternum.

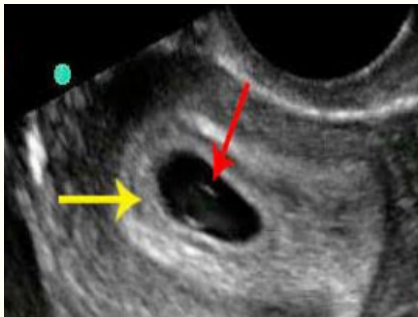
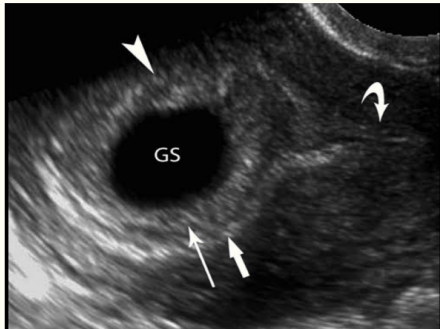



40 weeks : Relief of respiratory discomfort after descent of fetal head into pelvis.
(uterine height : Corresponds to 32 weeks)

Absolute Signs Of Pregnancy : Absent in pseudocyesis.

- Auscultation of FHS
 - Doppler : 10 weeks
 - Stethoscope : 20 weeks
- Palpation of fetal parts/fetal movement.
- USG evidence of pregnancy.
- Fetal skeleton visualized on x-ray.

USG Signs :

Intradecidual sign :	Double Decidual Sac sign :	Double bleb sign :
<ul style="list-style-type: none"> • 1st sign to be seen. • 1st structure : Gestational sac. 	<ul style="list-style-type: none"> • Gestational sac surrounded by 2 rings : <ul style="list-style-type: none"> - Inner ring : Decidua capsularis. - Outer ring : Decidua parietalis. • Obliteration of uterine cavity : 14-16 weeks. (Fusion of inner and outer ring) 	<ul style="list-style-type: none"> • Formed by yolk sac & amniotic sac. 

----- Active space -----

USG In Pregnancy & Macrosomia

00:28:10

USG MODALITIES IN PREGNANCY

modality	Timing
Dating/viability scan	6-8 weeks
Nuchal Translucency scan (NT scan)	11 to 13 weeks + 6 days
Anomaly scan/target scan (TIFFA/Level 2 scan) : (mandatory in all pregnant females)	18 to 20 weeks (Can be extended upto 22 wks)
Growth scan	32 & 34 weeks
Placental localization	32 weeks → Repeat at 36 weeks
Fetal Echo (Only if CHD is suspected in the fetus)	20 & 24 weeks

NT Scan :

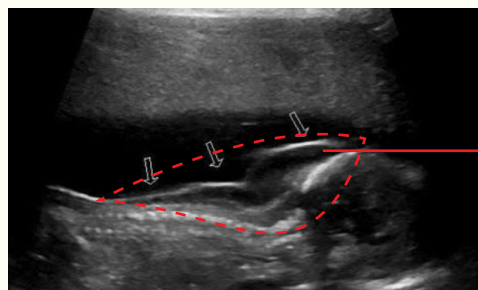
Normal nuchal translucency : <3 mm.

Causes of ↑ nuchal translucency (NT ≥3 mm) :

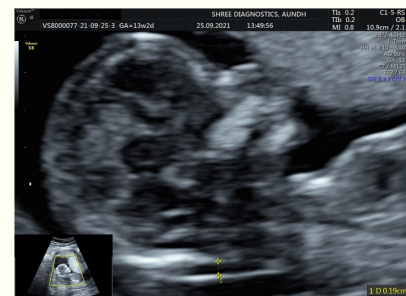- **Aneuploidy** (m/c) : Down's syndrome > Turner's syndrome > Trisomy 13/18.
- Congenital heart defects of fetus.
- ↑NT in twins : Early marker for Twin to Twin Transfusion Syndrome (TTTS).

Investigations :

1. Karyotyping
2. Fetal echo

D/d : **Cystic hygroma.**

Cystic hygroma

↑Fluid collection
(Generalized with
septa ⊕)

NT scan

ESTIMATION OF GESTATIONAL AGE

Earlier the timing of USG : ↑Accuracy of estimating gestational age.

Trimester	Best Parameter
T1 : Best time	MSD/CRL
T2/CRL ≥84mm	BPD > HC
T3	Femur length

Crown rump length (CRL) :

----- Active space -----

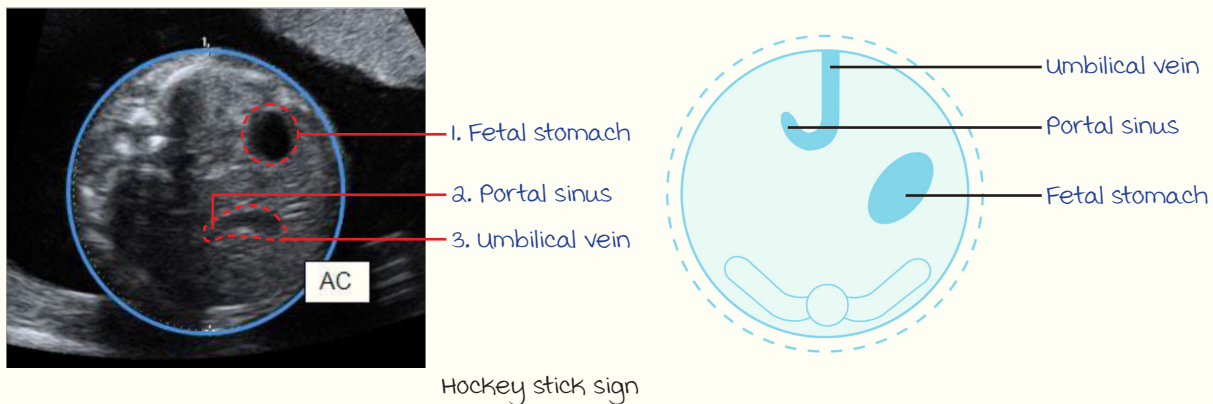
- Can be used till 13 weeks + 6 days (Till CRL < 84 mm).
- most accurate gestational age : Determined by CRL b/w 7-9 weeks.
- $CRL + 42$: Gestational age in days.
- Smallest measurable CRL : 5 mm.

Abdominal Circumference :

Best USG parameter for fetal growth.

Plane of measurement :

measured when all three structures mentioned are visible together.



Hockey stick sign

Note : Fetal weight estimation.

- Best clinical formula : Johnson formula.
- Best method : Hadlock formula/Shepard formula.

MACROSOMIA

Weight of fetus ≥ 4 Kg.

Risk factors :

- Post-term pregnancy
- Diabetic mother
- male fetus
- maternal obesity

management :

Diagnostics : AC ≥ 35 cm on USG.

mode of delivery : Vaginal.

Indications of C-section :

- Diabetic female with fetal weight ≥ 4.5 Kg.
- Non-diabetic female with fetal weight ≥ 5 Kg.
- H/o C-section : Relative C/I for VBAC.

----- Active space -----

Structures seen on USG in Pregnancy :

Structure	TVS	TAS
Gestational sac	4.5-5 weeks	5.5-6 weeks
Yolk sac	5 weeks	6 weeks
Fetal pole	5-5.5 weeks	6-6.5 weeks
Cardiac activity	5.5-6 weeks	6.5-7 weeks

Order of appearance : G. sac → Yolk sac → Fetal pole (CRL) → Cardiac activity.

Note :

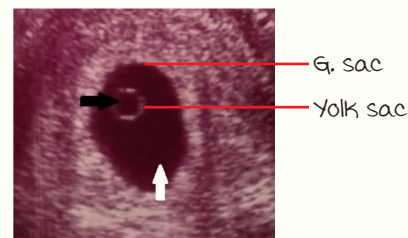
β HCG : Best parameter to differentiate b/w ectopic & intrauterine pregnancy.

Gestational sac : Only indicates pregnancy.

- Intrauterine pregnancy : True gestational sac.
- Ectopic pregnancy : Pseudo gestational sac.
(Thickened endometrium d/t progesterone)

G. sac + Yolk sac :

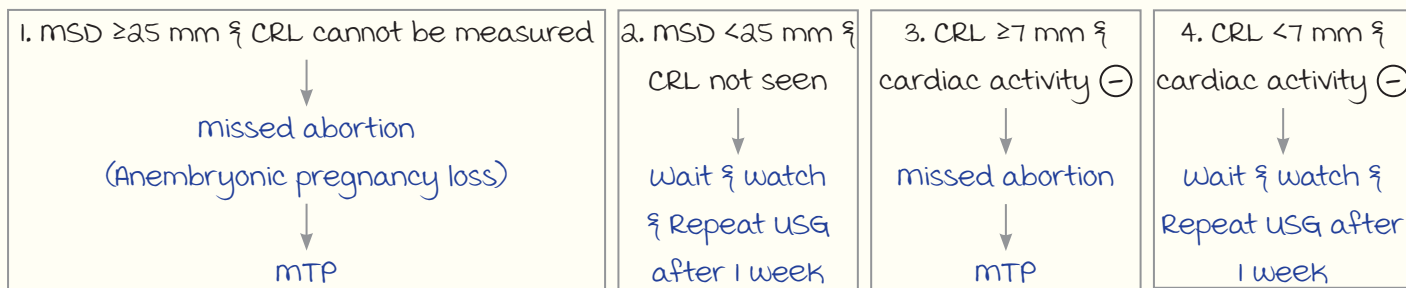
- Inside the uterus → Intrauterine pregnancy.
- Inside the fallopian tube → **ectopic pregnancy.**
(Confirmatory)



Important Cut-offs :

- MSD to measure CRL : 25 mm.
- CRL to get cardiac activity : 7 mm.
- HCG to see gestational sac on TVS (Critical titre) : **2000 IU.**
- minimum value of HCG at which G. sac is seen : 1000 IU.

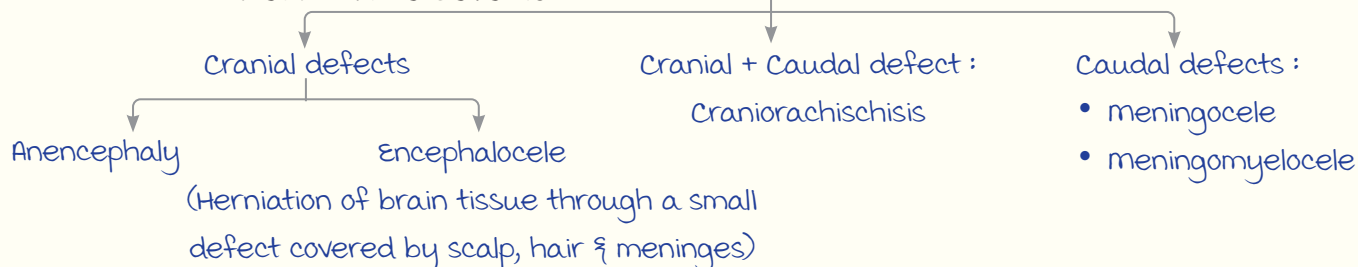
Scenarios And Protocols :



Anomalies Detected On Level 1 Scan

00:41:40

Neural Tube Defects :



Anencephaly :

----- Active space -----

Failure of closure of anterior neuropore → Brain tissue exposed to external environment.

Features :

- 1st anomaly to be detected on USG.
- Earliest detected by 10 weeks.
- Best detected by 14 weeks.

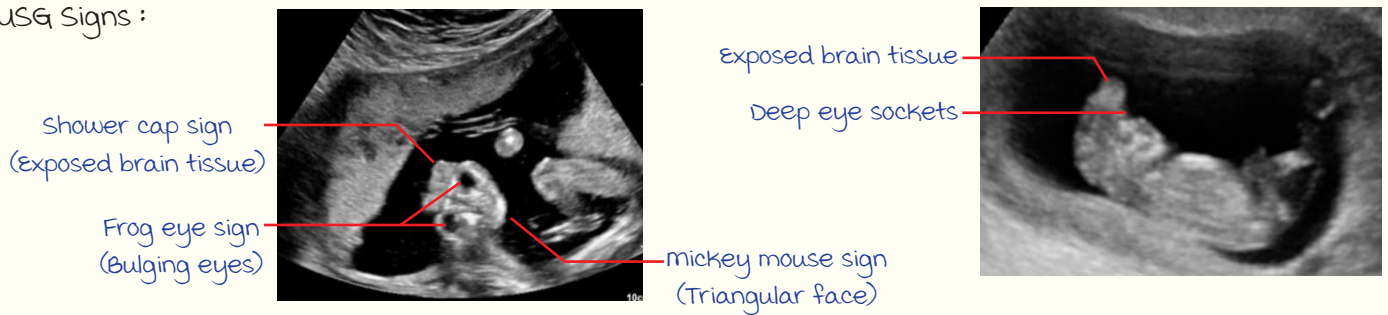
Note :

- GCA : Best detected on level 2 scan.
- Best time to check maternal serum AFP : 16-18 weeks.

Diagnosis :

- Screening test : Level 1 scan.
- Diagnostic test : Level 2 scan.
- Best biochemical marker : Acetylcholinesterase levels.

USG Signs :

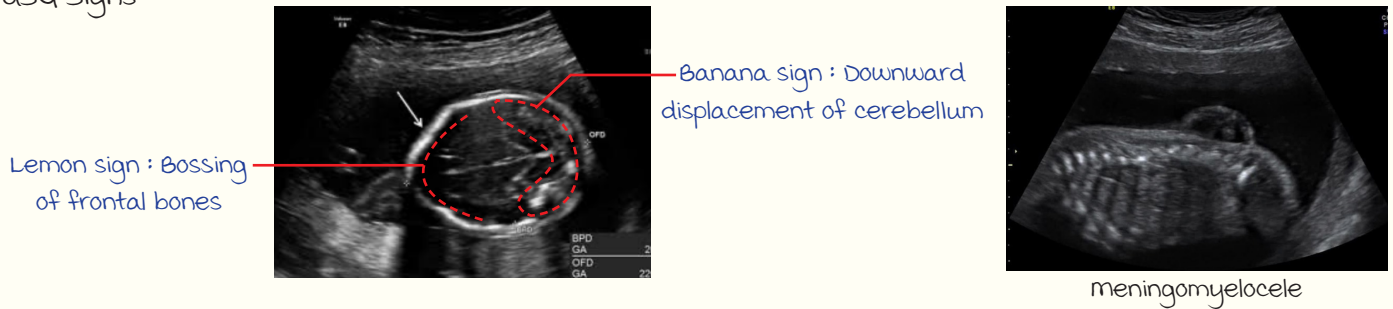


management : MTP

Spina Bifida :

- meningocele : Herniation of meninges.
- meningomyelocele : Herniation of meninges & spinal cord.

USG Signs :

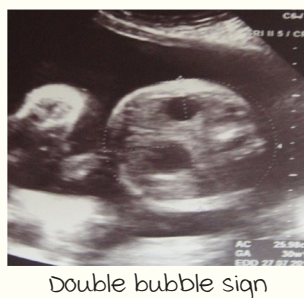

Duodenal Atresia :

Features :

- Defect in swallowing
- ↓
- Polyhydramnios
- A/w Down's syndrome.

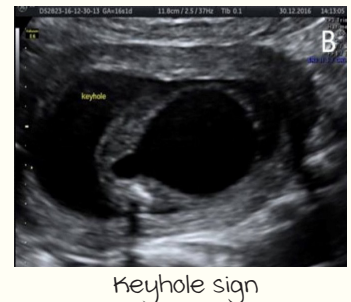USG : Double bubble sign

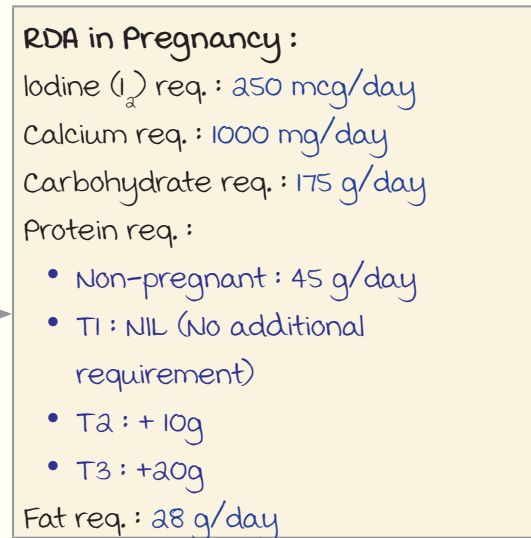
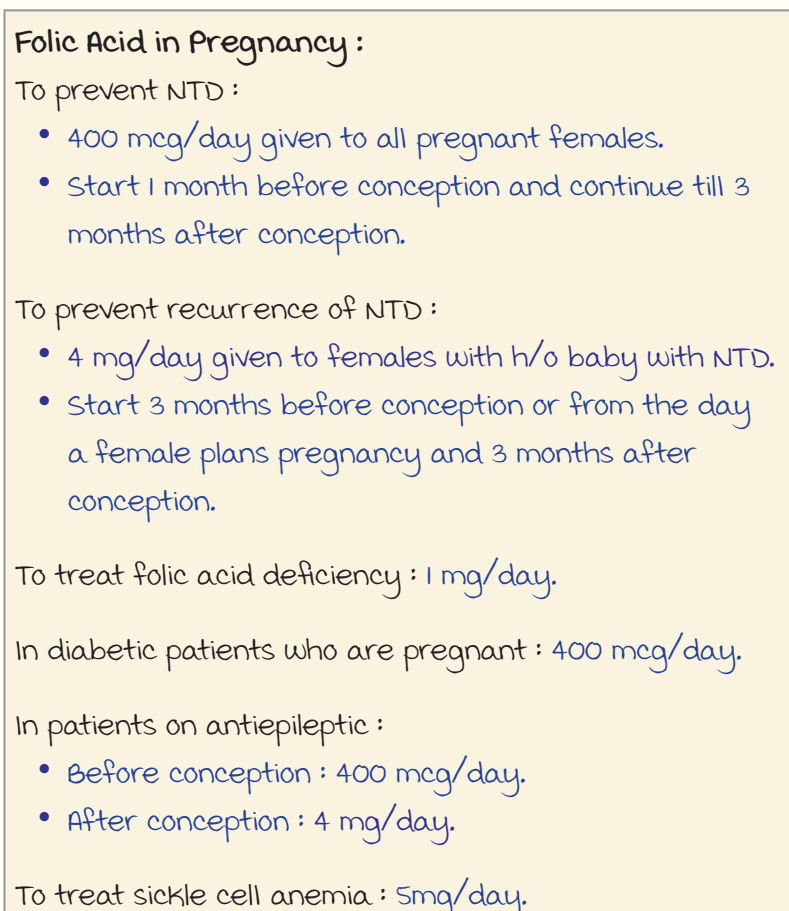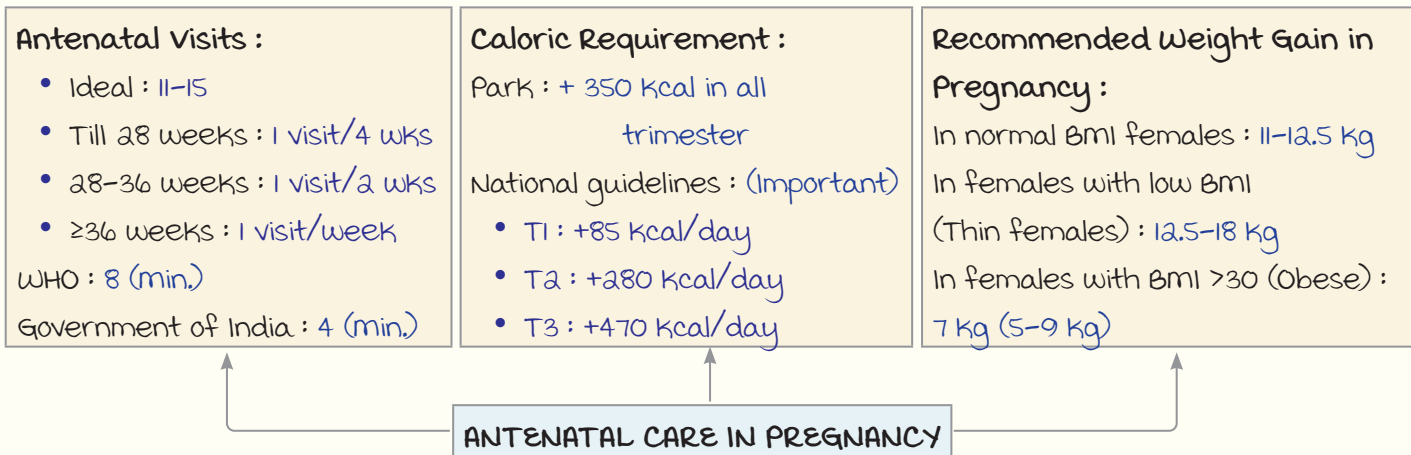


Posterior Urethral valve :

A/w Oligohydramnios.

USG : Keyhole sign.





VACCINATION IN PREGNANCY

Vaccines Absolutely C/I In Pregnancy :

- | | | | |
|-----------|-------------|---------------|-------|
| • mumps | • Rubella | • Chicken pox | • HPV |
| • measles | • Small pox | • BCG | |

Td vaccine : Given to all pregnant females.

- 1st dose : 1st antenatal visit.
- 2nd dose : 4 weeks after 1st dose.
- Booster dose : Given if 2 doses of immunization received in past 3 years.

----- Active space -----

Tdap vaccine : Tetanus + Diphtheria + acellular Pertussis.

- Protection against pertussis for the baby.
- ACOG Recommended single shot Tdap vaccine b/w 27-36 weeks.

Amniotic Fluid

00:55:05

Volume :

- 34 weeks (32-34 weeks) : 1000 mL (maximum).
- At term/40 weeks : 800 mL.
- >42 weeks : 200 mL.

Source :

Gestational age	Source
First trimester	maternal plasma
12-20 weeks	Fetal skin
>20 weeks	Fetal urine

Colour :

Colour	Seen in
Straw coloured	Term
Green colour (Due to biliverdin in meconium)	1. Fetal distress 2. Transverse lie/Breech 3. Listeria infection
Golden colour (Due to bilirubin)	Rh incompatibility
Tobacco juice/Brown	Intrauterine fetal death
Saffron colour, yellowish green	Post term pregnancy
Dark red	Concealed hemorrhage

AMNIOTIC FLUID DISORDERS

Normal values :

- AFI (Amniotic Fluid Index) : 5-24 cm.
- SVP (Single Largest vertical Pocket) : 2-8 cm.

----- Active space ----- **Oligohydramnios vs. Polyhydramnios :**

Oligohydramnios	Polyhydramnios
<ul style="list-style-type: none"> • AFI : <5 cm. • Single largest vertical pocket : (SVP) <2 cm. • m/c cause of mild oligohydramnios : Idiopathic. • m/c cause of severe oligohydramnios : Fetal renal anomalies. <ul style="list-style-type: none"> - Renal agenesis. - Posterior urethral valve. 	<ul style="list-style-type: none"> • AFI : >25 cm. • SVP : >8 cm. • mild Polyhydramnios : Idiopathic. • m/c cause of severe Polyhydramnios : Fetal GIT anomalies. <ul style="list-style-type: none"> - Esophageal atresia. - Duodenal atresia. - Cleft lip/Cleft palate.
Other causes :	Other causes :
1. Decreased transudation across placenta : (Small placenta) <ul style="list-style-type: none"> • PIH • IUGR • UPI 	1. Increased transudation across placenta : Placentomegaly d/t <ul style="list-style-type: none"> • Diabetes • Twin pregnancy • Rh negative pregnancy
2. Decreased urine output : <ul style="list-style-type: none"> • Renal disorders • Drugs : ACE inhibitors/Indomethacin 	2. Increased urine output : <ol style="list-style-type: none"> Twin pregnancy Diabetes Bartter syndrome Fetal anemia <ul style="list-style-type: none"> • Thalassemia • Rh negative pregnancy • Parvo virus infection
3. Decreased volume of Amniotic fluid : <ul style="list-style-type: none"> • Post term pregnancy • PROM • Leaking after amniocentesis 	3. Increased transudation from fetal skin : <ul style="list-style-type: none"> • NTD • Abdominal wall defect
4. Chromosomal Anomaly : (69 chr) Triploidy.	4. Chromosomal anomaly : Trisomy.

Conditions leading to both oligo & polyhydramnios :

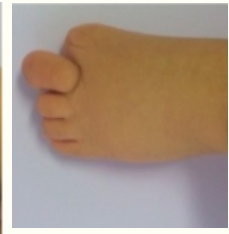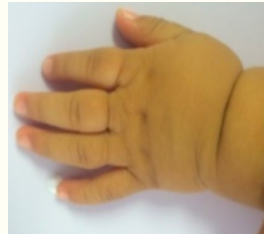- TTTS
- TORCH infections.

----- Active space -----

Amniotic band syndrome : Severe oligohydramnios d/t PPRoM.

c/f :

- Distal digit amputation.
- Craniofacial abnormalities.



Distal digit amputation

Note :

Proximal limb amputation :

Phocomelia d/t Thalidomide.

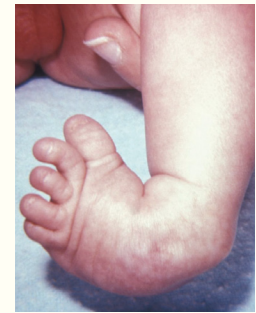Presentation Of Oligohydramnios :

Late pregnancy :

- Cord compression.
- Fetal distress.
- meconium aspiration syndrome.
- Club foot/CTEV.

Early pregnancy :

- Lung hypoplasia.
- Limb amputation.



Club foot

Placenta & HCG

01:08:25

PLACENTA

Dimensions :

- Weight : 500 gm.
- Ratio of placental weight to fetus at term = 1:6.
- Diameter : 15-20 cm.
- Placental weight = Fetal weight at 17 weeks.
- Central thickness : 2.5-4 cm.

Formation :

- maternal side : Decidua basalis.
- Fetal side : Chorion frondosum.

Features :

- Discoidal
- Deciduate : Shed off after delivery.
- Hemochorial : Lies in contact with maternal blood.

Placentomegaly : Placental thickness ≥ 4 cm.

Hormone secreted : hCG.

Umbilical cord : 3 vessels

- Right umbilical artery.
- Left umbilical artery.

- Left umbilical vein.

hCG :

Subunits : 2 subunits \rightarrow α : Similar to LH, FSH, TSH.
 \rightarrow β : Specific.

Source : Produced by syncytiotrophoblast.

Function : maintain corpus luteum of pregnancy.

Doubling time : 48 hours.

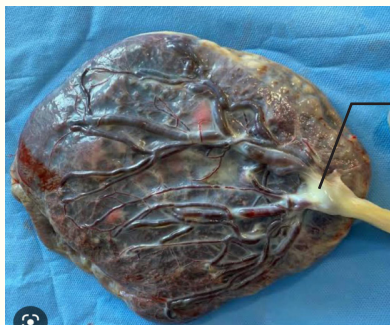Levels :

- Appears in blood : Day 8-9 after fertilization (Day of cycle).
- Peak levels : 9-10 weeks.
- Plateau : 16-20 weeks.

$T_{1/2}$: 36 hours.

----- Active space -----

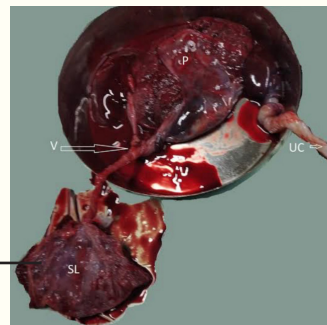
PLACENTAL ANOMALIES



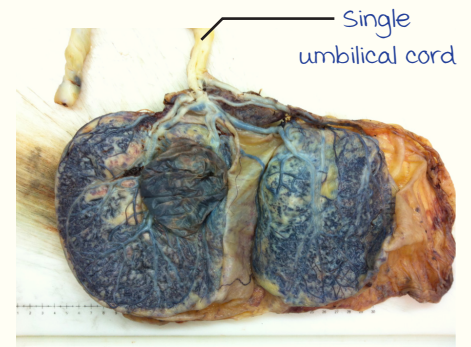
Battledore placenta

marginal
insertion
of cord

Succenturiate
lobe

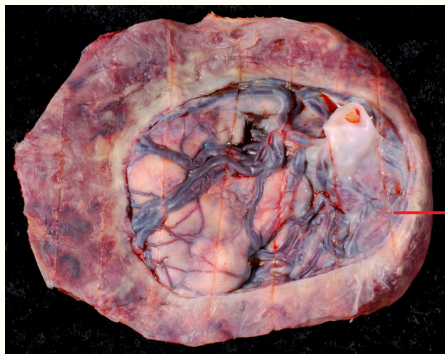


Placenta succenturiata
(Unequal lobes)



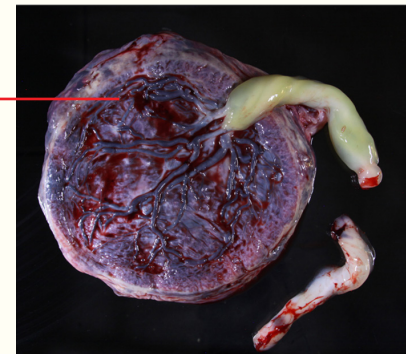
Placenta bilobata (Equal size lobes)

maternal side larger than fetal side :



Circumvallate placenta

Valve-like
thickening



Circummarginate placenta

No valve-like
thickening

Investigations Done At 1st ANC Visit

01:15:42

1. ABO, Rh typing

↳ If Rh-ve →

- Husband's Rh typing.
- Indirect Coombs' test.

2. Hb (Checked at least 4 times in pregnancy), Hematocrit.

3. VDRL.

4. HbsAg.

5. urine R/m.

6. HIV testing : Opt-out approach
(Patient can refuse).

7. DIPS1 → Repeat at 24-28 weeks.

8. Group B Streptococcus : 35-37
weeks (Rectovaginal swab taken).

Additional tests (voluntary) :

1. TSH.

2. Aneuploidy.

OBSTETRICS : PART 2

Abortions

00:00:48

Definition of abortion :

- Pregnancy loss before 20 weeks of pregnancy or before weight of fetus is 500 gm (WHO).
- Note : Weight of fetus at 20 weeks → 330 gm.
- Weight of fetus @ 22 weeks : 500 gm.

m/c Cause of T1 and T2

Spontaneous, Isolated Abortion :

Aneuploidy > Trisomy > monosomy X
> Trisomy 16.

- m/c uterine cause of T1 abortion or T1 recurrent abortion : Septate uterus.
- m/c uterine cause of T2 abortion or T2 recurrent abortion : Cervical incompetence.

(T1 : 1st trimester, T2: 2nd trimester)

m/c risk factors for abortion :

- ↑maternal age.
- Previous H/o abortion.

Recurrent Abortion :

Conventional definition : ≥3 abortions.

Definition by ASRM :

If there is occurrence of two or more consecutive losses of recognised pregnancies by USG or HPE before 20 weeks, start evaluating.

Four Established Causes of RPL :

1. APLA syndrome (Single most common cause) : 16%.
2. uterine structural abnormalities : Congenital - septate uterus & acquired - cervical incompetence, fibroid, polyp.
3. Chromosomal abnormalities (Balanced translocation of chromosome) are responsible for RPL in 4% cases.
4. Hypothyroidism.

Note : Infections including syphilis and TORCH do not cause RPL, they cause sporadic losses.

m/c group causing RPL : Endocrine causes > uterine causes.

Investigation for RPL :

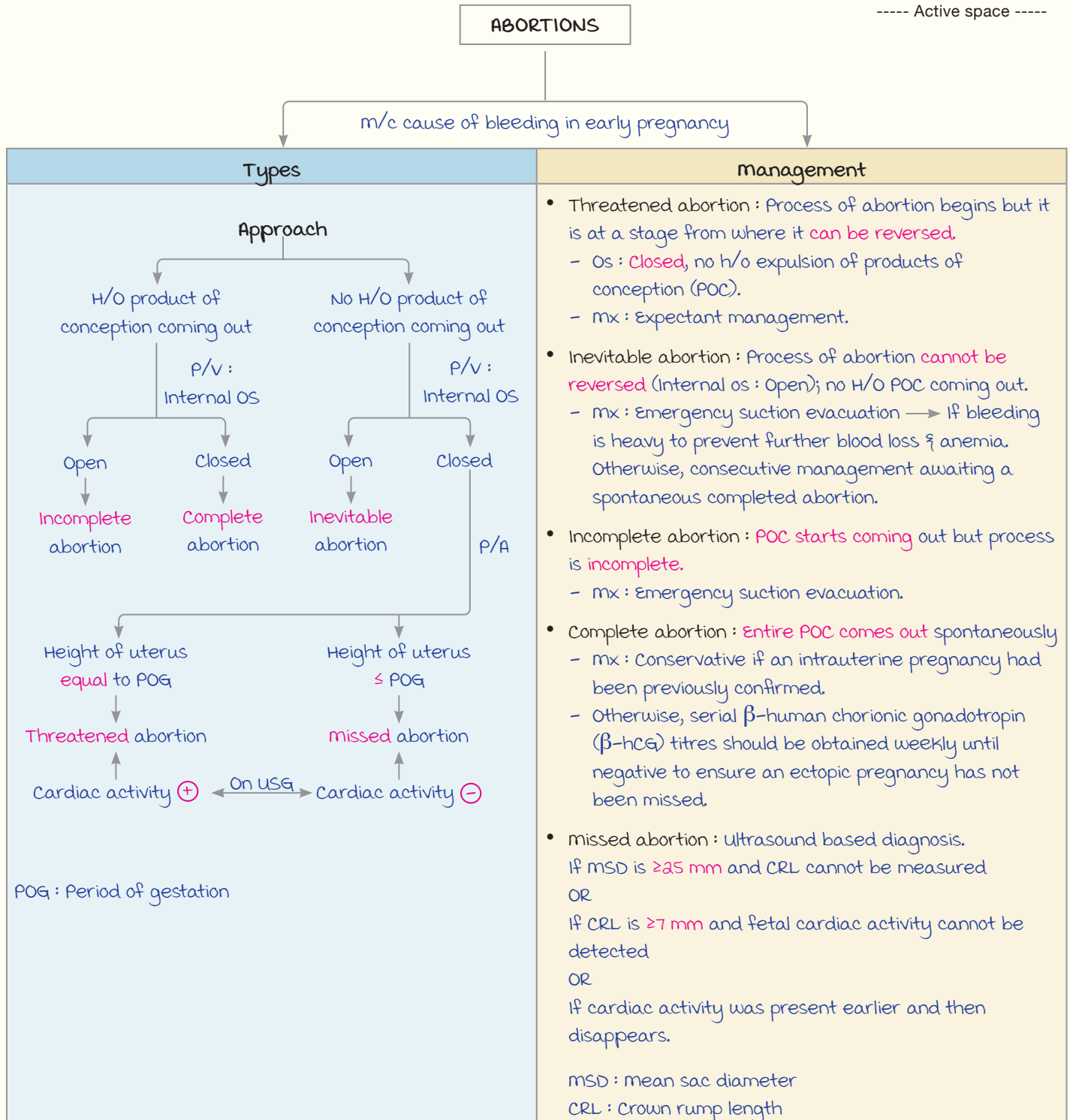
- Ultrasound uterus (TVS).
- APLA antibodies.
- Parental karyotype.
- TSH.

Investigation not done in RPL : TORCH, HIV & VDRL test

RPL : Recurrent Pregnancy loss

ABORTIONS

----- Active space -----



----- Active space -----

Cervical Insufficiency/Incompetence

00:11:35

Definition :

- Spontaneous dilatation of cervix (Internal os) d/t shortening of cervix.
- H/o painless recurrent TA abortions.

IOC : **USG (TVS).****History Based Diagnosis :**

≥2 abortions of second trimester (Painless) : Confirm cervical insufficiency.
No need for USG to measure cervical length.

USG-based Diagnosis :

H/O **one** second trimester abortion + TVS done in present pregnancy shows length of **≤2.5 cm**.

On TVS : Cervical Insufficiency

- Length of cervix : **≤2.5 cm** (Ⓝ Pregnant ♀ : 4cm).
- Shape of cervix : 'U' shaped.

Management of Cervical Insufficiency :

1. Progesterone.
2. Cervical (Cx) cerclage.

Next Steps :

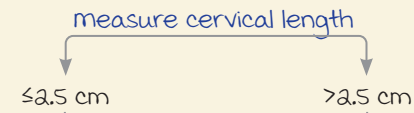
1. Pregnant female has h/o two TA abortions :

Next step :

- USG not required
- mx : Cervical cerclage + progesterone

2. Pregnant female has h/o one TA abortion :

Next step :



3. Pregnant female with no H/O abortion but cervical length <2.5 cm :

Next step : Progesterone

CERVICAL INSUFFICIENCY**Cervical Cerclage**

It can be done in pregnant females and non pregnant females.

Pregnant Females :**1. Transvaginally :**

- **McDonald cerclage (m/c)** : Purse string suture applied.
- **Shirodkar cerclage.**
- **Wurms cerclage** (2 sutures are applied; AKA Hefner cerclage) : Done as **emergency cerclage** → 2 stitches anteroposteriorly.

2. Transabdominally

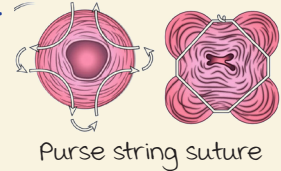
- **Benson and Durfee cerclage :**
 - Can be done laparoscopically.
 - Can be done during or before pregnancy.
- Indications : Failed transvaginal cerclage.
- Drawback : Sutures have to be removed transabdominally.
 - The suture should be removed only after female has completed her family.
- Delivery should be done : By cesarean section.

Non-pregnant Females :**1. Vaginally : LASH & LASH procedure**

- Here defective cervix is removed surgically.
- Patient should be advised to give a **gap of 3 months before conceiving.**
- Fetus should be delivered by cesarean section.
- Not done d/t ↑ complications.

2. Abdominally : Laparoscopic cerclage.**McDonald Cerclage :**

- m/c done.
- Suture : Nonabsorbable monofilament.
- Purse string sutures : Applied on **portiovaginalis.**
- Time : 14-16 weeks.
 - Earliest : By 12 weeks.
 - Maximum : By 24 weeks.

**C/I for Cerclage :**

1. Ruptured membranes (Chorioamnionitis).
2. Bleeding.
3. Uterine contractions.
4. Fetal demise/gross congenital anomalies.
5. Current pelvic infection.
6. Cervix dilated ≥3 cms.

Relative C/I : **Placenta previa.**Time to remove stitch : **37 weeks.****Note :**

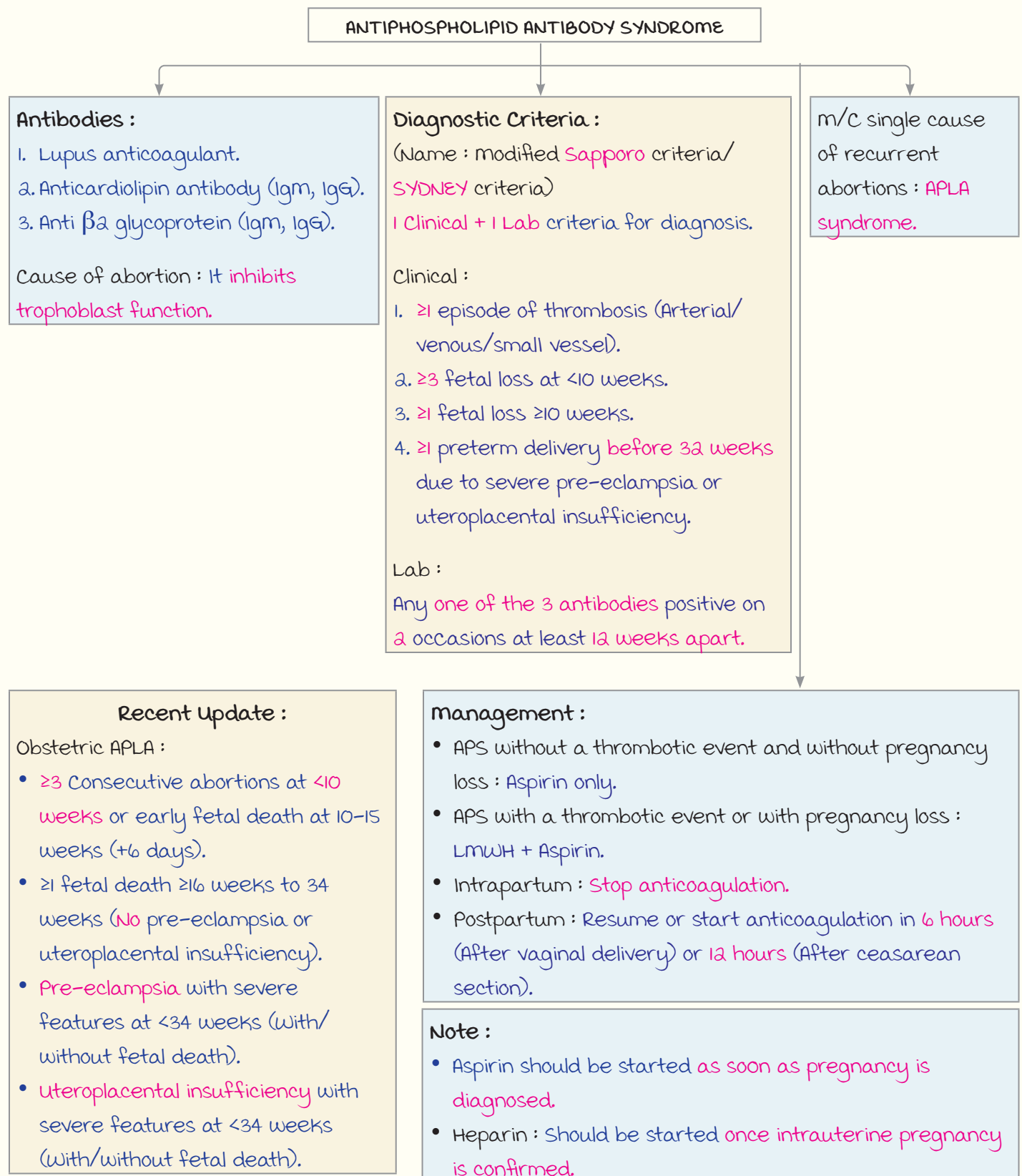
Shape of cervix on USG as it dilates :

Normal → T shaped → Y shaped →
 V shaped → U shaped.

Antiphospholipid Antibody

00:22:36

----- Active space -----



Medical Termination of Pregnancy

00:28:05

----- Active space -----

MTP Amendment 2022 :

- MTP can be done till : 24 weeks.
- In case of contraceptive failure : MTP done till 20 weeks only.
- In severe congenital anomalies of fetus : **No upper limit** (if medical board permits).
- **medical board** : Gynaecologist, Radiologist & Paediatrician
- Single doctor opinion : upto 20 weeks.
- 2 doctors opinion needed : 20-24 weeks.

Qualifications to do MTP

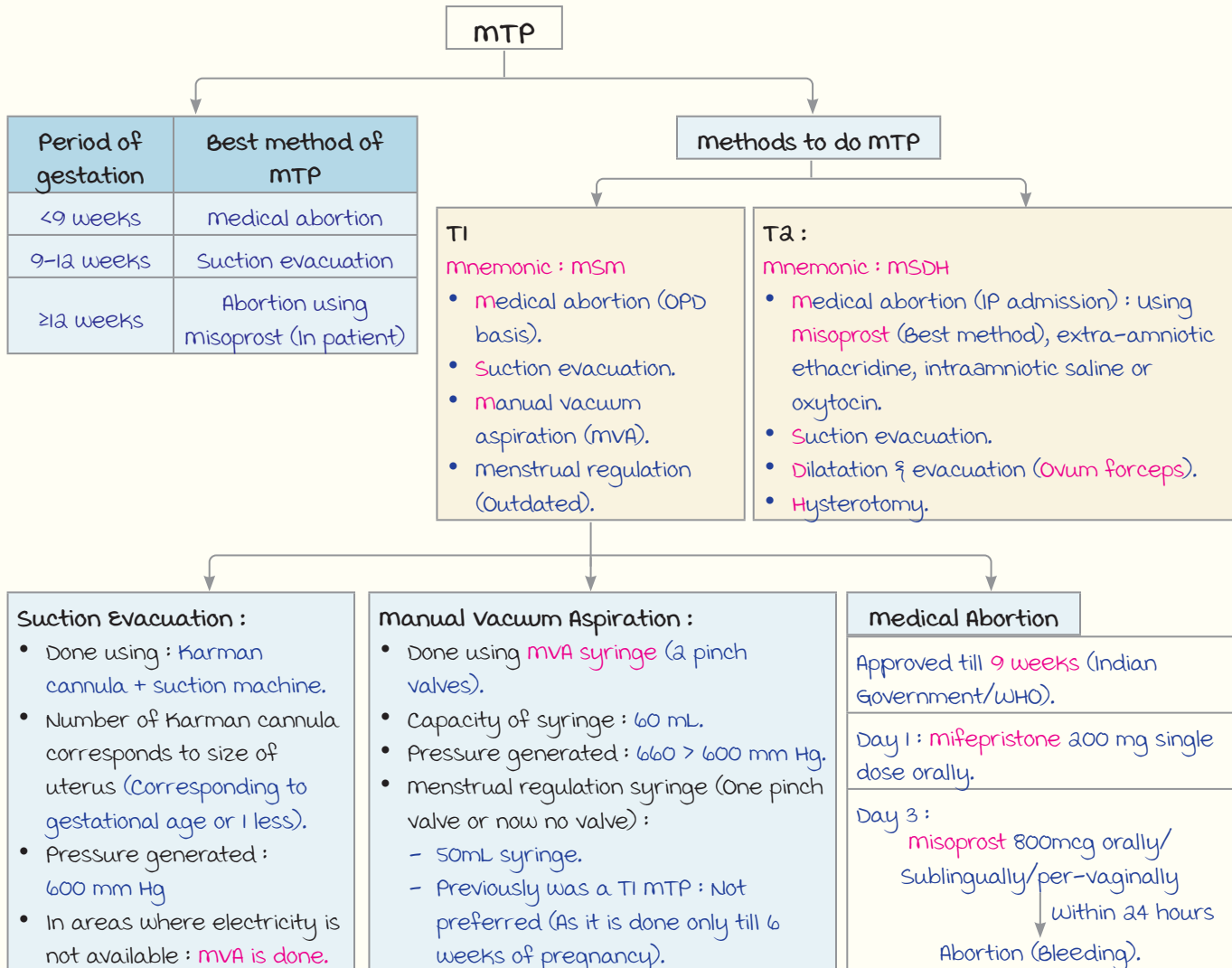
For doing MTP till 12 weeks :
RMP who has **assisted in 25 MTPs** (At least 5 should be as primary surgeon).

For doing MTP between 12-20 weeks :
1. RMP with 6 months of house job in Obs gynae or RMP with 1 year of experience in any hospital with all facilities.
2. Diploma/Degree/DNB in Obs and gynae.

Requirements for MTP

- Female's consent is needed for MTP.
- In minor/mentally retarded patients : Guardian consent needed.
- Age proof not needed.
- **marriage certificate : Not needed.**
- FIR report of rape : **Not needed.**
- All records of MTP should be **maintained for 5 years.**

RMP : Registered medical practitioner.



Suction Evacuation :

- Done using : Karman cannula + suction machine.
- Number of Karman cannula corresponds to size of uterus (Corresponding to gestational age or 1 less).
- Pressure generated : 600 mm Hg
- In areas where electricity is not available : **MVA is done.**

Manual vacuum Aspiration :

- Done using **MVA syringe** (2 pinch valves).
- Capacity of syringe : 60 mL.
- Pressure generated : 660 > 600 mm Hg.
- menstrual regulation syringe (One pinch valve or now no valve) :
 - 50mL syringe.
 - Previously was a TI MTP : Not preferred (As it is done only till 6 weeks of pregnancy).

Medical Abortion

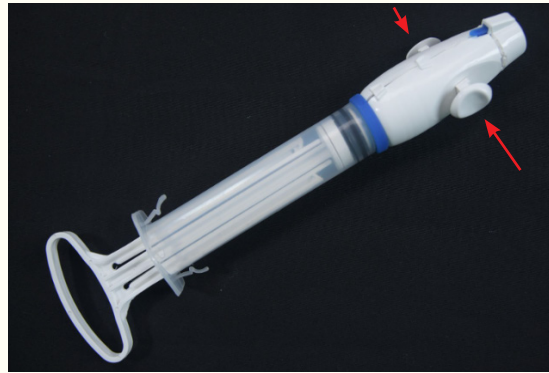
Approved till **9 weeks** (Indian Government/WHO).

Day 1 : **mifepristone** 200 mg single dose orally.

Day 3 :
misoprost 800mcg orally/
Sublingually/per-vaginally
↓
within 24 hours
Abortion (Bleeding).



Karman cannula




mVA syringe (2 pinch valves)

----- Active space -----



Hegar's dilators



menstrual regulation syringe
(1 pinch valve)

uterine perforation during suction evacuation :

D/t Hegar's dilators	D/t Karman cannula
<ul style="list-style-type: none"> • Stop procedure • monitor vitals 	<ul style="list-style-type: none"> • Stop procedure • Do not take cannula out • Immediate laparotomy

----- Active space -----

Ectopic Pregnancy

00:37:29

m/c site : Fallopian tube → Ampulla.
 m/c nontubal site : Ovary.
 L/c site : Cesarean scar/cervix.
 Cornual pregnancy : Site → Intramural part.
Heterotopic pregnancy : Twin pregnancy; one is intrauterine, other ectopic (mx : **Always surgical**).

Named Criteria :

Site	Criteria
Cervical	Palman, Rubin
Abdominal	Studdiford
Ovarian	Spiegelberg

Triad of Symptoms :

Amenorrhea (6-10 weeks), pain in lower abdomen and bleeding P/V.

Symptoms :

To suspect ruptured ectopic :

1. Orthostatic hypotension.
2. Shoulder tip pain.
3. Urge to defecate.

Signs : Ruptured Ectopic

1. Shock (↑PR, ↓BP).
2. P/A : Abdominal **distension**, rebound tenderness.
3. If localizing signs → Guarding (+)
Rigidity (+) } Hemoperitoneum

ECTOPIC PREGNANCY**Risk Factors :**

Maximum risk :

- Previous h/o tubal Sx.
- Previous h/o ectopic pregnancy.

m/c risk factor : PID/salpingitis.

Contraceptives :

Decrease **absolute risk** of ectopic but if failure of contraception occurs, then ectopic pregnancy risk is increased.

m/c : **Tubal sterilization** > MIRENA > IUCD > POP.

Presentation :

Female with 6-8 weeks amenorrhea, pain in abdomen, spotting, vitals unstable, UPT+ve

Next Step :

- If on P/A, guarding and rigidity present : Confirms hemoperitoneum → mx : **Sx** of ruptured ectopic.
- If guarding and rigidity are not present : **FAST** → Done to confirm diagnosis.

P/V Finding :

- most important : **Adnexal mass**.
- **Cervical movement tenderness** : D/t peritonitis (Cervical motion tenderness is also seen in PID)
- uterus is soft and enlarged but **size is less than POG**.

Management of Ruptured Ectopic :

- **Always surgical**.
- No role of conservative management or medical management.

Route of surgery :

- If vitals stable : Laparoscopy.
- If unstable vitals : Laparotomy.

Surgery of choice : **u/L salpingectomy**

Surgeries never done for ruptured ectopic :

- Salpingo-oophorectomy.
- Linear salpingostomy (Done for unruptured ectopic).

Unruptured Ectopic

00:45:15

----- Active space -----

Investigations done in Unruptured Ectopic :

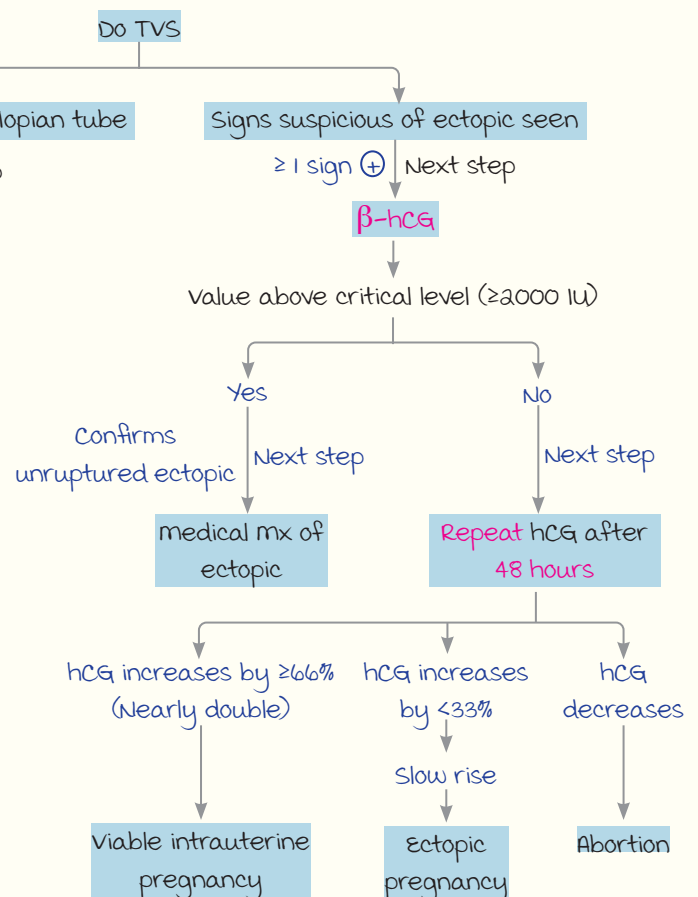
1. TVS :

- **Confirmed sign** of ectopic pregnancy : Gestational sac + yolk sac \pm cardiac activity seen in fallopian tube.
- **Suspicion of ectopic** if seen on USG :
 - Adnexal mass (m/c finding on USG).
 - Bagel sign (Only gestational sac \oplus).
 - Ring of fire appearance.
 - Empty uterus.

2. Beta-hCG :

- **Critical value of hCG** is that value of hCG above which in all intrauterine pregnancies, gestational sac is visible inside uterus.
 - TVS : 2000 IU.
 - TAS : 6500 IU.

Algorithm for Diagnosis of Unruptured Ectopic :



Note : Ix for ectopic pregnancy.

IOC in ectopic : TVS.

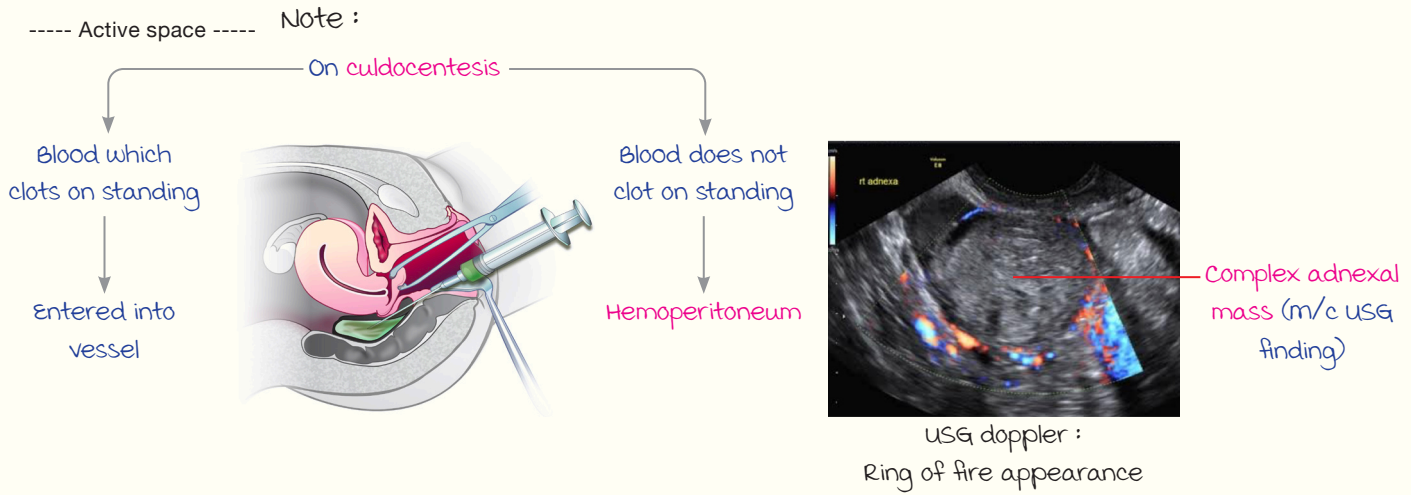
Gold standard Ix in ectopic : Laparoscopy.

Ix which may be done :

- S. progesterone.
- **Culdocentesis** (Ruptured ectopic).

Ix never done :

- Hysteroscopy.
- HSG.
- Colpotomy (Drainage of pelvic abscess).



management of unruptured Ectopic :

medical mx
<ul style="list-style-type: none"> • Best mx of ectopic pregnancy. • DOC : methotrexate (MTX). • Frequency : Single dose therapy. • Dose : 1 mg/kg. • Route : Im.

Prerequisites for MTX
<ul style="list-style-type: none"> • Patient : Vitally stable. • Family : Not complete. • Size of ectopic : <4 cm. • Beta-hCG : <5000 IU. • Cardiac activity : Preferrably absent.

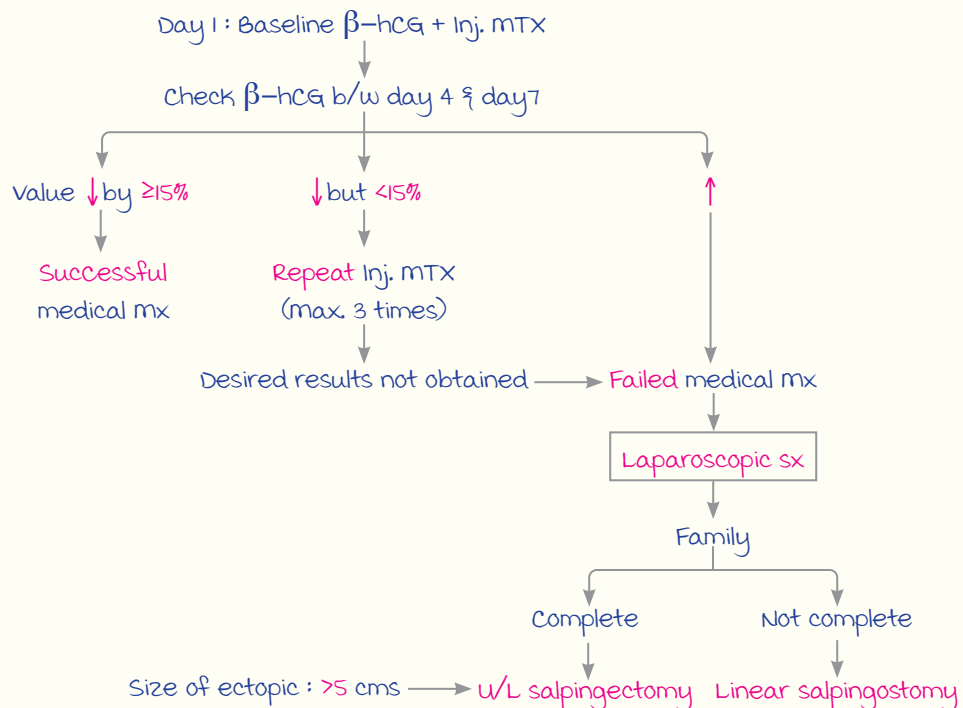
Absolute requirement

(Relative requirement)

Any prerequisite not fulfilled :

Laparoscopic sx

Treatment algorithm :



OBSTETRICS : PART 3

----- Active space -----

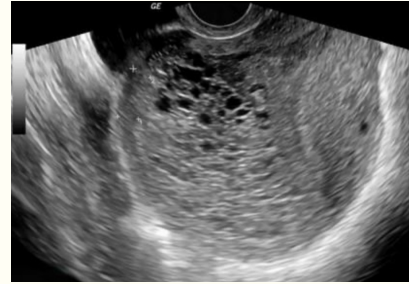
Molar Pregnancy

00:00:08

Benign disease of trophoblast with malignant potential.

Features d/t ↑HCG :

- Hyperemesis gravidarum.
- Thyrotoxicosis.
- B/L theca lutein cysts.



USG : Snow storm appearance

Types :

	Complete/vesicular mole	Partial mole
Pathogenesis	Empty ovum fertilized by 1 sperm	Ⓝ ovum fertilized by 2 sperms
Karyotype	Diploid : 46 XX	Triploid : 69 XXY
maternal chromosome	⊖	⊕
Extragenetic material	Paternal	
P/A examination	Fundal height > POG	Fundal height ≤ POG
	Absent FHS, no fetal parts felt	
β-hCG value (Compared to Ⓝ pregnancy)	↑↑	↑
USG : IOC	Snow storm appearance	Appearance of missed abortion
HPE : Gold standard	Trophoblastic proliferation, villi ⊕	
	No fetal tissue	Some fetal tissue ⊕

mx :

- Suction evacuation $\xrightarrow{F/b}$ Sharp curettage \xrightarrow{Sample} HPE.
- If age >40 years + family complete : TAH.

Follow up :

weekly β HCG levels \xrightarrow{Till} 3 consecutive findings Ⓝ/undetectable $\xrightarrow{F/b}$ monthly β hCG x 6 months
(Pregnancy is C/I : OCP preferred).

mx of theca lutein cysts : Spontaneously regress (No mx).

----- Active space -----

Gestational Trophoblastic Neoplasia

00:04:13

Types :

	Features	management
Invasive mole	m/c GTN after molar evacuation	Chemotherapy
Choriocarcinoma	<ul style="list-style-type: none"> m/c GTN after full-term pregnancy m/c cause : molar pregnancy 	
Epithelioid Trophoblastic tumour (ETT)	-	Hysterectomy + Chemotherapy
Placental Site Trophoblastic Tumour (PSTT)	Occurs primarily after full term pregnancy	

- HPE is **not required** to differentiate b/w GTN.

Signs & Symptoms :

- Persistent bleeding.
- Persistent theca lutein cyst. } **After evacuation.**
- Shock (D/t **Invasive mole**).
- Subinvolution of uterus.
- metastasis : **Lungs** > vagina.

Lab Ix :

- In 3 consecutive weeks : \uparrow hCG >10%
→ **Choriocarcinoma**.
- In 4 consecutive weeks : **Plateau** hCG (within 10% of \odot range) → **Invasive mole**.
- hCG detected even after 6 months of suction evacuation.
- HPE : Shows **GTN**.

Type of Chemotherapy Based on Stage and WHO Score :

Stage	WHO risk score	mx
1 → Limited to uterus	-	Single agent chemotherapy : multidose methotrexate (MTX) → On D1, D3, D5, D7 alternating with folinic acid.
2 → Pelvic spread	≤ 6 : Low risk	Multi agent chemotherapy : EMACO/Bagshaw regime → <ul style="list-style-type: none"> Etoposide Methotrexate Actinomycin D Cyclophosphamide Oncovin
3 → Spread to lungs	≥ 7 : High risk	
4 → Spread to other metastatic sites	-	

Note :

m/c chest x-ray finding in lung mets :

Canon ball appearance > Snow storm appearance.

WHO Scoring System :

----- Active space -----


	Low risk	High risk
Age	<40 years	≥40 years
hCG value	≤10 ³	≥10 ⁵
Antecedent pregnancy	molar pregnancy	Full term pregnancy
Interval b/w antecedent pregnancy & GTN diagnosis	<4 months	>12 months
Tumour size	<3 cm	>5 cm
No. of metastases	<4	>8
Site of metastases	Lungs, vagina	Brain, liver
Prior failed therapy	⊖	⊕

Antepartum Hemorrhage

00:13:13

Any bleeding ≥ 28 weeks of pregnancy before placental separation.

Causes & D/D :

Placenta previa	Abruptio placenta	Vasa previa	uterine rupture
No pain abdomen	Pain abdomen ⊕	No pain abdomen	Pain abdomen ⊕
<ul style="list-style-type: none"> Causeless Recurrent Bright red color blood Warning hemorrhage seen 	<ul style="list-style-type: none"> Precipitating factors : PIH/trauma/PROM Not recurrent Dark red bleeding AKA accidental hemorrhage 	<ul style="list-style-type: none"> D/t fetal blood loss Less blood loss + marked fetal distress After ARM : Fetal distress + bleed m/c seen in :  <p>Velamentous insertion of cord</p>	<ul style="list-style-type: none"> Blood : Bright red in color Known case of previous C-section (m/c cause in scarred uterus) <p>w Note :</p> <ul style="list-style-type: none"> m/c cause in unscarred uterus : Obstructed labour m/c drug causing uterine rupture : misoprost (C/I in h/o previous LSCS)

P/A Findings :

Placenta previa	Abruptio placenta	uterine rupture
<ul style="list-style-type: none"> uterus relaxed Soft, non-tender Height of uterus = POG Fetal heart sounds : ⊖ 	<ul style="list-style-type: none"> uterus : Tense + tender Well defined uterine contour Fundal height > POG Fetal parts not easily felt Fetal distress ⊕ 	<ul style="list-style-type: none"> Generalized abdominal tenderness Fetal parts superficially palpable uterine contour cannot be made out Fetal distress ⊕ / Fetal heart sounds ⊖

----- Active space -----

Classifications of Placenta Previa :

Old classification		New classification
Type	Description	
1/ Lateral	Placental edge within 2 cm of the os (Doesn't touch it)	Low lying placenta
2/ marginal	Placental edge reaches the margin of os	Placenta previa
3/ Incomplete	Placenta partially covers the os	
4/ Complete	Placenta completely covers the os	

Investigations :

- P/S, P/V examination : **C/I** in placenta previa but not in abruptio.
- **Screening USG** to differentiate b/w placenta previa and abruptio : **TAS**.
- **IOC** in placenta previa : **TVS**.
- Best time to do USG to rule out placenta previa : **T3** (32 weeks $\xrightarrow{f/b}$ 36 weeks).

Importance of USG in placenta previa :

- Confirm diagnosis
- Detect malpresentation
- Rule out placenta accreta spectrum (PAS)

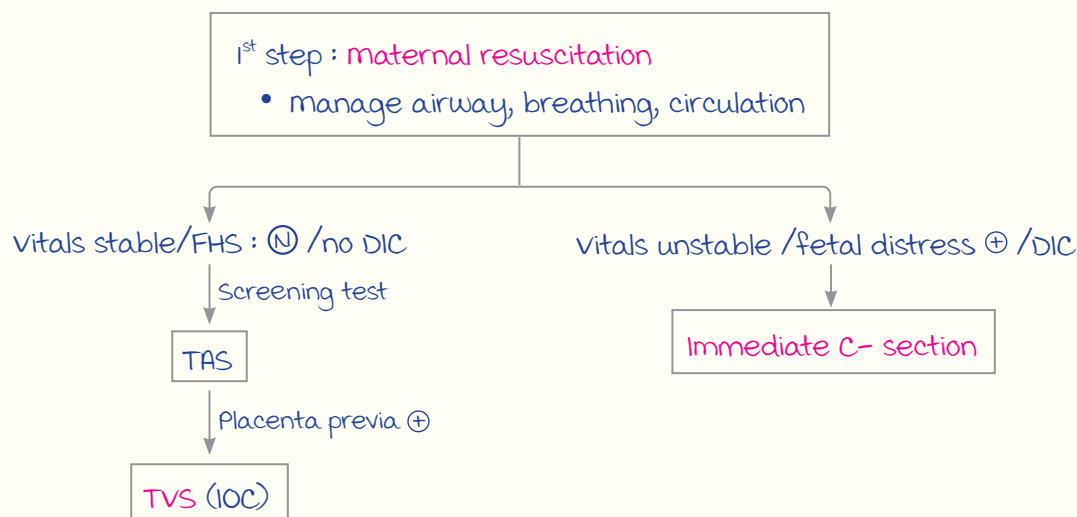
Note (97) :

- m/c malpresentation in placenta previa : **Transverse lie** > breech presentation.
- In placenta previa : Placenta accreta spectrum is possible.
- **Stallworthy sign** : Seen in posterior variety of placenta previa.
- Older type 2 posterior placenta was called **dangerous variety placenta previa**.

Rx & Complications of APH

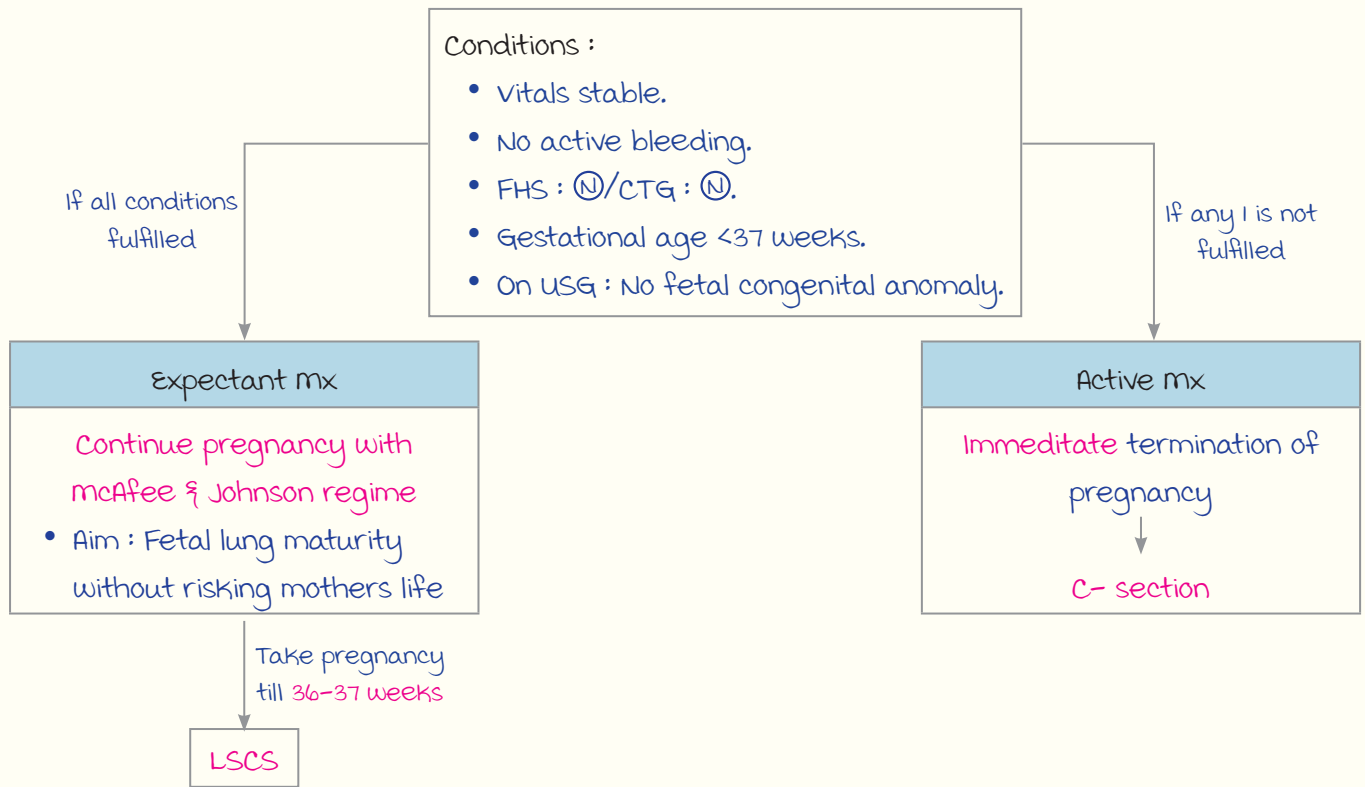
00:25:25

mx of a Case of Bleeding \geq 28 weeks (Diagnosis not known) (97) :



mx of Placenta Previa :

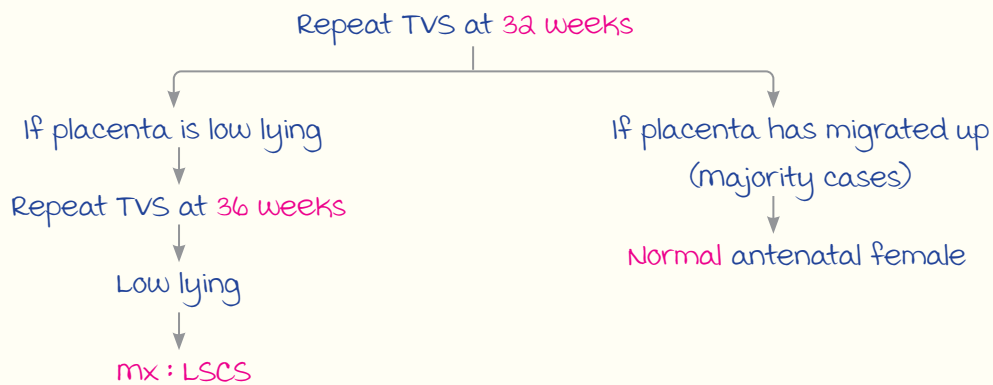----- Active space -----



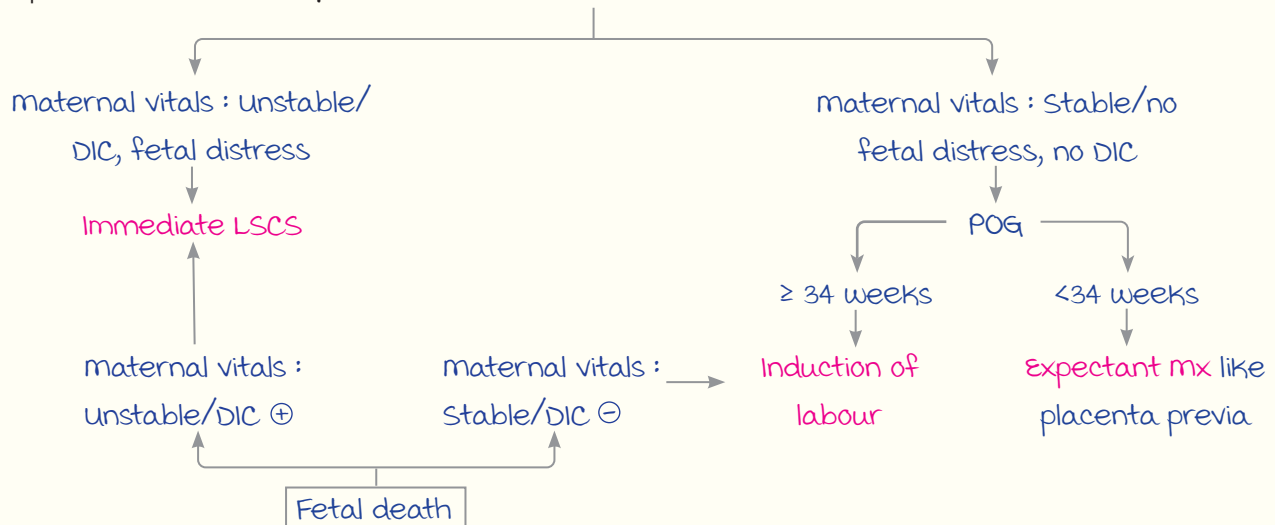
McAfee & Johnson regime :

- Admit the patient → Arrange blood → Give Inj corticosteroid (For fetal lung maturity).
- If contractions ⊕ and gestational age <34 weeks : Give tocolytics (C/I ≥34 weeks).
- Give $MgSO_4$ for neuroprotection (Gestational age <32 weeks).
- Anti-D in Rh negative patients.

mx of Low Lying Placenta in Level 2 Scan :



----- Active space -----

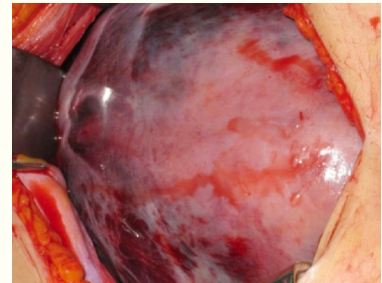
mx of Abruption Placenta :

ARM : To be done in all patients of abruption (Help make diagnosis, ↓ blood loss, augments labour).

Complications :

Associations of abruption :

- DIC.
 - Preterm labour.
 - Couvelaire uterus : Seen in concealed hemorrhage (Hysterectomy is **not** done).
 - Retroplacental clot.
- } (D/t thromboplastin release)



Couvelaire uterus

Disseminated Intravascular Coagulopathy (DIC) :

- m/c cause : **Abruption placenta**.
- Other causes : Intrauterine death of fetus, amniotic fluid embolism, septic shock, acute fatty liver of pregnancy.
- mx : Fresh Frozen Plasma (FFP)/**Cryoprecipitate**.

Note :

PCPNDT act : Radiologist (During antenatal checks) can look for congenital anomalies of the fetus but **not sex**.

OBSTETRICS : PART 4

----- Active space -----

Placental Hormones :

1. hCG.
 2. HPL.
 3. Estrogen : From **DHEA-S** produced by **fetal adrenal gland**.
 4. Progesterone
- } ↑E & ↑P (In pregnancy) → ↓FSH, ↓LH
↓
Suspension of ovulation.

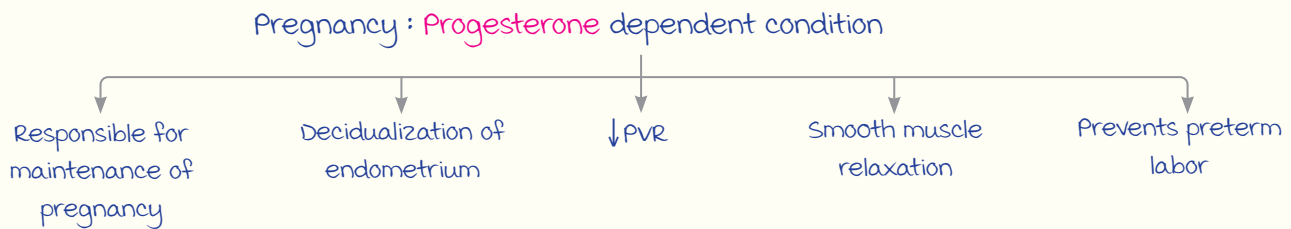
m/c site of production : Syncytiotrophoblast.

Source of Estrogen + Progesterone :

Corpus luteum of pregnancy $\xleftarrow{\text{Before}}$ 8 weeks $\xrightarrow{\text{After}}$ Placenta.

Physiological Changes in Pregnancy

00:00:45



Estrogen dependent changes in pregnancy :

1. Skin changes : Chloasma.
2. Salt & water retention (↑**Blood volume**)
3. Obstetric cholestasis.
4. ↑TBG (Thyroid binding globulin).
5. For onset of labor $\left\{ \begin{array}{l} \uparrow \text{Oxytocin receptors.} \\ \text{Functional withdrawal of progesterone.} \end{array} \right.$

Hematological Changes in Pregnancy :

Parameters ↑	Parameters ↓	Parameters Unchanged
<ol style="list-style-type: none"> 1. Blood volume (D/t estrogen & aldosterone) 2. Plasma volume (40%) 3. RBC volume (20%) 4. Hb mass (g) 5. Reticulocyte count 6. Plasma protein mass (g) 7. Globulin (TBG, sex hormone binding globulin) 8. Clotting factors (Excluding II & I3) 9. WBC count (15,000 - 25,000) : mostly neutrophils. 10. Inflammatory markers (ESR, CRP) 	<ol style="list-style-type: none"> 1. Hematocrit/PCV : D/t hemodilution. 2. Hb concentration (g/dL) 3. Plasma protein concentration (g/dL) 4. Albumin 5. A : G ratio = 1 : 1 6. Factor II, I3 7. Fibrinolytic activity 8. Protein C & S 9. Antithrombin 10. Platelet count : Benign gestational thrombocytopenia. II. Eosinophils 	<ol style="list-style-type: none"> 1. Bleeding time 2. Clotting time 3. APTT

----- Active space ----- Note :

1. Size of spleen : ↑ by 50%.
2. Size of pituitary : ↑ by 125-135% (Anterior > Posterior).
3. BMR : ↑ by 10-20%.

Anemia in Pregnancy

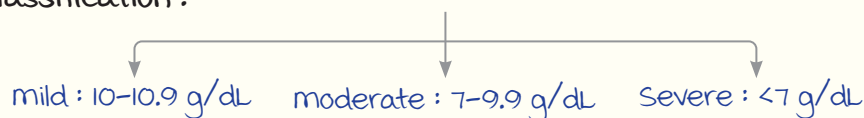
00:08:24

m/c indirect cause of maternal mortality in India.

Causes :

Physiological Anemia	Pathological Anemia
<ul style="list-style-type: none"> • m/c cause of anemia in pregnancy • Normocytic normochromal anemia • Hb : Never falls below 11 g/dL 	<ul style="list-style-type: none"> • m/c cause : Iron Deficiency Anemia (IDA) • microcytic hypochromic anemia • Hb : <11 g/dL

WHO Classification :



Note :

- ICMR → very severe anemia : Hb <4 g/dL.
- microcytic hypochromic anemia → Nestroft test
 - ⊕ → Thalassemia : Rx with iron is C/I.
 - ⊖ → IDA : Rx with iron supplementation.

ANEMIA MUKT BHARAT PROGRAM

Interventions :

1. Digital hemoglobinometer.
 2. IFA pill : Weekly.
 3. Deworming : 400 mg Albendazole twice a year.
 4. Food fortification.
 5. Delayed cord clamping : Prevention of neonatal anemia.
 6. Addressing other causes.
- } For reproductive age females.

Supplementation in Pregnancy :

If pregnancy is planned :

- IFA pill stopped.
- Only folic acid 400 mcg/day taken (To prevent neural tube defects).

Pregnant females :

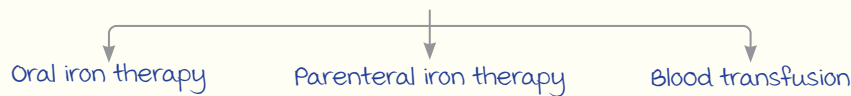
- First 3 months : Folic acid (400 mcg).
- 4th month onwards : IFA pill (RDA of FA in pregnancy : 500 mcg)
 - Dose : 1 tablet/day for at least 180 days in pregnancy.
 - Continued till 180 days after delivery.

Note : To Rx anemia in pregnancy → IFA pill given at time of diagnosis.

Deworming : Once in second trimester.

MANAGEMENT

Treatment modalities :



Oral iron therapy :

- Rate of Hb ↑ : 0.7 g/dL/week after 3rd week.
- For maintenance therapy post parenteral iron therapy (If target Hb = 11 g/dL).
- minimum time gap b/w oral & parenteral iron : 3 weeks (C/I with parenteral therapy).

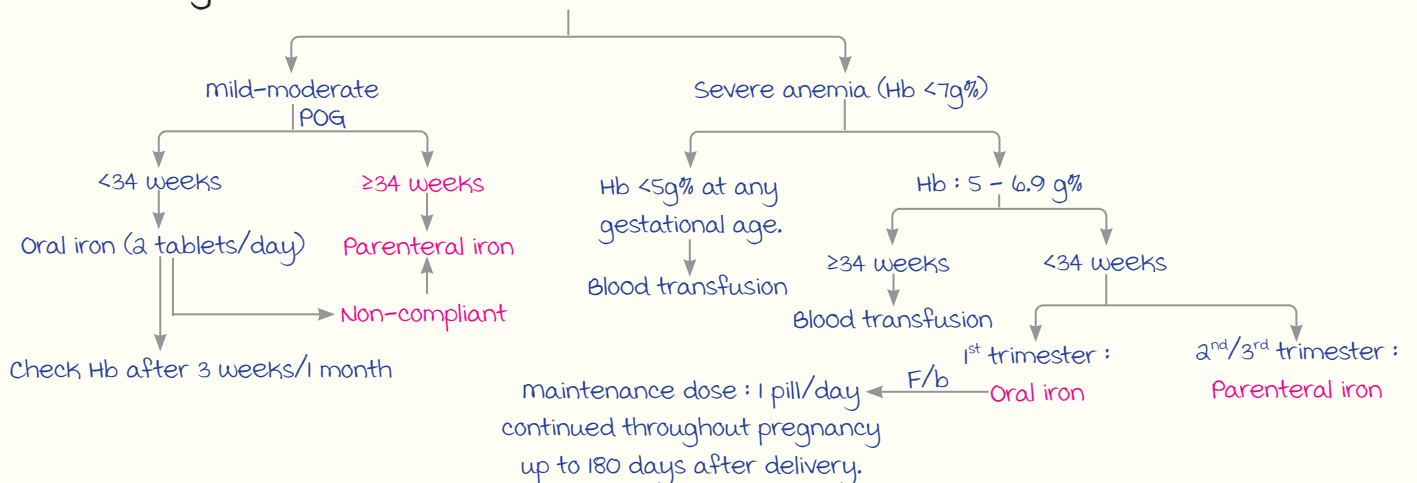
Parenteral iron :

- Rate of Hb ↑ : Same as oral therapy.
- Dose : Ganzoni formula
 - $2.4 \times \text{Pre-pregnancy weight (kg)} \times \text{Hb deficit (Target Hb - Patient's Hb)} + 500 \text{ mg}$
- C/I : 1st trimester.

Blood transfusion indications :

1. Unstable vitals.
2. Signs of heart failure ⊕.
3. Thalassemia.
4. Hb < 5 g/dL at any gestational age.

Treatment Algorithm :



IFA Pill
<ul style="list-style-type: none"> • Red color pill • Fe : 60 mg + Folic acid : 500 mcg (To prevent megaloblastic anemia)
<ul style="list-style-type: none"> • Dose to <ul style="list-style-type: none"> - Prevent anemia : 1 tablet/day - Rx anemia : 2 tablets/day

----- Active space -----

----- Active space -----

Cardiovascular Changes & Heart Disease in Pregnancy

00:21:20

Normal Findings in Pregnancy :

Heart sounds :

- S1 : Loud & prominent splitting.
- S2 : Normal.
- S3 : Easily heard.

Note : Symptoms normal in pregnancy

1. Dyspnea on exertion
2. Easy fatiguability
3. ↓ Exercise tolerance
4. Peripheral dependent edema

Murmurs :

- Ejection systolic murmur (ESM) <3/6 grade.
- Continuous murmur (mammary murmur).

Chest X-ray : mild apparent cardiomegaly.

ECG : Left axis deviation.

Changes in Pregnancy :

Parameters ↑	Parameters ↓	Remain constant
1. Heart rate, pulse rate 2. Stroke volume 3. Femoral venous pressure → ↑ Risk of varicose veins & hemorrhoids } ↑ Cardiac Output (CO)	↓ PVR : • SBP • DBP (maximum ↓ : In TA & supine position) • MAP	1. JVP 2. LVEF

HEART DISEASE IN PREGNANCY

- m/c heart disease in pregnancy : mitral stenosis.
- m/c CHD in pregnancy : ASD.
- Heart disease with maximum maternal mortality : Eisenmenger syndrome.

Indicators of Heart Disease in Pregnancy :

- ↑ JVP.
- S2 : Loud + prominent splitting.
- S4.
- Chest X-ray : marked cardiomegaly.
- Murmurs :
 - ESM ≥3/6 grade.
 - Diastolic murmur (Normally found in 20%).

Symptoms : Chest pain, hemoptysis, PND, orthopnea.

Signs : Clubbing, cyanosis.

----- Active space -----

Cardiac Output in Pregnancy :

- Starts to increase at 5 weeks.
- maximum CO : 28-32 weeks.
- **maximum chance** of heart failure :
Immediate postpartum > 2nd stage of labor > Late 1st stage of labor > 28-32 wks.
- Normalizes within **10 days post delivery**.

management :

- mandatory pain relief.
- **Restrict IV fluid** : 75 mL/hour.
- Semi-recumbent position.
- **AMTSL** :
 - Inj. oxytocin used.
 - **C/I** : Inj. **methyl ergometrine** (D/t tetanic uterine contractions).

Vaginal Delivery :

- Preferred mode of delivery.
- Induction of labor : Not C/I.
- **Prophylactic use of forceps > vacuum** : Shortens 2nd stage of labor.

Indications for C-section :

1. **Aortic** lesions : ↑risk of aortic dissection with vaginal delivery
 - Aortic aneurysm.
 - Aortic regurgitation.
 - In marfan's syndrome.
 - Coarctation of aorta. } (D/t refusal for MTP)
2. Patient on **warfarin**.

Prognosis :

Overall better prognosis : Congenital > Acquired heart disease.

a. Worsens :

- Stenotic lesions.
- Cyanotic HD.
- Pulmonary HTN.

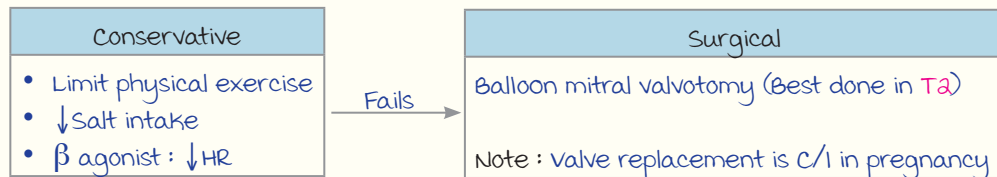
b. Improves :

- Regurgitant lesions.
- Acyanotic HD.

----- Active space -----

Mitral Stenosis in Pregnancy :1st symptom : Exertional dyspnea.

management of Symptomatic Patients :

**C/I for Pregnancy :**

WHO Class IV Pregnancy (Indications for mTP) :

1. Pulmonary HTN : 1^o, 2^o (Eisenmenger).
 2. Severe MS.
 3. Severe AS.
 4. LVEF < 35%.
 5. Marfan syndrome with aortic involvement.
 6. Coarctation of aorta.
 7. NYHA Class 3/4.
 8. Peripartum cardiomyopathy.
 9. Fontan surgery. (Left hypoplastic heart)
- } with residual defects.

PERIPARTUM CARDIOMYOPATHY

Criteria :

- No prior heart disease.
- Heart failure anytime b/w last month of pregnancy up to 5 months after delivery.

Risk Factors :

- ↑ Age.
- multifetal pregnancy.
- Pre-eclampsia.

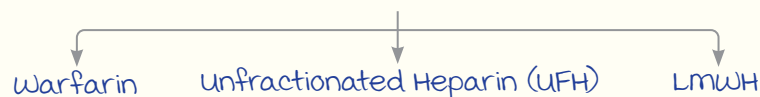Echocardiography (IOC) :

- ↓ LVEF : Diagnostic criteria.
- Dilatation of Lt. ventricle.

management : Heart failure mx + Bromocriptine.

Anticoagulants in Pregnancy

00:35:40



For bioprosthetic valves : Aspirin.


For mechanical valves : Anticoagulant + Aspirin.

DOC per POG :

----- Active space -----

Period of gestation	Anticoagulant of choice
upto 12 wks	Based on preconception dose of warfarin : <ul style="list-style-type: none"> • <5 mg/day → Continue warfarin • ≥5 mg/day → LMWH
12-36 wks	warfarin
At 36 wks	<ul style="list-style-type: none"> • Stop aspirin • Replace warfarin with LMWH
1 week before delivery (Optional)	Switch LMWH → UFH
6h after vaginal delivery/ 6-12h after C-section	Unfractionated heparin + warfarin ↓ INR : 1.5-2 Withdraw UFH + Lifelong warfarin.

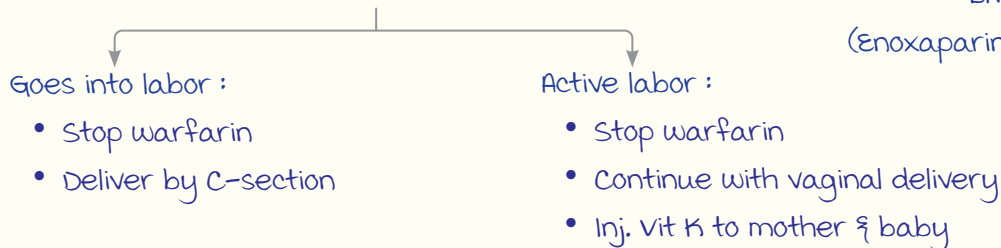
Warfarin in Pregnancy :



Only indication : **mechanical valve replacement.**

Note : Previous h/o DVT - DOC

management of Patient on Warfarin :



↓
LMWH
(Enoxaparin/Dalteparin).

Teratogens

00:42:45

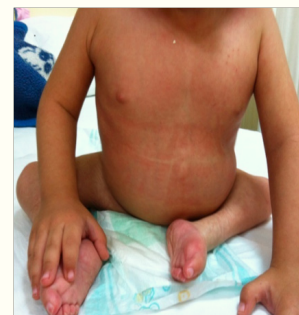most teratogenic period : Embryonic period → ≥2 wks to 8 wks after fertilization. (4-10 wks POG).

I. Pregestational Diabetes

Formation of free radicals ^{Placenta} → Congenital malformations.

Congenital malformations in pregestational diabetes :

- m/c system involved : CVS > CNS.
- m/c congenital malformation : **VSD** > NTD.
- most specific malformation : Caudal regression syndrome/Sacral agenesis.
- most specific cardiac malformation : Transposition of great arteries.
- m/c cardiac lesion : **HOCm.**



Caudal Regression Syndrome

----- Active space -----

Risk Predictor : **HbA1c**

- <6.5% → No additional risk.
- ≥6.5% → ↑ Risk.

Note :
Gestational diabetes → Congenital malformations absent.

Ix :

- Screening : Level 1 USG.
- IOC to detect gross congenital anomalies : **Level 2 USG.**

2. Radiation :

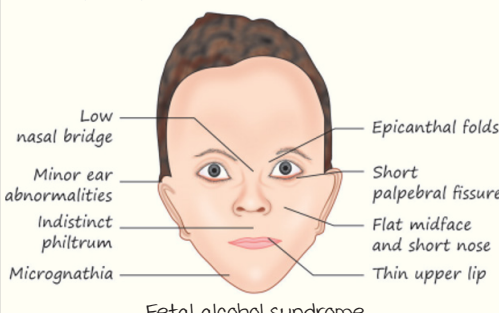
Teratogenic effects :

- Exposure ≥5 rads →
- **microcephaly** (m/c)
 - Growth restriction
 - Neurological impairment
 - Risk of cancer : **Leukemia** (m/c)
 - Fetal dose (≥10 rads exposure)

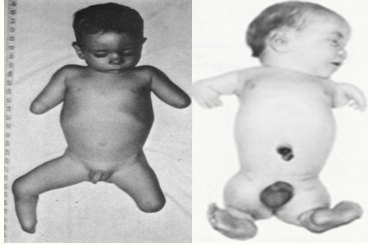


Accidental X-ray in pregnancy : Not an indication for MTP.

All or none law : First 2 weeks after fertilization **Teratogenic exposure** → Abortion
 → Normal fetus (No congenital malformations)

3. Teratogenic Drugs :

Drug	Teratogenicity
<p>1. Alcohol :</p>  <p>Fetal alcohol syndrome</p>	<p>Fetal Alcohol Syndrome (FAS) :</p> <p>mnemonic : Goa's famous beer bar</p> <ul style="list-style-type: none"> • Growth restriction • Abnormal facial features : Smooth philtrum, thin vermilion border, small epicanthal folds • Abnormal brain development, microcephaly • Abnormal behavioral development : Cognitive impairment
2. Phenytoin	<p>Fetal hydantoin syndrome :</p> <ol style="list-style-type: none"> midfacial hypoplasia uprturned nose Distal digital hypoplasia ± cardiac defects
3. ACE inhibitors/ARBs	<ul style="list-style-type: none"> • Oligohydramnios in the 2nd trimester • Renal agenesis
4. Lithium	<ul style="list-style-type: none"> • Ebstein anomaly : <ul style="list-style-type: none"> - Apical displacement of tricuspid valve → Tricuspid regurgitation - Right atrial enlargement • Neonate : Floppy baby syndrome, diabetes insipidus & hypoglycemia

----- Active space -----

Drug	Teratogenicity
5. Isotretinoin	microtia/Anotia
6. Thalidomide	<ul style="list-style-type: none"> • Phocomelia (Proximal limb amputation) • Stillbirth  <p style="text-align: center;">Phocomelia</p>
7. Warfarin :  <p>Depressed nasal bridge</p>  <p>Stippled epiphysis</p>	DisSala syndrome : <ul style="list-style-type: none"> • Chondrodysplasia • Stippled epiphysis • Nasal hypoplasia • CNS : Corpus callosum agenesis, microcephaly • Cataract
8. methotrexate	Craniosynostosis : Clover leaf skull
9. Tamoxifen (SERM) Note : minimum time gap b/w stoppage of tamoxifen and pregnancy : 2 months (Ideal : 3 months)	<ul style="list-style-type: none"> • Similar to DES : <ul style="list-style-type: none"> - Vaginal adenosis - Craniofacial defects - Ambiguous genitalia • mother : Endometrial cancer
10. misoprostol	moebius syndrome : 6 th & 7 th nerve palsy
11. Indomethacin	<ul style="list-style-type: none"> • >32 weeks : Premature closure of ductus arteriosus • Oligohydramnios

Note :

Distal digital hypoplasia/amputation → Phenytoin.
 → Amniotic band syndrome.

Hyperpyrexia in pregnancy →

- microcephaly.
- NTD.
- Intellectual disability.

Teratogenic Infections

00:53:16

Syphilis :



- Follows **Kassowitz Law** : As no. of pregnancies ↑, subsequent pregnancies have better outcomes.
- Not a/w recurrent abortion.

----- Active space ----- A/w :

- Stillbirth.
- Polyhydramnios.
- Hydrops fetalis.
- Fetal anemia.

Varicella Zoster :

Teratogenic period : 12-20 weeks.

Congenital Varicella Syndrome	Neonatal Varicella Syndrome
Indication for MTP	Pregnant female acquires infection 5 days before to 2 days after delivery
<ul style="list-style-type: none"> • microcephaly • Calcifications • Limb hypoplasia & contractures • Cicatricial skin lesions 	<ul style="list-style-type: none"> • Hepatitis • Pneumonia • Skin rash • meningoencephalitis 

Rubella :

Congenital rubella syndrome :

- Cataract, SNHL & heart defects (PDA > Pulmonary stenosis).
- Blueberry rash.
- Indication for MTP.

Zika :

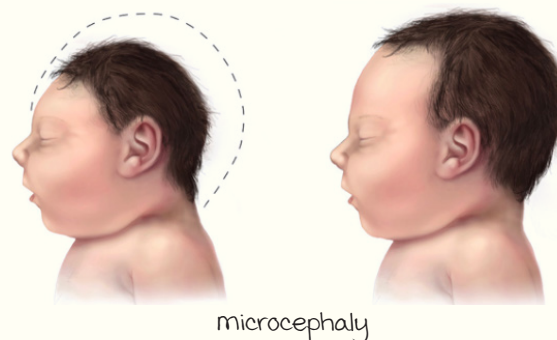
vector borne teratogen (Aedes mosquito).

A/w receptors :

- TIM 1
- TAM-XL

Features (STP) :

- microcephaly.
- ↑Limb tone.
- Club foot.



OBSTETRICS : PART 5

----- Active space -----

Endocrine Changes in Pregnancy

00:00:07

THYROID CHANGES IN PREGNANCY

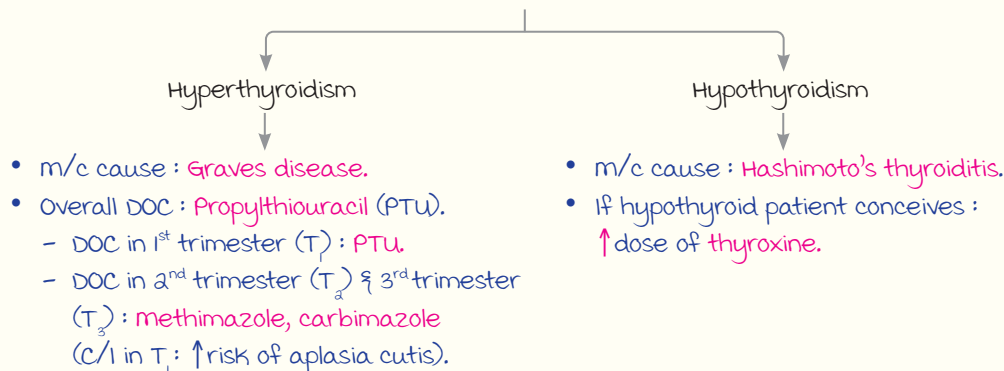
Physiological Changes :

Size of thyroid gland : \uparrow in pregnancy (Goitre : Pathological).

Thyroid profile :

- Total T₃, T₄ : \uparrow (hCG $\xrightarrow{\text{Similar to}}$ α subunit of TSH $\xrightarrow{\text{Stimulates}}$ Thyroid gland).
- Free T₃, T₄ : \textcircled{N} .
- Thyroid binding globulin : \uparrow (D/t estrogen).
- TSH : \textcircled{N} (\textcircled{N} range in pregnancy : 0.1-2.5 mu/L).

Thyroid Disorders in Pregnancy :



Thyroid storm : DOC \rightarrow PTU (Propranolol for symptomatic management).

Note :

- Iodine requirement in pregnancy : 250 mcg/day.
- In pregnancy, size of pituitary gland \rightarrow \uparrow by 125%, & spleen \rightarrow \uparrow by 50%.

Insulin Resistance (IR) in Pregnancy :

- Pregnancy : Diabetogenic state.
- Insulin secretion : \uparrow ; glycosuria : \textcircled{N} .

Hormones causing IR :

- HPL (main) : Detected by 3 weeks POG & maximum by 36 weeks POG.
- Estrogen, progesterone, cortisol (hCG \rightarrow Insulin resistance).

Note : Oncotic pressure \downarrow , Fluid retention of 6.5 litres \rightarrow Physiological edema.

----- Active space -----

Urinary System & Respiratory Changes in Pregnancy

00:04:32

Renal Changes in Pregnancy :

- Size of kidney: ↑ by 1 cm.
- Renal blood flow : ↑, GFR : ↑ → ↓ S. urea, ↓ S. uric acid, ↓ S. creatinine.

Asymptomatic Bacteriuria (ASB) :

- $\geq 10^5$ /mL in urine without any UTI symptoms.
- m/c organism : E. coli.
- Urine R/m (+ culture : If risk factors ⊕) to be done in every trimester to monitor ASB.

Diagnosis :

Type of specimen	No. of samples required	minimum CFU/mL for UTI diagnosis
midstream clean catch urine	2 consecutive samples	$\geq 10^5$ of same bacteria species
Catheterized urine	Single sample	100
Suprapubic aspirate		Any growth of microorganisms in culture

CFU : Colony forming units.

Risk factors : Sickle cell anemia, diabetes.

Complications : Preterm labour, pyelonephritis.

mx : Amoxicillin/Nitrofurantoin (DOC).

RESPIRATORY CHANGES IN PREGNANCY

Transverse diameter of chest	Diaphragm pushed	Chest circumference
↑ by 2 cm	Pushed by 4 cm	↑ by 6 cm

Respiratory Parameters :

Parameters ↑	Unchanged parameters	Parameters ↓
<ul style="list-style-type: none"> • IC : Inspiratory Capacity • T : Tidal volume • mv : minute ventilation 	<ul style="list-style-type: none"> • IRV : Inspiratory Reserve Volume • R : Respiratory rate • V : Vital capacity 	All other respiratory parameters

Diabetes in Pregnancy

00:08:08

----- Active space -----

Pregestational diabetes :

(Priscilla white : Type non-A diabetes)

- Diabetic female conceives.
- Blood sugar levels raised from day 1 of pregnancy.
- Hyperglycemia is **fetotoxic**.
- **Leads to** congenital malformation.
- **Doesn't resolve after delivery.**

Diagnosis of Pregestational Diabetes :

- FBS : ≥ 126 mg/dL.
- RBS : ≥ 200 mg/dL.
- 2-hour PP : ≥ 200 mg/dL.
- HbA1C : ≥ 6.5 %

Gestational Diabetes :

(Priscilla white : Type A diabetes)

- Nondiabetic female conceives but becomes diabetic during pregnancy d/t **insulin resistance**.
- Insulin resistance is d/t **HPL** and increases as pregnancy advances.
- **Significant IR** develops between **24 and 28 weeks of pregnancy**.
- Gestational diabetes develops between **24 and 28 weeks** (Organogenesis is complete).
- **Doesn't lead to** congenital malformation.

DIABETES IN PREGNANCY

Type A diabetes can be

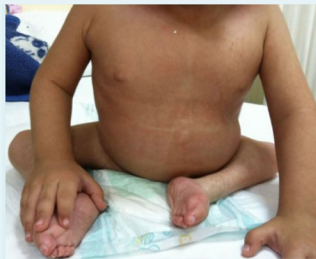- A1 : Gestational diabetes controlled by **diet**.
- A2 : Gestational diabetes controlled on **insulin or OHA**.

Congenital malformation in Diabetes :

m/C system involved : **CVS** > CNS.

m/C congenital malformation : **VSD** > neural tube defect (NTD).

most specific : **Sacral agenesis**/Caudal regression syndrome.



Caudal regression syndrome

m/C CVS anomaly : **VSD**.

most specific CVS anomaly (Does not resolve after delivery) : **Transposition of Great Arteries (TGA)**.

m/C CVS finding (Reversible after delivery) : **Hypertrophic Cardiomyopathy (HOCm)**.

Diagnosis of Gestational Diabetes :

- In India : **DIPSI** guidelines are followed
- Test : **1st** antenatal **visit** + repeated at **24-28 weeks** of pregnancy.
- Fasting : **Not required**.

Procedure :

Give 75 g of glucose in 300 mL of water irrespective of previous meals → To be drunk in 5 minutes.

Result :

- If 2-hour PP < 140 mg/dL : **Repeat** test at 24-28 weeks.
- If 2-hour PP ≥ 140 mg/dL : **Gestational diabetes**.
- If 2-hour PP ≥ 200 mg/dL : **Pregestational diabetes**.

Important points :

- Minimum time gap between 2 tests : **4 weeks**.
- If patient comes for first time after 28 weeks : **Test only once**.

ANTENATAL CARE IN DIABETIC PATIENTS

----- Active space -----

National Guidelines :

1. For congenital malformation :

In pregestational diabetes :

- Do HbA1c (Risk assessment tool).
 - If HbA1c
 - <6.5% : No risk.
 - ≥10% : 15-20% risk.
- Screening of congenital malformation : Level I USG.
- IOC : Level 2 scan/Target/anomaly scan at 18-20 weeks.
- Fetal Echo : 22-24 weeks (To be done).

2. Target scan also done in GDM patients :
Fetal echo not done.

3. In both GDM + pregestational diabetes :

Do 2 growth scans

- 28-30 weeks.
- 34-36 weeks.

(To estimate macrosomia and amniotic fluid).

4. Number of antenatal visits :

- Well controlled GDM/no complications : Routine antenatal visits.
- Not well controlled GDM/complication seen :
 - T_a : Every 2 weeks.
 - T₃ : Every week.

5. Urine R/m and urine culture to be done in : Each trimester as asymptomatic bacteriuria is common in diabetic patients.

6. Begin fetal monitoring at 32 weeks in high risk pregnancy :

- DFMC (Daily fetal movement count).
- NST and BPS (Biophysical score) : weekly.
No need for umbilical artery doppler unless PIH is present.
- Growth scan : Every 3 weeks.

Obstetric management :

Gestational diabetes : Termination of pregnancy

- Well controlled on diet (Type A₁)
 - Type A₂ : Well controlled on insulin/drugs
 - Pregestational well controlled
 - Type A₃ : Not controlled on insulin → 37 weeks.
- 39 weeks

Metabolic Goals in Diabetes :

(MNT or Insulin)

- FBS : <95 mg/dL.
- 1-hour PP : 140 mg/dL.
- 2-hour PP : 120 mg/dL.
- HbA1c : <6%.
- Average capillary glucose : <100.

Medical Nutrition Therapy (MNT) :

Advised to all pregestational & GDM patients.

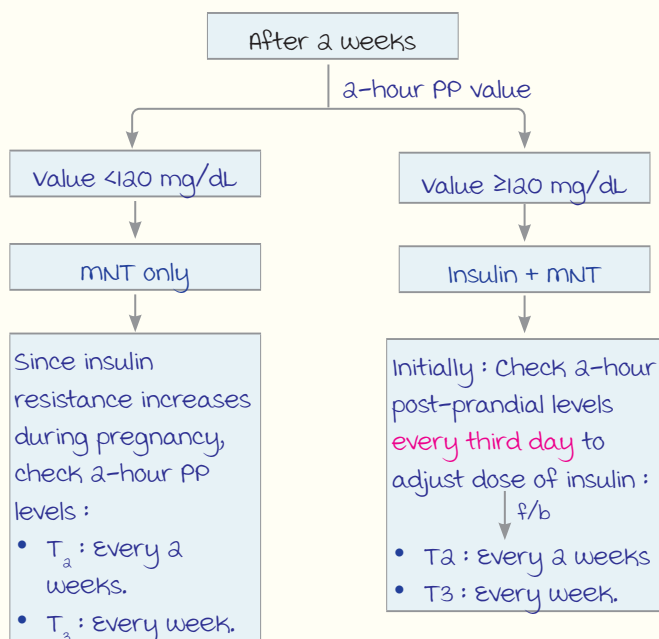
- Carbohydrate : 40%.
- Fat : 40% (Saturated fat <10%).
- Protein : 20%.

Insulin :

- DOC for diabetes in pregnancy.
- Route : Subcutaneous.
- m/c used : Human premix insulin.
- vial : 40 IU/mL.
- Maximum times syringe can be used : 14 times.
- Stored at 4°-8°C (In fridge).

Management of Gestational Diabetes :

Give medical nutrition therapy (Diet modification) alone for 2 weeks.



MANAGEMENT OF PREGESTATIONAL DIABETES :

----- Active space -----

- When a diabetic patient conceives : Put patient on **insulin** (Stop OHA) + **start medical nutrition therapy** + give **aspirin** (To prevent PIH).
- OHA are **C/I in pregnancy** :
 - In case of gestational diabetes : If patient refuses insulin + **metformin/ glyburide** may be given but **not in pregestational** diabetics.

COMPLICATIONS OF DIABETES

maternal	Fetal (ⓈⓉ)	Neonatal (↑ insulin in neonates)
<ul style="list-style-type: none"> • ↑ chances of infection : Asymptomatic bacteriuria, candidiasis. • Placentomegaly can cause PIH/polyhydramnios • Polyhydramnios can cause : <ul style="list-style-type: none"> - PPH. - Abruptio placenta. - PROM. - PTL. - Cord prolapse. - malpresentation. • Risk of developing diabetes in future : 30-50%. 	<p style="text-align: center;">Fetal pancreas → ↑ insulin → ↑ Growth (No role of GH)</p> <ul style="list-style-type: none"> • Fetal hyperglycemia • macrosomia ← ↑ chances • Shoulder dystocia. • ↑ chances of abortion, IUD, still-birth. • If there is diabetic vasculopathy or DM + PIH : Patient may have oligohydramnios and IUGR. 	<ul style="list-style-type: none"> • Neonatal hypoglycemia. • Hypocalcemia. • Hypokalemia. • Hypomagnesemia. • Respiratory distress syndrome. • Necrotising enterocolitis. • Hyperviscosity syndrome a/w : hyperbilirubinemia + polycythemia. <div style="border: 1px solid black; padding: 5px; margin-top: 10px;"> <p>Note :</p> <p>Never seen in babies of diabetic mothers :</p> <ul style="list-style-type: none"> • Anemia. • mental retardation. </div>

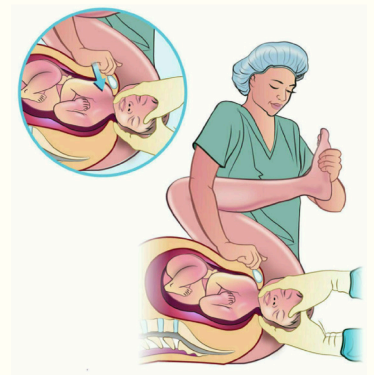
Shoulder Dystocia :

- Delay in delivery of shoulder by **≥1 minute** after delivery of fetal head.
- It is an **obstetric emergency**.
- Sign : **Turtle sign** (Head tries to retract against perineum).

Algorithm for management of shoulder dystocia :

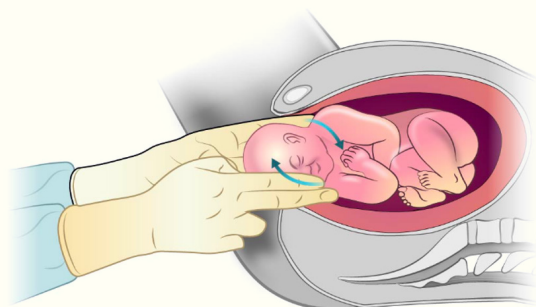
mnemonic : **HELPERR**

- **H** : Call for help.
- **E** : Give liberal episiotomy.
- **L** : Legs maneuver (AKA **McRoberts maneuver**)
 - Flex the thighs and abduct them.
 - It leads to straightening of sacrum and increases available space.
- **P** : Suprapubic pressure.
- **E** : Enter the hand → Rotate shoulders of baby (Woods corkscrew maneuver).
- **R** : Remove (Deliver) the posterior arm of baby.
- **R** : Roll the patients on all 4 limbs (AKA All four maneuver/Gaskin maneuver).

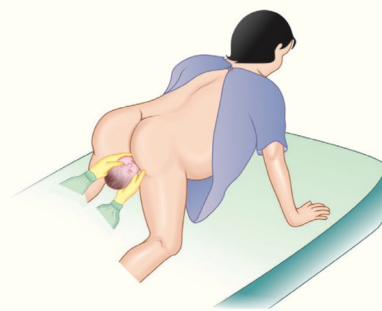


McRobert maneuver

----- Active space -----



woods corkscrew maneuver



All four maneuver

Note : m/c nerve injured during mcRobert maneuver → Lateral cutaneous nerve of thigh.

C/I in shoulder dystocia : Fundal pressure.

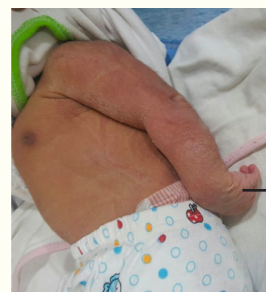Last step if everything fails : Zavanelli maneuver.

m/c fetal complication in shoulder dystocia :

Erb's palsy (Nerve roots : C5, C6)

m/c maternal complication in shoulder dystocia :

Post partum Hemorrhage (PPH).



Policeman tip hand

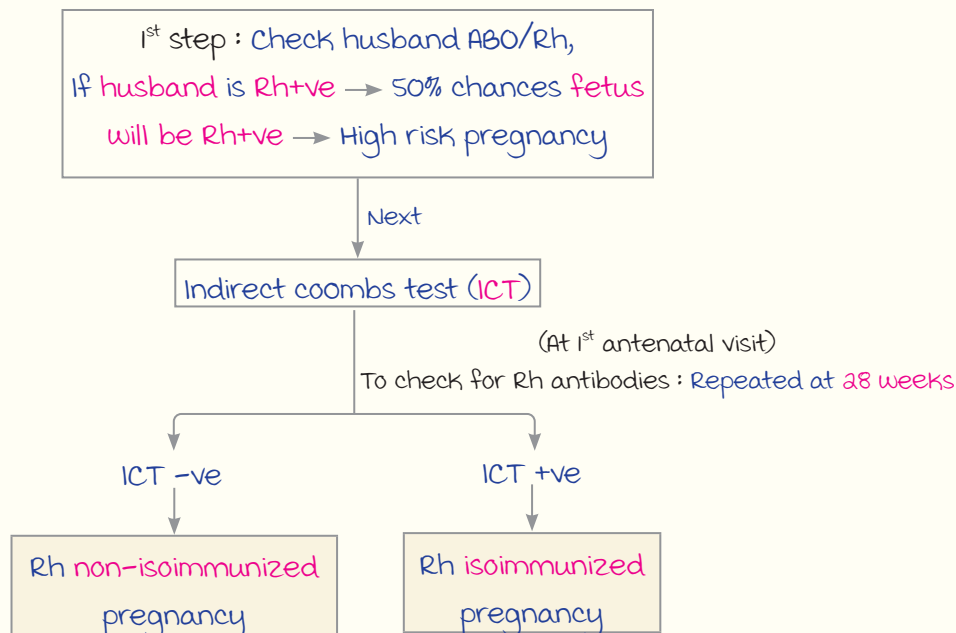
Erb's palsy

Rh Negative Pregnancy

00:30:28

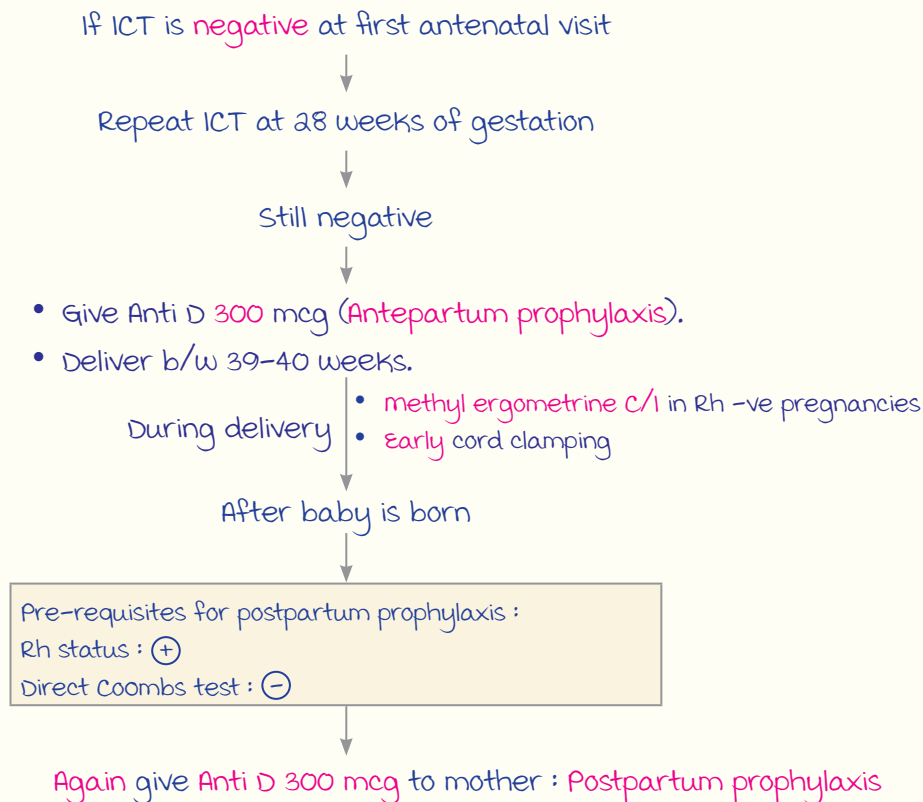
mother : Rh-ve, Fetus : Rh +ve

Rh-ve female 1st antenatal visit work up :



MANAGEMENT OF RH NONIMMUNIZED PREGNANCY

----- Active space -----



Anti D :

Antepartum prophylaxis :

- To Rh-ve pregnant female if ICT ⊖ is at 28 weeks.
- To protect current pregnancy.
- Dose : 300 mcg.

Postpartum prophylaxis :

- Within : 72 hours (Ideal) - 28 days post delivery (maximum).
- Done to protect future pregnancies.

Other indications for anti D :

1 st trimester	2 nd and 3 rd trimester
<ul style="list-style-type: none"> • Abortion • Ectopic pregnancy • molar pregnancy • mTP • Chorionic villus sampling 	<ul style="list-style-type: none"> • Trauma • APH • Amniocentesis • ECV (External cephalic version) • manual removal of placenta • Fetal death
Dose : 50 mcg	Dose : 300 mcg (1500 IU)

Note: Anti D is not given after **cordocentesis**

----- Active space -----

MANAGEMENT OF RH ISOIMMUNIZED PREGNANCY

If ICT is +ve either at first antenatal visit or at 28 weeks, such pregnancy is called **Rh Isoimmunized pregnancy**

Next step

Assessment of antibody titre

Critical titre = 1:16

Titre \geq 1:16 (1:16, 1:32, 1:64)

Next step

Check Peak systolic velocity (PSV) of middle cerebral artery (MCA)

\geq 1.5 mOm (Fetal anemia)

Next step

Cordocentesis/Per-umbilical blood sampling (PUBS) : Only indication
 → To know **exact hematocrit** in Rh isoimmunized pregnancy

Fetal blood taken from umbilical vein

Hematocrit : $<$ 30%

\geq 35 weeks POG

$<$ 35 weeks POG

Termination of pregnancy Intra-uterine blood transfusion

Titre $<$ 1:16 (1:2, 1:4, 1:8) :

- Repeat titre every : **4 weeks.**
- Fetal monitoring begins : At **32 weeks.**
- Delivery :
 - B/w **37-38 weeks.**
 - methyl ergometrine c/i.
 - **Delayed** cord clamping.

\leq 1.5 mOm (Fetal anemia **absent**) :

- Repeat MCA Doppler : Every **2-4 weeks.**
- Fetal monitoring begin : At **32 weeks.**
- Delivery : **37-38 weeks.**

Hematocrit : \geq 30%

- Repeat Hb and hematocrit **weekly**
 - MCA Doppler : **1 - 2 weekly**
 - Fetal monitoring : From **32 weeks**
- Deliver : **37 - 38 weeks**

Delivery in Rh-ve, pregnancy :

- mode of delivery in Rh negative pregnancy : **vaginal.**
- In Rh negative pregnancy : **Early cord clamping** done.
 - If indirect Coombs test +ve in Rh negative pregnancy : Do **delayed cord clamping.**
 - If ICT is -ve : Do **early** cord clamping.

Anti-D :

- Test done to calculate dose of Anti D : **Kleihauer - Betke test.**
- Reagent : **Citric acid phosphate buffer.**
- 300 mcg of Anti D can neutralize **30 mL** of fetomaternal hemorrhage (Abruptio, maternal trauma)/**15 mL** of fetal RBCs.

Hydrops fetalis (HF) :

It is an USG diagnosis :

- | | | |
|--------------------------|--|----------------------|
| 1. Pericardial effusion. | } Presence of \geq 2
or
Anasarca + any 1 | } → Hydrops ⊕ |
| 2. Ascites. | | |
| 3. Pleural effusion. | | |

Note : Placentomegaly and polyhydramnios are seen in hydrops but are not included in diagnostic criteria.

Causes :

- Immune HF : **Rh negative pregnancy (m/c)**, ABO incompatibility.
- Nonimmune HF : **CVS disease (m/c)**, chromosomal disorders, parvovirus infection.

Note (97):

----- Active space -----

- Supine hypotension syndrome :
 - Gravid uterus → ↓ venous return → ↓ Cardiac output → ↓ BP, fetal distress.
press on IVC
 - mx : Lie on left lateral position.
- IADPSG/ADA criteria for gestational diabetes :
 - Test done b/w 24-28 weeks of pregnancy.
 - 8 hours of fasting needed → FBS taken → 75g of oral glucose in water
↓
Blood levels checked after 1 hour & 2 hours.
 - Diagnosis : If ≥ 1 value is abnormal, then GDM is diagnosed.

Sample	Upper normal glucose level (mg/dL)
FBS	92
1 hour sample	180
2 hours sample	152

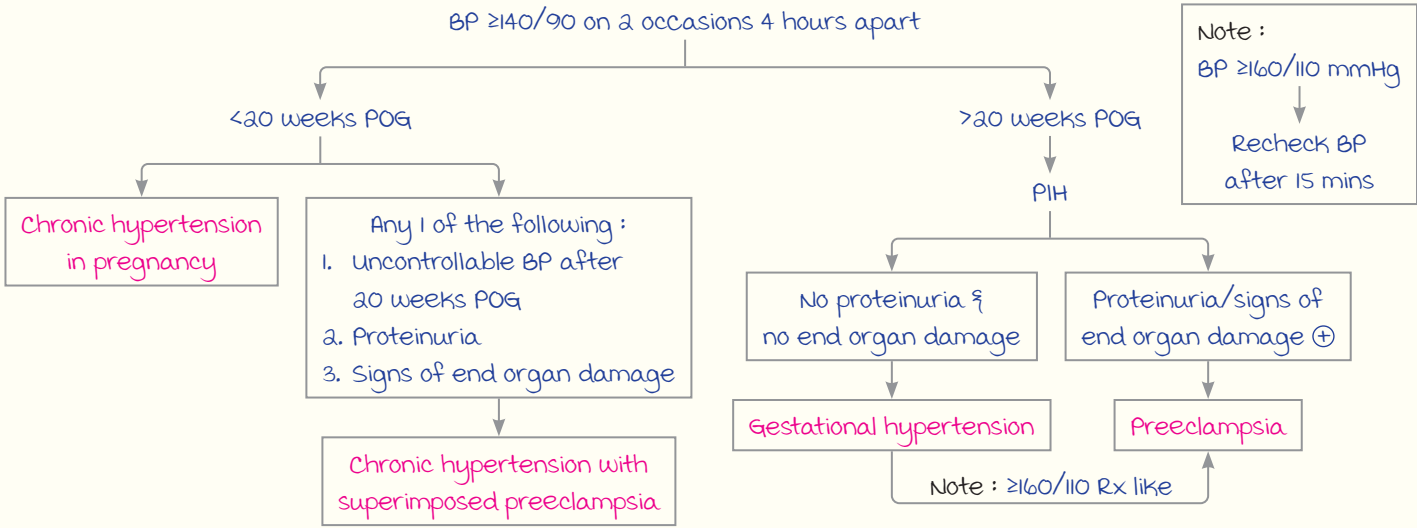
OBSTETRICS : PART 6

----- Active space -----

Pregnancy Induced Hypertension (PIH)

00:00:20

Definitions :



Proteinuria :

Any 1 of the following :

- Excretion of ≥ 300 mg of protein in 24 hours.
- Protein : Creatinine ratio ≥ 0.3 .
- Dipstick $\geq 1+$.

Signs of End Organ Damage :

Any 1 of the following :

- Platelet count ≤ 1 lakh.
- Liver enzymes ≥ 2 times \uparrow .
- S. creatinine ≥ 1.1
- Pulmonary edema.
- Cerebral edema/visual disturbances/severe headache.

Screening test : urine dipstick.

Gold standard : 24 hr urine sampling.

Pre-eclampsia :

Differentiating features	mild pre-eclampsia	Severe pre-eclampsia
1. BP criteria	$\geq 140/90$ & $< 160/110$ mmHg	$\geq 160/110$ mmHg
2. Signs of end organ damage	Absent	Present
3. Symptoms of impending eclampsia	Absent	Present

Signs & symptoms of impending eclampsia :

- Severe headache.
- Visual disturbances.
- Epigastric pain.
- Clonus.

----- Active space -----

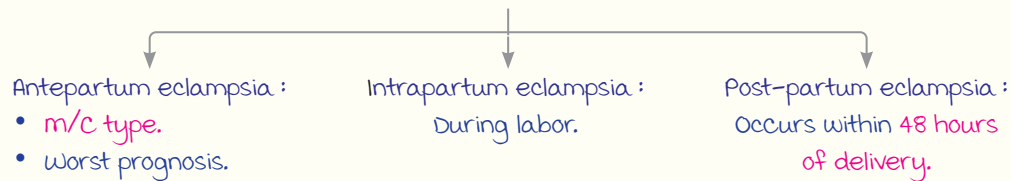
Non-differentiating features :

1. Proteinuria.
2. Oliguria.
3. IUGR.

Eclampsia :

Occurrence of generalized tonic clonic seizures in a patient of severe preeclampsia.

Types :



Risk Factors & Prevention of PIH

00:06:36

RISK FACTORS (57)

1. Female exposed to placenta for first time :
 - Primigravida.
 - New paternity.
 - Long interpregnancy interval.
2. Placental tissue increased :
 - Twin pregnancy.
 - Diabetic patient.
 - Rh negative pregnancy.
 - molar pregnancy.
3. Autoimmune disease :
 - APLA.
4. Patient's details :
 - Pregnancy <18 years/≥40 years.
 - Obesity.
 - Calcium deficiency.
5. Previous H/O :
 - In vitro fertilization.
 - Chronic HTN.
 - PIH.

Note : Smoking → Protective factor against PIH.

----- Active space -----

Prevention of PIH :

Prophylactic aspirin :

Give low dose aspirin :

- Start at 12 weeks
(Not later than 16 weeks).
- End at 36 weeks.
- Dose : 75-100 mg/day

ACOG recommendation for prophylactic aspirin

1. APLA syndrome.
2. Chronic HTN.
3. Multifetal pregnancy.
4. Kidney disease.
5. Diabetes.

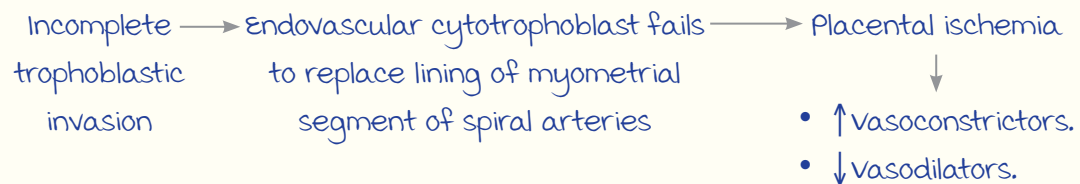
mnemonic : All hypertensive mothers can die.

Other measures :

Proven role	No proven role
<ul style="list-style-type: none"> • Aspirin (Low dose) • Weight loss • Calcium supplements (useful only in calcium deficiency) 	<ul style="list-style-type: none"> • Antioxidants • Fish oil • Vitamin E • Absolute bed rest • Salt restriction

Pathophysiology of PIH

00:09:54

**Predictors for PIH :**

Increased vasoconstrictor	Decreased vasodilators
<ul style="list-style-type: none"> • SFLT (Soluble Fms like tyrosine kinase) • S. Endoglin • ILs, TNF α • Thromboxane A₂ • ↑ Sensitivity to angiotensin II • Cytokine • Lipid peroxidase 	<ul style="list-style-type: none"> • VEGF • Placental growth factor • NO • Prostacyclin I_a • ↓ Activity of angiotensinase enzyme

Note :

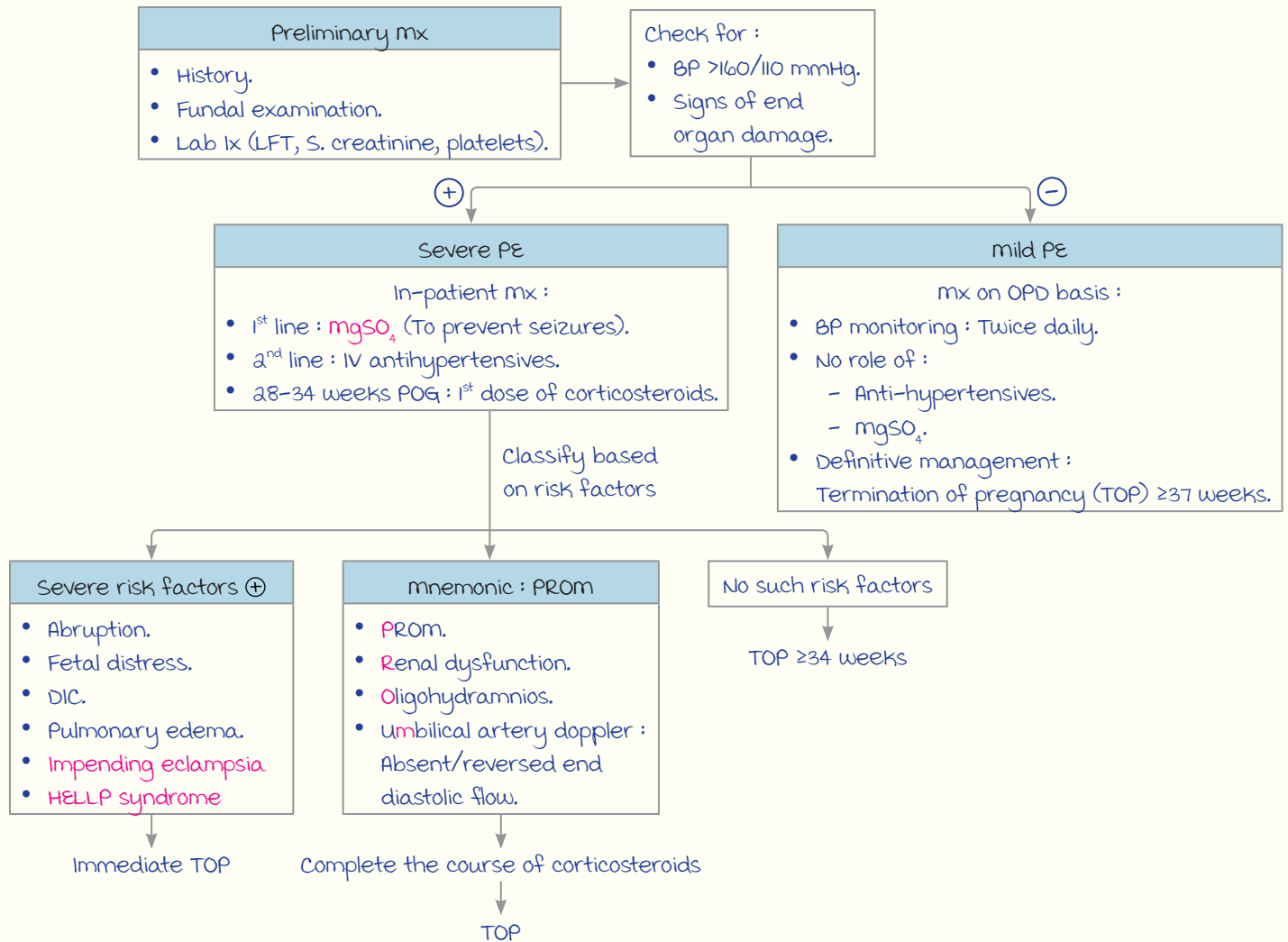
maternal NK cells : Play a role in trophoblastic invasion.

Management of PIH

00:12:56

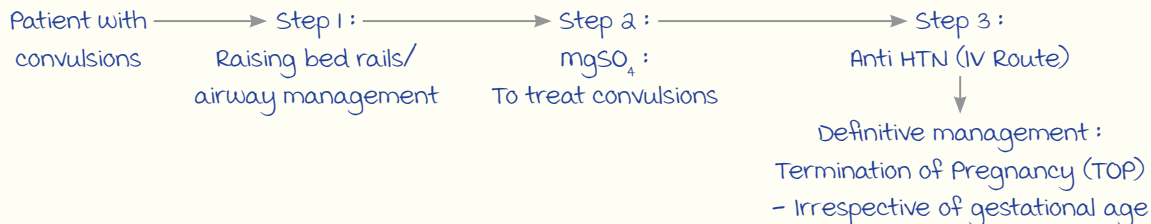----- Active space -----

All patients with PIH should be admitted.



Note : No role of aspirin, salt restriction or bed rest in Rx of PIH.

Eclampsia :



mode of delivery : vaginal delivery.

Anaesthesia : General anaesthesia (Neuraxial > epidural).

----- Active space -----

Antihypertensives in Pregnancy

00:18:40

Indications :

- BP $\geq 160/110$ mmHg (Even on single occasion).
- NICE guidelines : BP persistently $\geq 150/100$ mmHg.

Anti-hypertensives for		
Severe PE	Chronic hypertension	Refractory hypertension
<ul style="list-style-type: none"> • Labetalol IV - max. dose : 220 mg. • Hydralazine IV. • Oral nifedipine. <p>Note : α-methyldopa (Slow acting) not used as 1st line for severe PE.</p>	<p>1st line (Oral route) :</p> <ul style="list-style-type: none"> • α methyldopa. • Labetalol. • Nifedipine. <p>Note : Hydralazine is not used.</p>	<p>Nitroprusside</p> <ul style="list-style-type: none"> • S/E : Cyanide poisoning.

Contraindicated Antihypertensives :

- ACE inhibitors.
- ARBs (Eg : Losartan).
- Diazoxide.
- Diuretics : Not absolutely C/I.
 - C/I in PE.
 - Can be used in chronic HTN (Not 1st line and should be used before 20 wks).

Magnesium Sulphate

00:20:46

DOC : Prevention & treatment of seizure in a hypertensive pregnant female.

MOA : Centrally acting drug (Not an antihypertensive).

Therapeutic range : 4 to 7 mEq/L.

Pritchard's Regime (97) :

Loading dose :

- IM : 10g of 50% MgSO_4 (5g in each buttock) \rightarrow 10 ampoules.
- IV : 4g of 20% MgSO_4 \rightarrow 4 ampoules.

Preparation of dose	1 ampoule of MgSO_4 : 2 mL of MgSO_4 = 1g of MgSO_4 (50% solution of MgSO_4)
IV dose preparation	<p>In 20 mL syringe : 4 ampoules of MgSO_4 + Add 12mL NS</p> <p style="text-align: center;">↓</p> <p>20 mL solution : 4g of MgSO_4 (~20% concentration)</p>

Note :

- For loading dose : Renal function is not checked (Given irrespective of renal status).
- While giving IV, monitor maternal HR.

Maintenance dose :

- 1m : 5 gm 50% solution every 4 hourly in alternate buttocks.
- To be given till : 24 hrs after delivery
or
24 hrs after last convulsion } whichever is later.
- Before giving maintenance dose check for :
 1. Deep tendon reflex/knee jerk (+)
 2. Respiratory rate ≥ 12 /minute
 3. Urine output ≥ 100 cc/4 hours
 } Given only if all 3 (+)

Note :

$MgSO_4$: Can lead to \downarrow variability on CTG.

SIGNS AND SYMPTOMS OF $MgSO_4$ TOXICITY (57?)

≥ 10 mEq/L : Loss of knee jerk (1st sign), diaphoresis & slurring of speech.

≥ 12 mEq/L : Respiratory paralysis.

≥ 15 mEq/L : Cardiac conduction defects.

≥ 24 mEq/L : Cardiac arrest.

Role of Doppler in PIH

00:24:52

UTERINE ARTERY DOPPLER

- Predicts PIH.
- Done b/w 22-24 weeks POG.

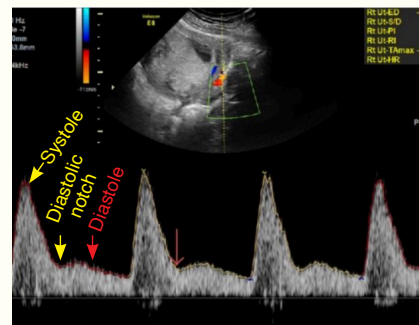
\uparrow Risk of PIH :

1. Persistence of diastolic notch > 24 weeks POG.
2. \uparrow Pulsatility index :

Detected by doppler at 11-13 weeks



Helps diagnose early onset pre-eclampsia



Diastolic notch

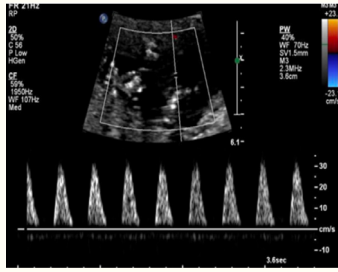
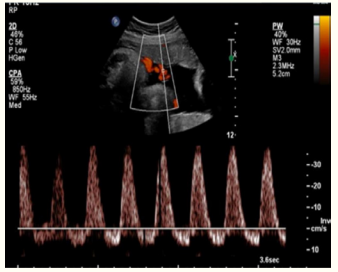
(N) : Disappears by 24 weeks POG

Indications : PIH, uteroplacental insufficiency, IUGR.

SD ratio :

- Normal : ≥ 3 .
- PIH : $< 3 \rightarrow$ mild PIH \rightarrow TOP ≥ 37 weeks.

----- Active space ----- **Abnormal waveforms :**

	Absent end diastolic flow (AEDF)	Reverse end diastolic flow (REDF)
Uterine artery (UA) Doppler		
TOP	33-34 weeks	31-32 weeks

POG <33 weeks :

1. Admit pt.
2. Corticosteroids.
3. NST : Daily/twice daily.
4. UA doppler : 2-3 times a week.
5. USG for fetal growth.

IUGR

00:29:40

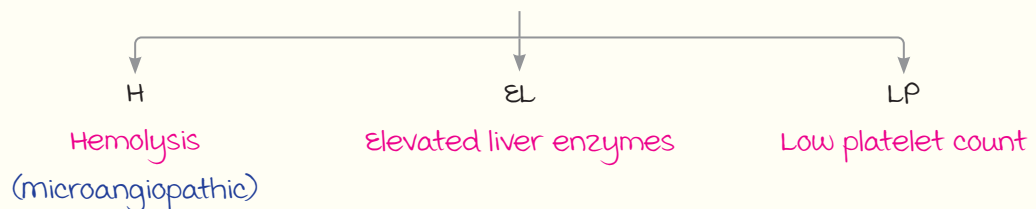
	Small for gestational age	very small for gestational age	Oligohydramnios ⊕
Estimated fetal weight	3-9%	<3%	⊖
TOP	38-39 weeks	37 weeks	36-37 weeks

Indices (57) :

- ↑ Pulsatility index : $\frac{\text{Peak systolic velocity (PSV)} - \text{End diastolic velocity (EDV)}}{\text{Avg. velocity}}$
- ↑ Resistance index.

HELLP Syndrome

00:31:20



All 3 must be present for diagnosis.

Symptom : Present with c/o pain abdomen in T3.

Tennessee Criteria for Diagnosis :

----- Active space -----

Hemolysis : Any 2 of the following should be present.

- P/S : Schistocytes.
- ↑LDH levels.
- ↑S. Bilirubin ≥ 1.2 mg/dL.
- ↓Haptoglobin levels.
- Severe anemia unrelated to blood loss.

Elevated liver enzymes :

Raised SGOT/SGPT : 2 times that of normal value (Normal : 30-35 IU).

Low platelet count : < 1 lakh/ mm^3 .

Note :

- PIH : m/c in primigravida.
- HELLP syndrome : m/c in multigravida.
- BP is not a criteria for diagnosis.

management :Initial : mgSO_4 (To prevent seizures) + antihypertensive drugs.Definitive : 1st dose of corticosteroid (If < 34 wks POG) \rightarrow Immediate TOP.**Twin Pregnancy**

00:33:35

Dizygotic Twins :

- Dichorionic diamniotic (DCDA) : m/c type.
- Better prognosis.

Factors determining incidence :

- Geographical distribution.
- maternal family h/o twinning.
- ↑maternal age & ↑parity.
- IVF & ovulation induction drugs (Clomiphene citrate, hMG).

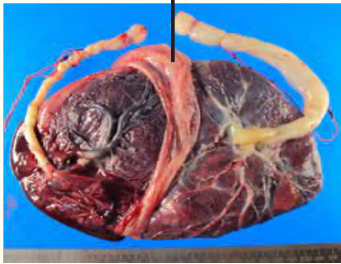
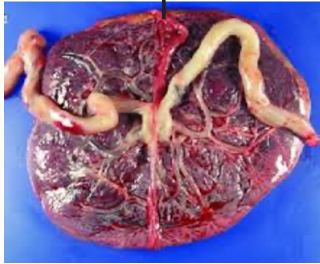
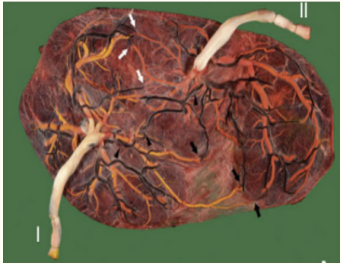
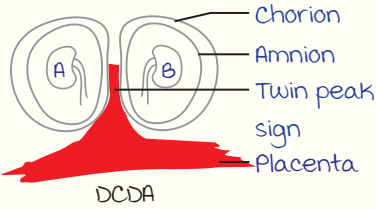
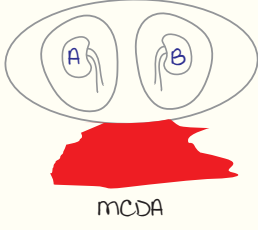
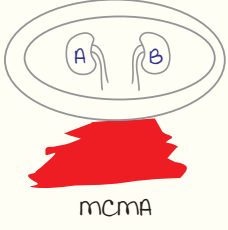


monozygotic Twins :

- Same : Sex, Karyotype, HLA type & blood group.
- Different fingerprints.
- Incidence : 1 in 250 pregnancies (Constant throughout the world).

Type based on division :

- < 4 days (morula) : DCDA.
- 4-8 days (Blastocyst) : mCDA (m/c).
- 9-12 days : mCMA.
- > 12 days : Conjoint twins
 - \rightarrow m/c : Paraphagus $>$ thoracophagus.
 - \rightarrow L/c : Rachipagus $>$ craniophagus.

----- Active space ----- DCDA vs MCDA vs MCMA :

	Dichorionic diamniotic	monochorionic diamniotic	monochorionic monoamniotic
No of layers between the twins	4	2	0
Thickness of membrane	<p>≥ 2 mm</p> 	<p>< 2 mm</p> 	<p>-</p> 
Vascular connections between twins	-	Deep vascular connections	Superficial vascular connections
Sex	Same/different	Same	Same
Number of placenta	<p>2 placenta/appear as a single placenta.</p>  <p>DCDA</p>	<p>Single placenta</p>  <p>MCDA</p>	<p>Single placenta</p>  <p>MCMA</p>
TVS : <ul style="list-style-type: none"> • IOC for chorionicity • Done at 10-14 weeks POG 	<p>Twin peak / Lambda sign (Placenta in between chorion)</p>  <p>LAMBDA/TWIN PEAK</p>	<p>Twin peak sign absent for both.</p> <p>T sign : Single chorion with no intervening placenta</p> 	-
	Prognosis (Depends on chorionicity)	Good	Bad
Specific complication	-	Twin to twin transfusion syndrome (D/t deep vascular connections)	Cord entanglement, conjoined twins
Delivery	38 weeks	34-37 weeks	32-34 wks : C-section after corticosteroid injection

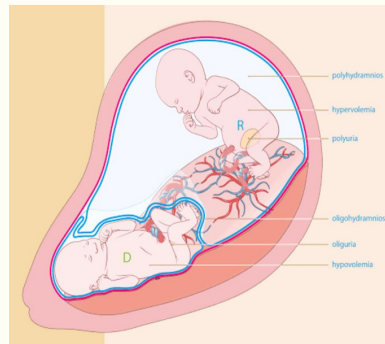
Complications of Twin Pregnancy :

Complications specific to monochorionic twins :

1. TTTS (Twin to twin transfusion syndrome).
2. TAPS (Twin anemia polycythemia sequence).
3. TRAP (Twin reversed arterial perfusion).
4. Selective IUGR.

Complications specific to monoamniotic twins:

1. Conjoint twins.
2. Cord entanglement.



TTTS

----- Active space -----

TTTS & TRAP

00:43:44

TTTS

Occurs d/t deep arterio-venous anastomoses.

Criteria for diagnosis :

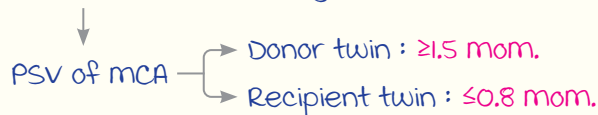
1. MCDA
2. USG → Donor twin : Oligohydramnios.
Recipient twin : Polyhydramnios.

Complications :

Donor twin	Recipient twin
<ul style="list-style-type: none"> • Oligohydramnios • Anemia • Renal failure • Growth restriction • Heart failure 	<ul style="list-style-type: none"> • Polyhydramnios • Thrombosis • Polycythemia • Congestive heart failure (m/c) : Fetal echo to be done • Hydrops

Quintero Staging for TTTS :


- Stage 3 : Abnormal doppler study



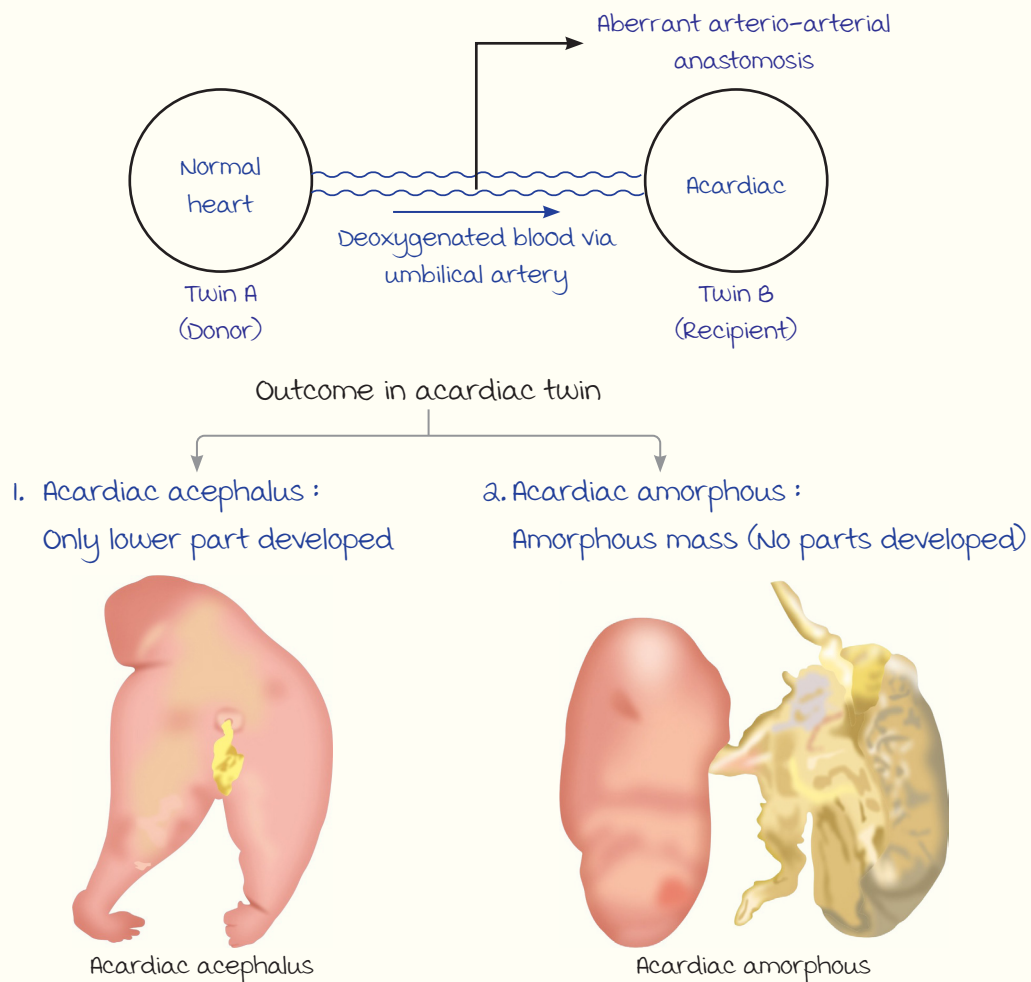
- Stage 4: Hydrops fetalis.
- Stage 5 : Fetal death.

Prognosis : Depends on recipient twin.

----- Active space -----

Management :**TRAP**

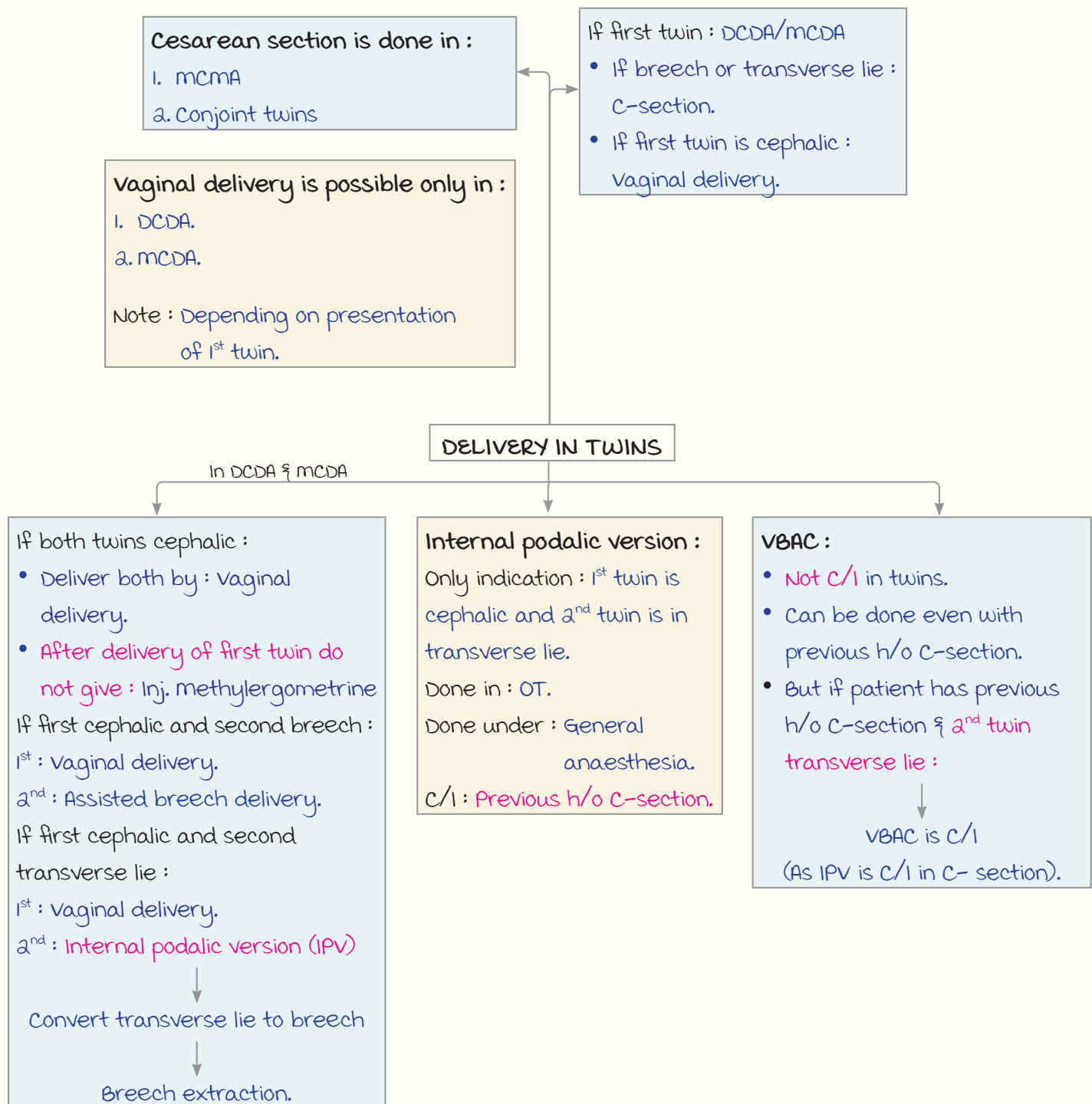
Pathophysiology :



Delivery in Twins

00:48:20

----- Active space -----



AMTSL in twin delivery :

- Inj. methergine C/I.
- Inj. Oxytocin given.

m/c fetal complication : Prematurity/preterm labour.

Cerclage : C/I.

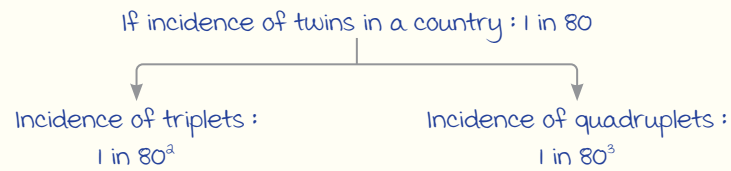
Progesterone : Not useful.

----- Active space -----

Special Features of Twin Pregnancy

00:52:12

Hellin's Rule :



Superfecundation vs Superfetation (97%) :

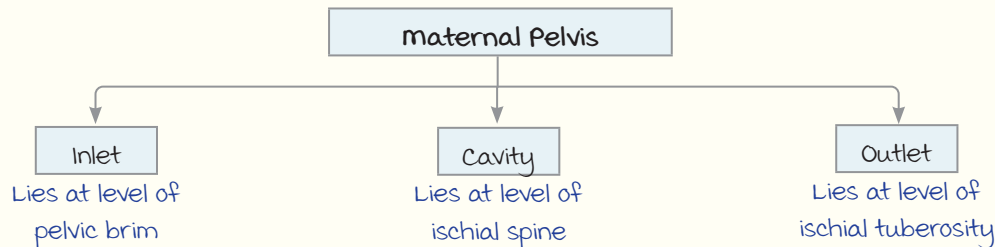
Superfecundation	Superfetation
<ul style="list-style-type: none"> Both ova released in same cycle <p style="text-align: center;">↓</p> <p>Fertilized at a different times by a different acts of coitus</p>	<ul style="list-style-type: none"> 2 ova released & fertilized in a different cycles
<ul style="list-style-type: none"> Rare (Can be seen in humans) 	<ul style="list-style-type: none"> Not seen in humans (Theoretically possible till uterine cavity not obliterated : 14-16 weeks)

OBSTETRICS : PART 7

----- Active space -----

Maternal Pelvis

00:00:28



Important Diameters of Inlet :

1. AP diameter :
 - True conjugate : Distance between sacral promontory (SP) and upper border of pubic symphysis : **11 cm**.
 - Obstetric conjugate (OC) : Distance between SP and mid of pubic symphysis : 10.5 cm.
 - Diagonal conjugate : Distance between SP and lower border of pubic symphysis : 12 cm.
2. Transverse diameter : **13 cm**.
3. Oblique diameter (Right and left) : Oblique diameter is distance between sacroiliac joint of one side to other side Ilio pectineal eminence : 12 cm.

Cavity :

Two important planes :

1. Plane of greatest pelvic dimension :
 - Anterior : Posterior surface of pubic symphysis.
 - Posterior : Junction of S2-S3.
 - Lateral : Obturator foramen.
 - All diameters are : 12 cm.
 - It doesn't have any obstetric significance
2. Plane of least pelvic dimension :
 - Anterior : Lower border of pubic symphysis.
 - Posterior : Junction of S4-S5.
 - Laterally : Ischial spine.
 - Narrowest plane of pelvis.
 - AP diameter : 11.5-12 cm.
 - Transverse diameter** (Interischial diameter/ Bispinous diameter) : **10cm** (Smallest in pelvis).

midpelvis (PQ) :

Area b/w plane of greatest pelvic dimensions and least pelvic dimensions.

Anatomical outlet

- Ant : Lower border of pubic symphysis.
- Post : Tip of coccyx.
- Lateral : Ischial tuberosity.

Diameters :

AP diameter : **13 cm**.

Transverse diameter : **11 cm**.

(Distance between 2 ischial tuberosities : Bituberous diameter).

Obstetric outlet

Space b/w plane of least pelvic dimensions and anatomical outlet.

Imp PQ's (PQ) :

- AP diameter of inlet which can be clinically measured : **Diagonal conjugate**.
- Critical obstetric conjugate : That value of OC below which vaginal delivery is not possible : **<10 cm**
- If diagonal conjugate is x cm : Obstetric conjugate is **x-1.5 cm**.
- Overall most imp diameter for labor : **Inter-ischial diameter**.
- Angle of inclination : **55°**.
- Sub pubic angle is :
 - Angle b/w descending ramus of pubic bone.
 - male → **Acute**, Female → **Obtuse**.

----- Active space -----

Contracted Pelvis :

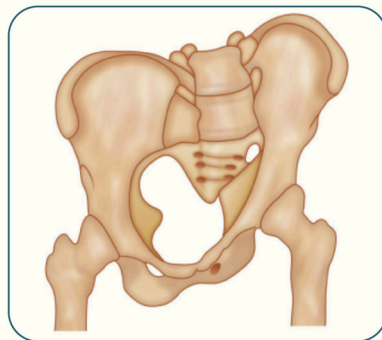
If any of major diameters of pelvis is decreased by 1 cm or if :

- Obstetric conjugate : <10 cm → Contracted inlet.
- Interischial diameter : <8 cm → Contracted midpelvis.
- Bituberous diameter : <8 cm → Contracted outlet.
- mx. of contracted pelvis : Always **cesarean section**.

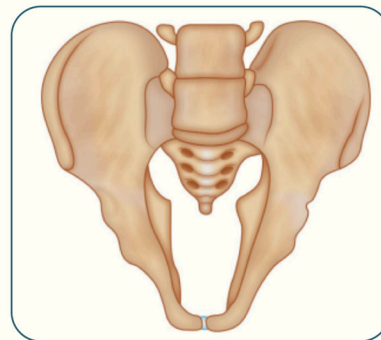
Naegele's pelvis : Only **one Ala** is present, i.e., one Ala of sacral bone is absent.

Robert pelvis : **Both Ala** are absent.

} varieties of contracted pelvis.







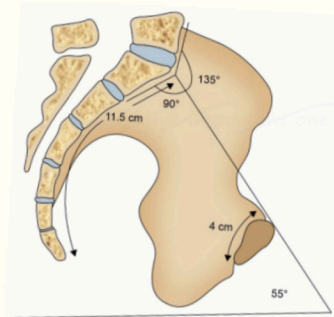
Naegele's pelvis



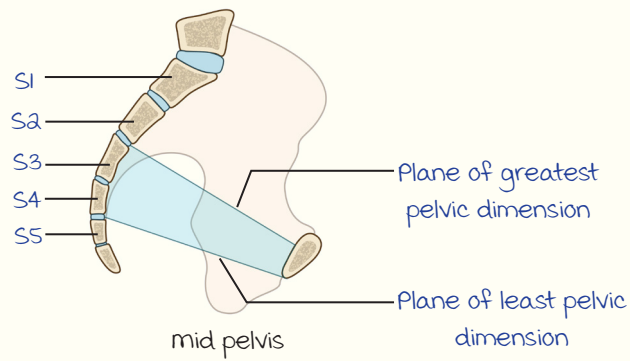
Robert pelvis

Caldwell moly Classification (97) :

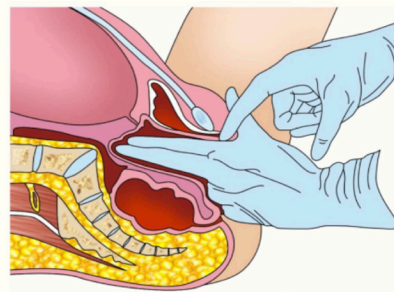
	Gynecoid (♀)	Android(♂)	Anthropoid	Platypelloid
Diagram of inlet	m/c type of pelvis 50% (m/c) 	20%, male pelvis 	25% 	Least common type of pelvis 5% 
Shape of inlet	Transverse oval.	Heart shaped	Anteroposterior oval	Flat bowl like pelvis
Transverse and AP diameter	TD > AP diameter	TD > AP diameter	AP diameter > TD	TD >>> AP diameter
Ischial spine	-	Prominent	-	-
Side walls	Parallel and broad	Convergent	Parallel and narrow	Divergent
Subpubic angle	Obtuse	Acute		
m/c Presentation		Occipitoposterior (OP)	Persistent OP Direct OP	Face
Delivery	most favourable	Least favourable	Face to pubis	



Angle of inclination :
Angle made by inlet with horizontal : 55°



----- Active space -----



Diagonal conjugate being measured

Terminologies of Labour

00:09:57

- m/c lie : **Longitudinal**.
- m/c presentation : **Cephalic**.
- m/c malpresentation : **Breech**.
- Presentation in transverse lie :
Shoulder.

mx of transverse lie :

- Antenatal period → External cephalic version at **≥36 wks**.
- During labour → **C-section**.
- Dead baby with transverse lie (Neglected shoulder presentation) → **C-section**.

Presenting Part :

	vertex m/c	Brow	Face
Fetal head	Flexed or deflexed	Partially extended	Fully extended
AP diameter of engagement	Sub occipitobregmatic	mento vertical : 14 cm	Submento vertical (smv)/ Submento bregmatic (SMB)
Delivery	Vaginal	C-section	If mento anterior : vaginal If mento posterior : C-section

Note :

- Face & brow : **Attitude is abnormal**, presentation is **(N)** (Cephalic).
- m/c congenital anomaly with face : Anencephaly.
- m/c presenting part in anencephaly : Face.

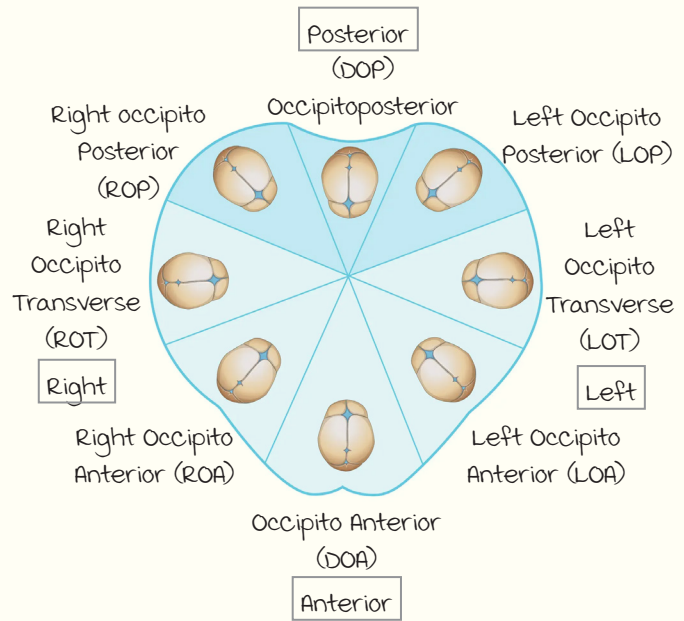
----- Active space -----

Position :

Relationship of denominator to maternal pelvis.

(Denominator : Bony point of reference in presenting part) :

- m/c position in breech : **Left sacroanterior.**
- m/c position in face : **Left mentoanterior.**
- Cord prolapse (max. risk) : **Transverse lie.**
- m/c position :
 - Antenatal : **LOT > LOA.**
 - During labour : **LOT.**
 - Active labour : **DOA.**
- m/c occipito anterior position : **LOA.**
- m/c occipito posterior position : **ROP.**



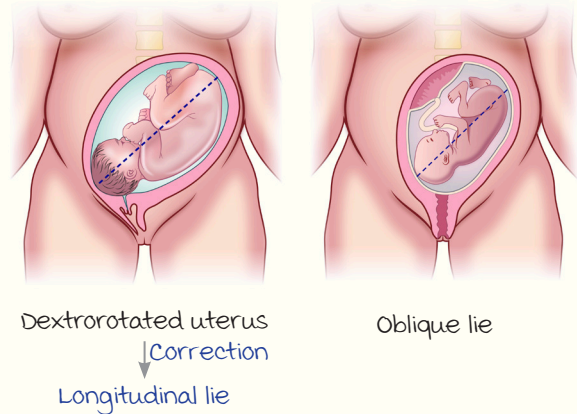
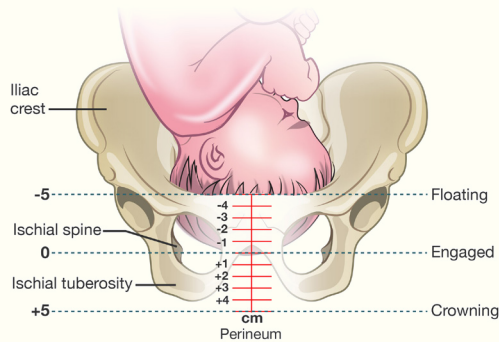
Note : Occipito-posterior is an example of malposition mx : wait & watch.


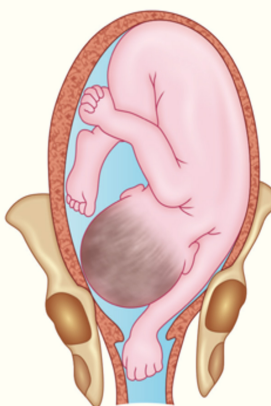
Station :

- Position of fetal head with respect to **ischial spine.**
- Forceps : Applied at **+2** or below.

Lie :

uterus needs to be parallel to vertebra (Not dextrorotated).

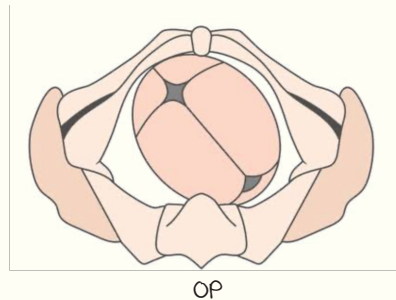


Hand prolapse		Compound presentation	
	Transverse	Lie	Longitudinal
	Hand comes out	Presenting part	Head & hand down
	C-section	mx	vaginal delivery
			

----- Active space -----

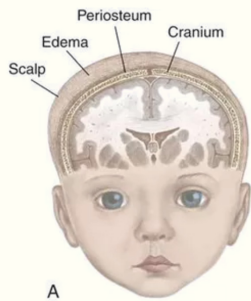
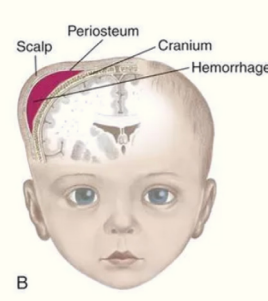
Identification of Position :

- Identify occiput (Below posterior fontanelle : Δ shaped).
- If occiput is near to :
 - Pubic symphysis : OA.
 - Sacral promontory : OP.
 - midway b/w them : OT.
- If occiput towards :
 - Your right : mother's left.
 - Your left : mother's right.



Caput Succedaneum v/s Cephalhematoma

00:19:48





	Caput succedaneum	Cephalhematoma
Collection	Fluid	Blood
D/t	Prolonged stagnation of fetal head during labour	Traumatic instrumental delivery
Location	Above periosteum (Can cross suture lines)	Below periosteum (Cannot cross suture line)
Pits on pressure	Yes	No
A/w fracture	No	Yes
Appearance	At time of birth	Hours after birth
Disappearance	2-3 days	2-3 weeks (drainage is c/d)
		

----- Active space -----

Leopold's Maneuvers

00:21:04

Grips → First 3 : Facing the patient.
 → Fourth : Facing the feet of patient.

	Hand placement	Checks for	Interpretations
1 st : Fundal grip  1 st grip	On fundus	<ul style="list-style-type: none"> • Lie • Presentation 	<ul style="list-style-type: none"> • Empty : Transverse lie • Broad, irregular, soft (Buttocks) : Cephalic presentation • Hard, globular (Head) : Breech presentation
2 nd umbilical/Lateral grip  2 nd grip	Lateral side, parallel to umbilicus	<ul style="list-style-type: none"> • Position 	<ul style="list-style-type: none"> • Smooth, regular, curved, board like rigidity : Back - Back corresponds to occiput • Small, multiple knob like structures : Limbs
3 rd Pawlik grip  3 rd grip	Single hand on pelvic area	<ul style="list-style-type: none"> • Presentation • Engagement of head 	<ul style="list-style-type: none"> • Firm, globular, round structure : Cephalic presentation • Can move head side to side : Ballotable (Not entered pelvis)
4 th : Deep pelvic grip  4 th grip	<ul style="list-style-type: none"> • Over pelvic area • parallel to inguinal ligament 	<ul style="list-style-type: none"> • Attitude • Engagement of head (Confirms Pawlik grip findings) 	<ul style="list-style-type: none"> • Fingers of both hands brought below fetal head • Both hands → Converge : Not engaged → Diverge : Engaged

Bishop's Score & Induction of Labour

00:24:14

----- Active space -----

Bishop's Score :

- To assess susceptibility of cervix for Induction of Labour (IOL).
- Mnemonic : **D**elhi **p**olice **e**mloyed **s**pecial **c**ommanders.

Parameter	0	1	2	3
Cervical dilatation	Closed	1-2 cm	3-4 cm	>5 cm
Cervix position	Posterior	mid	Anterior	-
Cervical effacement	30%	40-50%	60-70%	>80%
Fetal head station	Above -2	At -2	-1, 0	Below 0
Cervical consistency	Firm	medium	Soft	-

Scoring :

- max : 13.
- ≥6 : IOL can be done.
- ≤5 : Poor score, ripening before IOL.
- ≥9 : maximum success of IOL.

modified bishop score : Effacement of cervix replaced by length of cervix (TVS).

Simplified bishop score :

- Dilatation of cervix.
 - Effacement of cervix.
 - Station of fetal head.
- } max. score : 9.

Induction of Labour :

Mechanical methods :

- Foley catheter filled with 30-50 mL NS/extra amniotic saline infusion (Best for IOL in C-section patient).
- Stripping of membranes.

Medical methods :


- Misoprost (PGE₁) : Tab. 25 mcg Q4H P/V (max : 6 doses).
- Dinoprostone (PGE₂) :
 - Cerviprime : Gel 0.5 mg Q6H (max : 4 doses).
 - Cervidil : 10mg dinoprostone placed in posterior vaginal formix (Slow release).

Contraindications :

- Severe cephalopelvic disproportion.
- Contracted pelvis.
- Transverse lie, Brow presentation, Face (mentoposterior) position.
- Fetal distress : Non assuring FHR.

----- Active space -----

- Placenta previa.
- Classical C-section.
- Previous hysterotomy.
- Previous myomectomy.
- Active genital herpes infection.



Cervidil

Normal Labour

00:30:48

At onset :

Estrogen levels	Oxytocin receptors	Prostaglandins	GAP junctions	Progesterone
↑	↑	↑	↑	↓ (Functional withdrawal)

Labour Pain :

	True labour pain	False labour pain
Progression	Progressive	Non-progressive
Cervical dilatation	⊕	⊖
Site	Lower abdomen, radiates to back and thigh	Non-radiating
A/w	Bag of waters	⊖
Pain relief	⊖	⊕ (With enema or sedation)
Character	Regular, rhythmic	⊖

Adequate Contractions :

- Frequency : ≥ 3 in 10 mins.
- Duration : ≥ 45 secs.
- Intensity : 65-75 mm Hg (200-250 mw).
- Origin : Cornua of uterus.

Tachysystole :

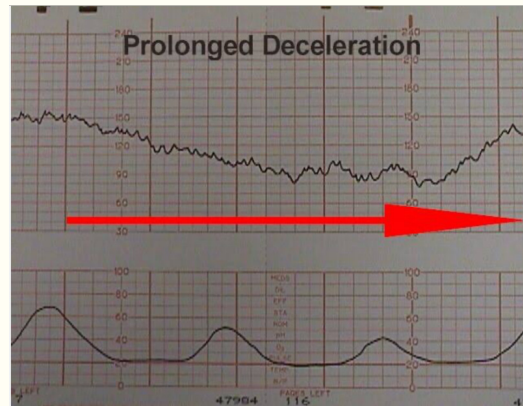
- >5 contraction in 10 mins (with fetal distress : Hyperstimulation).

Cause : Augmentation of labour with misoprost/oxytocin.

CTG : Prolonged deceleration (2-10 mins).

mx :

- Stop oxytocin.
- Left lateral position.
- O₂ by mask.
- Terbutaline.



----- Active space -----

Cardinal movements (572) :

Mnemonic : Every decent female I employ rises extremely late.

- Engagement.
- Descend.
- Flexion of fetal head.
- Internal rotation (IR).
- Extension : Head of baby delivered.
- Restitution.
- External rotation : Internal rotation of shoulders.
- Lateral flexion : Body of baby delivered.

Note :

Crowning → Occurs after IR.
 → Not a cardinal movement.

Note : Delivery of head

- Vertex presentation : By extension.
- Breech & face : By flexion.

Engagement :

- When largest transverse diameter of fetal head crosses pelvic brim (Biparietal diameter : 9.5 cm).
- Time :
 - Primi → 38 weeks.
 - Multi → Onset of labour.
- Assessment :
 - P/A → $\leq 2/5^{\text{th}}$ head palpable.
 - P/V → 0 station or below.
- Cause for unengaged (Free floating) at term in primi :
 Deflexed/OP position > CPD > Placenta previa.

----- Active space ----- Stages of Labour :

Stage	Definition		Function	Duration/rate	
	Begins	End		Primi	multi
1 - Latent phase (Cervical effacement)	Onset of regular uterine contractions	Cx dilatation : • ACOG : 5 cm • modified WHO : 4 cm (Earlier WHO : 3 cm)	Prepares cervix for dilatation	<20 hrs	<14 hrs
1 - Active phase (Cervical dilatation)	• ACOG : 6 cm cervix. • modified WHO : 5 cm	10 cm (Complete cervical dilatation)	Rapid cervical dilation	1.2 cm/hr	1.5 cm/hr
2	10 cm dilated cervix	Delivery of baby	Delivery of baby	Without epidural	
				50 min (Avg)	30 mins (Avg)
				<3 hr (max)	<2 hr (max)
				+ Epidural : +1 hr	
3	Delivery of baby	Delivery of placenta	Delivery of placenta	<ul style="list-style-type: none"> • Active mx : 5-10 min. • Passive mx : 10-15 min • max: 30 mins 	
4	<ul style="list-style-type: none"> • Observation period after delivery of placenta • C/F : Physiological chills 			1-2 hours	

Note :

1. Active phase begins at :

- 4cm → modified WHO.

- 5cm → Labor care guide (Next generation). } Partogram.

- 6cm → ACOG guidelines.

2. Dilatation of cervix in active phase recommendation :

- Earlier WHO : minimum 1 cm/hr.

- New WHO : Can be <1 cm/hr.

Abnormal Stages of Labour Management

00:39:56

----- Active space -----

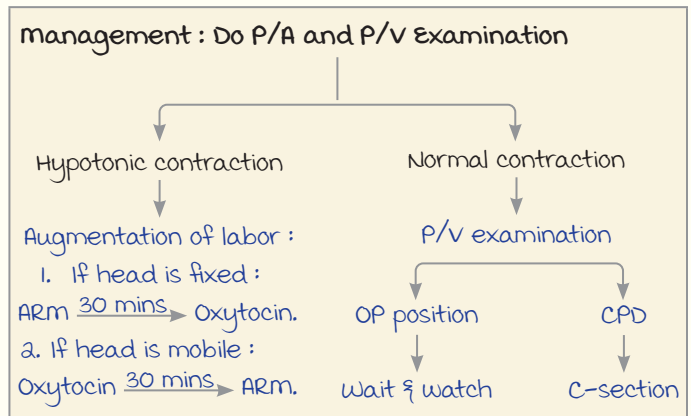
Abnormality
Prolonged latent phase

Definition
If latent phase :
• ≥20 hours in primi.
• ≥14 hours in multi

Cause
• Occipitoposterior position.
• Unfavourable cervix.
• False labour pains.
mx :
Therapeutic rest (C-section is never done for prolonged latent phase)

Abnormality
Protracted active phase : Slow progression.
Note :
Dilatation of <1 cm/hr + moulding or caput indicates CPD.

Definition
• If dilatation of cervix is <1 cm/hr.
• Descent of fetal head is <1 cm in primi or <2 cm in multigravida.



ABNORMAL STAGES OF LABOR AND MX

Abnormality
Arrest of active phase

Definition
It is diagnosed if membranes are ruptured and cervical dilatation has not changed :
• For 4 hrs with adequate uterine contraction.
• 6 hrs hours : If oxytocin is given with inadequate uterine contraction.

mx
C-section.
Note : If fetal distress (+) → Emergency C-section.

Note :
Forceps and vacuum can be applied only if :
1. Cervix : Fully dilated.
2. Station of fetal head : ≥+2

Second stage arrest/prolonged

Nulliparous : If second stage ≥3 hours without epidural or ≥4 hours with epidural.
Multiparous : If second stage ≥2 hours without epidural or ≥3 hours with epidural.

mx :
• In case of prolonged second stage if head of fetus above +2 station section : C-section.
• Head of fetus is at or below +2 : Forceps/vaccum.
• Bandl's ring (Indicates obstructed labor) present : C-section.
• moulding/Caput present with second stage arrest (CPD) : C-section.

----- Active space -----

Obstructed Labor

00:46:21

Cause :

Transverse lie/Conjoint twin etc.

Clinical features :

maternal dehydration exhaustion, tachypnea, tachycardia.

On P/A :

- Upper uterine segment (UUS) : Thick, tender & tonically contracted.
- LUS : Thinned & stretched.
- Bandl's ring (Depression/groove felt & **seen** b/w UUS & LUS).

On P/V :

- Hot and dry vagina.
- Caput (+).
- moulding (+).
- Hematuria +/-.

mx :

- **C-section immediately.**
- Do not give oxytocin/forceps/vaccum.

Complication :

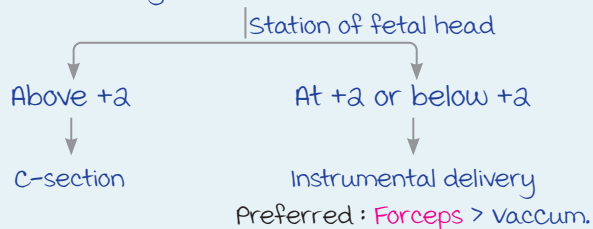
1. Rupture of uterus.
2. Vesicovaginal fistula : m/c cause is obstructed labour in developed countries.

mx of fetal distress in labor :

In first stage of labor : (Dilatation <10 cms).

mx : C-section.

In second stage of labour (Dilatation is 10 cm) :

**Augmentation of Labour :**

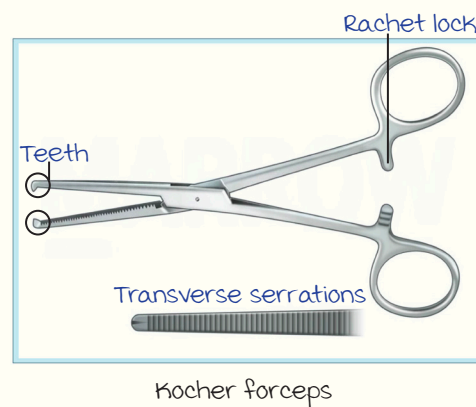
Augmentation means accelerating the progress of labor.

Indication : Protracted active phase after ruling out occipitoposterior position and CPD.

1. methods : Artificial rupture of membranes done by Kocher forceps.
2. Oxytocin : Given at 6 mU/min increased at interval of 20-40 minutes by 6 mU.

C/I of ARM :

1. maternal HIV infection.
2. Genital Herpes infection.
3. Vasa previa.
4. Intrauterine death of fetus.

Note : In polyhydramnios → **Controlled** rupture of membranes is done**Note :**

Band's ring	Constriction ring/Schroeder ring
<ul style="list-style-type: none"> • Retraction ring • Due to obstructed labor • Between UUS and LUS • Seen in 2nd stage of labor • Felt and seen P/A • A/w maternal dehydration and fetal distress • Relieved by C-section 	<ul style="list-style-type: none"> • Constriction ring • Injudicious use of oxytocin → Localised spasm of uterus • Can be seen anywhere • 1st or 2nd stage of labor • Felt P/V • mother and fetus are normal • Relieved by sedation, if ring reappears then do a lower vertical C-section (Only indication)

Management of Labour

00:51:24

----- Active space -----

AT ADMISSION

Recommended :

- Check vitals.
- Leopold's maneuvers.
- Ascultate FHS.
- P/v examination : (Contraindicated in active bleeding).

Not recommended :

- Routine pelvimetry.
- Routine enema.
- Routine CTG.
- Routine pelvic shaving.

STAGE I OF LABOUR

Supportive Care (Labor Care Guide) :

Early Labour : Ambulation allowed.

Late labour : Lie in left lateral position.

Oral intake :

- Solids are not allowed.
- Clear fluids can be given orally.
- IV fluids can be given for C-section.
- Liquid stopped : 2 hrs before surgery.
- Solid stopped : 6 hrs before surgery.

Bladder function : Encouraged.

Pain relief : Epidural/opioids/massage etc.

Companion : Allowed.

monitoring :

maternal :

- Pulse & BP : Hourly.
- Temperature : 4 hourly (Hourly if membranes have ruptured).
- uterine contractions : Every 30 mins.
- P/v : 4 hourly.

FHR

	Low risk ♀	High risk ♀
Stage 1	30mins	15mins
Stage 2	15 mins	5mins

MANAGEMENT OF SECOND STAGE

Prevention of perineal tear (STP) :

- Perineal massage.
- Warm compress at perineum.
- Controlled delivery of head.
- Perineal support.
- Fetal head : First flexed, then extended with one hand & other hand should support perineum (modified Ritgen maneuver).

----- Active space ----- Not recommended :

- Routine episiotomy.
- Fundal pressure.

Breech

00:54:00

m/c malpresentation.

m/c cause of breech : Prematurity.

m/c cause of recurrent breech : uterine malformation.

Risk of gross congenital anomalies : 10%.

IOC : USG.

Best mx of breech : C-section at 39 weeks.

Breech with head extended : Stargazer breech (mx : C-section).

Risk of cord prolapse : Footling > knee > flexed > frank.

vaginal delivery, ECV C/I : Footling & knee.

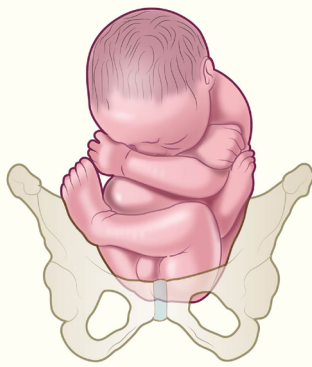
mx in antenatal period : external cephalic version (ECV) at ≥ 36 wks.

vaginal delivery in breech : Assisted breech delivery.

Note :

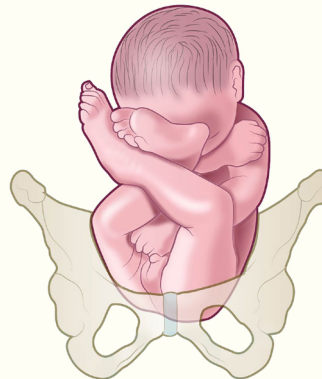
max risk of cord

prolapse : Transverse lie



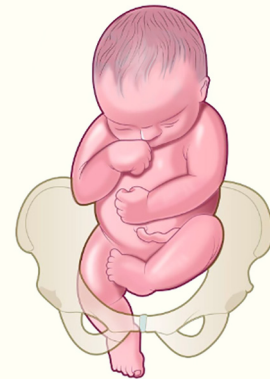Complete/Flexed breech :

- Hip & knee flexed
- vaginal delivery possible



Frank breech :

- Hip flexed, knee extended
- vaginal delivery possible



Footling breech :

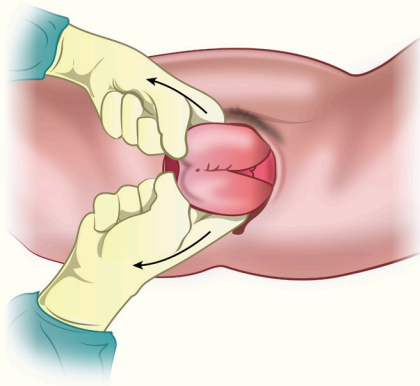
- Hip & knee extended
- C-Section only

Criteria for favorable breech :

- Gestational age : ≥ 36 weeks.
- Spontaneous onset of labour should be present.
- No h/o C-section (VBAC : Relative C/I).
- No c/I to vaginal delivery.
- Facility for emergency C-section should be present.
- USG should show :
 - Frank breech > complete breech.
 - Head should not be extended.
 - Weight of baby : 2-4 kg.
 - No anomaly causing abnormal labor.

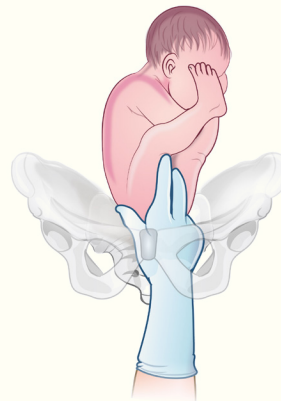maneuver for Breech Delivery :

----- Active space -----



Groin traction :

- Delivery of **buttocks**.
- Flexed breech.



Pinard maneuver :

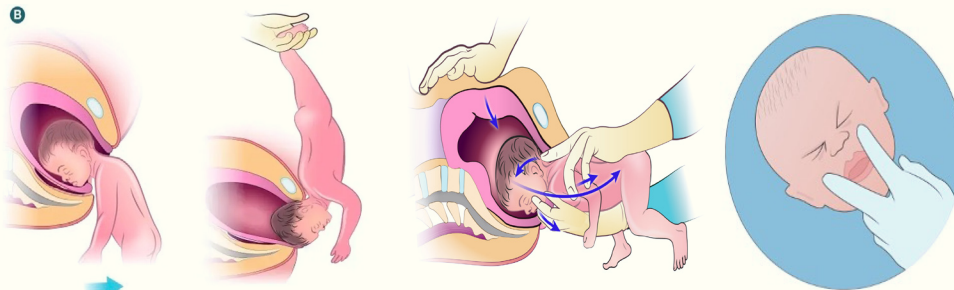
- Delivery of **extended legs**.
- Pressure on **popliteal fossa**.

Lovset's maneuver :

- Delivery of **shoulder**.
- Hold back of baby & rotate.

Delivery of after coming head in breech :

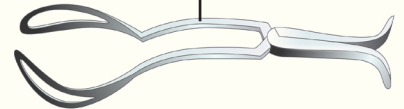
- Head is last part to be delivered.
- m/c cause of death in breech : Intracranial haemorrhage.
- Head is born by movement of : Flexion.
- method of delivery in dorso anterior breech (m/c) :



1. Burn Marshall technique

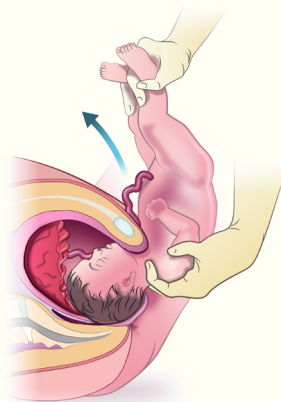
2. Mauriceau Smellie Veit technique : malar flexion + Shoulder traction

Perineal curve



3. Piper's forceps : Long forceps

- Dorsoposterior :



Prague maneuver : Back is posterior

----- Active space -----

Malpresentation and Malposition

01:00:32

Transverse lie :

- Presentation : **Shoulder.**
- Vaginal delivery : **Not possible.**
- Maximum risk of : **Cord prolapse.**
- If patient comes in antenatal period with transverse lie : **ECV at ≥ 36 weeks.**
- If patient comes in latent phase with transverse lie : **ECV.**
 - If patient comes in active phase : **C-section.**
 - m/c/c of transverse lie : **Prematurity.**
 - m/c/c of transverse lie at term : **Placenta previa.**

Brow :

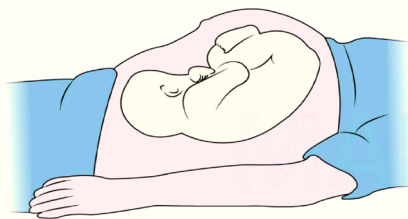
- Engaging diameter : **mentovertical $\rightarrow 14$ cm.**
- mx (Always) : **C-section.**
- If anterior fontanelle and supra orbital ridge palpable : **Brow presentation.**

Face :

- Denominator : **mentum.**
- mentoposterior :
 - **C-section.**
 - **No forceps, No vacuum.**
- mentoanterior : **vaginal delivery.**
 - Engaging diameter : **smv/smb.**
 - Head of baby is born by **flexion.**
 - **Forceps : Possible.**
 - **Vacuum : Not possible.**

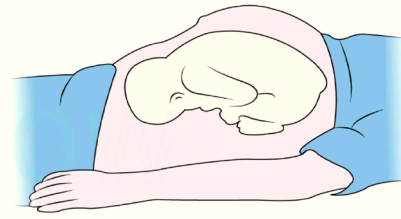
MALPRESENTATION AND MALPOSITION**Occipito Posterior Position :**m/c OP position : **ROP.**m/c cause of OP position : **Deflexed head.**2nd m/c cause of OP position : **Android pelvis.**m/c outcome in OP position : **Anatomically becomes DOA (Rotates 3/8th of circle).**Best management of OP : **wait and watch.****Deep Transverse Arrest (TVA) :**

- m/c pelvis : **Android.**
- m/c level : **Ischial spine.**
- Best management : **C-section.**



Occipitoposterior (TVA) :

- **Infraumbilical flattening.**
- **FHS heard in maternal flank area.**



Occipitoanterior :

- **Smooth baby bump.**
- **FHS heard near umbilicus.**

External Cephalic Version

01:03:29

----- Active space -----

Procedure :

- Per-abdominally baby is rotated from transverse lie or breech and made cephalic.
- Done in OPD.
- Anesthesia not needed. Tocolytics are used to relax.

Indication :

Breech/Transverse lie in singleton pregnancy.

- In Rh negative females : Anti-D given after.
- No routine induction of labor after ECV
- Should be done under continuous fetal monitoring.
- Previous cesarean sections : Relative C/I.

EXTERNAL CEPHALIC VERSION

Pre-requisites for ECV	Absolute contraindications for ECV
Period of gestation ≥ 36 weeks : usually done at 37 weeks (Less chances of reversion).	Oligohydramnios.
Liquor should be adequate and membranes should be intact.	Ruptured membranes.
Can be done in early labor (Latent phase) if membranes are intact.	Active phase of labor.
Singleton pregnancy.	Twin/multifetal pregnancy.
Fetal heart rate should be normal on CTG.	Abnormal fetal heart rate on CTG.
No contraindications for vaginal delivery.	<ul style="list-style-type: none"> • Placenta previa/contracted pelvis. • uterus/fetus grossly anomalous.

Relative Contraindications for ECV :

- PIH.
- Heart disease in mother.
- IUGR.
- Previous LSCS.

----- Active space -----

Partogram

MODIFIED WHO PARTOGRAM

- Based on earlier WHO recommendations :
 - Latent phase : Till 3 cm.
 - Active phase : 4-10 cm.
 - Active phase minimum dilation : 1 cm/hr (Based on this alert line is drawn.)
- Time duration b/w alert & action line : 4 hrs.
- Latent phase : Not represented.
- Active phase : Represented.
- Second stage of labour : Not represented.

Upper Part :

Fetal condition assessment.

FHR :

- FHR represented by a circle.
- Ⓝ FHR : 110-160 bpm.
- FHR plotted every 30 minutes.
- Each square is 30 mins

Amniotic fluid :

- I : Intact.
- A : Absent liquor.
- C : Clear liquor.
- B : Blood stained.
- m : meconium stained.

moulding : If present or not.

middle Part :

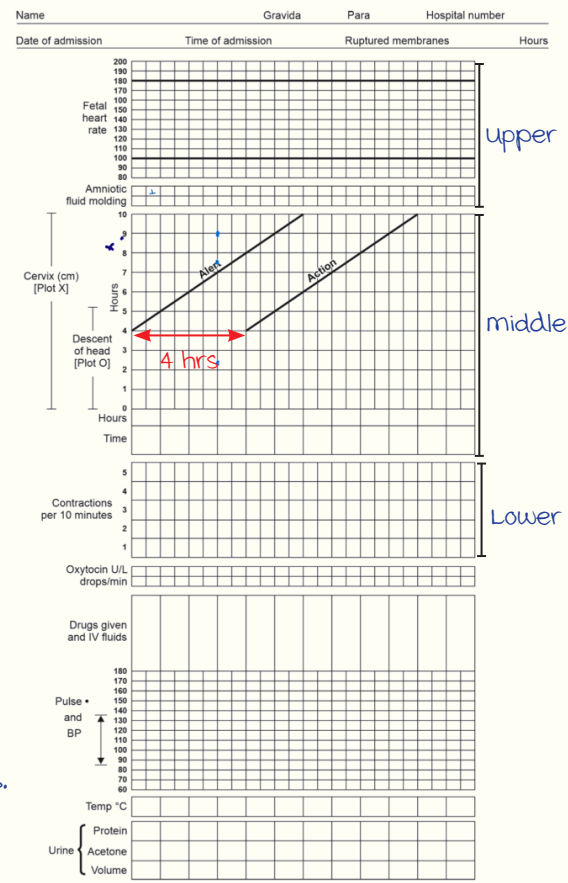
Cervicogram :

- X axis : Time.
- Y axis : Cervical dilatation (x).
- Descent of fetal head (o).
- Big square : 1 hr.
- Small square : 30 mins.
- 2 parallel lines :
 - Alert & action line.
 - Duration b/w : 4 hrs.

Lower Part :

maternal condition assessment.

- Uterine contractions :
 - Every 30 mins.
 - Placing palm on fundus of uterus.
 - No : of contractions in 10 mins.
- Each square : 1 contraction.



Partogram

Contraction	Representation
<20 s	
20-40 s	
>40 s	

----- Active space -----

Following charted :

- Oxytocin.
- Drugs.
- Pulse, BP, temperature of mother.
- urine output.

Not charted :

- Respiratory rate.
- Oral intake.
- Oxygen saturation.

LABOR CARE GUIDE (LCG)/NEXT GENERATION PARTOGRAM

Based on new WHO guidelines (2020) :

- Active phase : Begins at 5 cm.
- If mother and baby are fine : Cervical dilatation can be <1 cm/hr.

In LCG :

- Latent phase : Not represented.
- Active phase : At 5 cm.
- Plotting should begin : At 5 cm.
- No alert & action line.
- 2nd stage of labour : Is represented.

used for :

All females who are delivering (Especially low risk).

used at :

At all levels of health care.

Sections in LCG :

Mnemonic : **Smart beautiful women love me.**

1	Pt details & labour details
2	Supportive care
3	Care of baby
4	Care of woman
5	Labour progress
6	medication
7	Shared decision making

Section 2 : Supportive care

- C : Companion
- P : Pain relief
- O : oral fluid
- P : Posture
- Y : Yes.
- N : No (Alert).
- D : Woman declined.
- mo : mobile.
- L : Left lateral.
- SP : Supine (Alert sign).

The form is titled 'WHO LABOR CARE GUIDE' and is divided into several sections:

- Section 1:** Patient information including Name, Parity, Labor onset, Active labor diagnosis (Date), and Risk factors.
- Alert Column:** A vertical column for recording alerts, with a horizontal timeline for the first and second stages of labor.
- Section 2 (Supportive Care):** A grid for recording interventions like Companion, Pain relief, Oral fluid, and Posture.
- Section 3 (Maternal):** A grid for recording maternal vital signs and status (e.g., Blood pressure, Heart rate, Temperature, Pulse, Respiration, Urine).
- Section 4 (Fetal):** A grid for recording fetal status (e.g., Fetal position, Cervix, Moulding).
- Section 5 (Labour Progress):** A grid for recording labor progress, including Cervix dilation (cm) and Descent (cm).
- Section 6 (Medication):** A grid for recording medications used, such as Oxytocin, Analgesia, and IV fluids.
- Section 7 (Shared Decision Making):** A grid for recording patient decisions and the provider's plan.

At the bottom, there are instructions for use and a legend for abbreviations.

OBSTETRICS : PART 8

----- Active space -----

Active Mx of Third Stage of Labour (AMTSL)

00:00:34

WHO Recommends :

Active management of third stage of labor (AMTSL)

- It **decreases** the duration of **third stage** (5-10 mins)
- Decreases blood loss
- **Decreases** chances of **PPH**
- AMTSL is the **best method** to prevent PPH

Steps in AMTSL :

1. Inj. **uterotonic** within **1 minute** of delivery of baby or **immediately after delivery** of **anterior shoulder** of baby (**most imp step**)
2. Delayed cord clamping (Clamping cord in 1-3 mins of delivery)
3. Delivery of placenta by controlled cord traction (**modified Brandt Andrews technique**)
4. Intermittent assessment of uterine tone (Earlier : uterine massage)

Note : **Early cord clamping** is not a part of AMTSL

AMTSL

Uterotonics :

Recommended by WHO :

Oxytocin : 10 IU IM or IV infusion.

If oxytocin is not available, the following can be given :

1. methyl ergometrine : (methergine) 0.2 mg IM (**Never given I/V** as it can lead to hypertension)
2. Syntometrine : Fixed dose combination of 5 U oxytocin and 0.5 mg methyl ergometrine
3. **Carbetocin** : **Synthetic oxytocin** with longer $T_{1/2}$ and dose - 100 mcg slow IV.
4. **misoprost PGE₁** 600 mcg oral for AMTSL (400-600 mcg)
5. **WHO recommends misoprostol distribution to pregnant females** to prevent PPH

Note :

Carboprost : PGF_{2α} is used for management of PPH and **not for AMTSL**

Conditions Of Early Cord Clamping :

(Clamping cord **within 1 minute** of delivery)

1. Birth asphyxia } Absolute
2. If **neonatal resuscitation** is needed. } Indication
3. K/c/o congenital heart disease
4. If in Rh negative female : Indirect coomb's test is negative (**Non-isoimmunized pregnancy**)

Delayed Cord Clamping Indications :

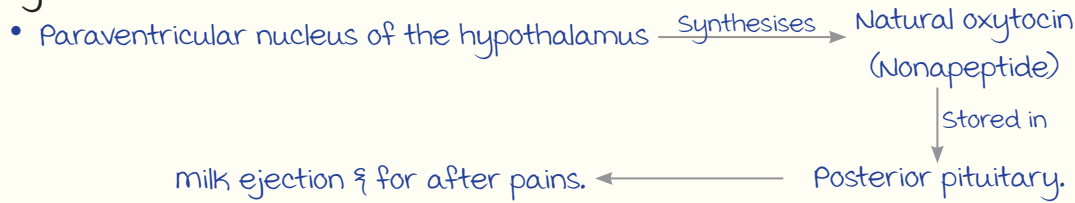
- HIV + pregnant females
- **In case of Rh negative pregnancy** : If indirect Coombs test is positive, where maternal antibodies are already formed against fetal Rh antigen, early cord clamping is of no use
- In preterm infants
- In COVID 19 +ve patients
- Macrosomic babies.
- In post term cases.

Note : Extra 80 ml of blood goes to fetus → Prevents neonatal anemia

DRUGS USED IN AMTSL & PPH

----- Active space -----

Oxytocin :



- $t_{1/2}$: 3-5 mins.

Route : Im/IV infusion (Prepared in Ringer lactate/normal saline).

C/I :

- IV bolus \rightarrow Hypotension/cardiac arrest.
- Dextrose 5% preparation \rightarrow Water intoxication.

If Oxytocin unavailable :

	methyl ergometrine	misoprost	Carboprost
Route	Im (Never IV)	<ul style="list-style-type: none"> • Oral/sublingual/PR (Available as tablet) • P/V route : Not used 	Im (Available as injection)
Features	Leads to tetanic uterine contractions	<ul style="list-style-type: none"> • Water, heat soluble • $t_{1/2}$: 20-40 mins • Can be used in asthmatic patients 	Best in mx of PPH (But not in AMTSL)
C/I	<ul style="list-style-type: none"> • Absolute : mnemonic : TOPER <ul style="list-style-type: none"> - After 1st twin delivery - Organic (Any) heart disease - Peripheral vascular disease - Eclampsia & pre-eclampsia - Rh -ve ♀ • Relative : HIV ⊕ ♀ on protease inhibitor <p>Note : Oxytocin can be used in all these conditions.</p>	P/V administration in AMTSL/PPH	<ul style="list-style-type: none"> • Absolute C/I : <ul style="list-style-type: none"> - Asthmatics - Pulmonary HTN - Suspected amniotic fluid embolism • Relative C/I : Pre-eclampsia, renal disease
Side effect	Transient severe hypertension	Hyperthermia	Diarrhea

Note :

Drugs not used in PPH mx in hypertensive pts : methyl ergometrine > carboprost.

----- Active space -----

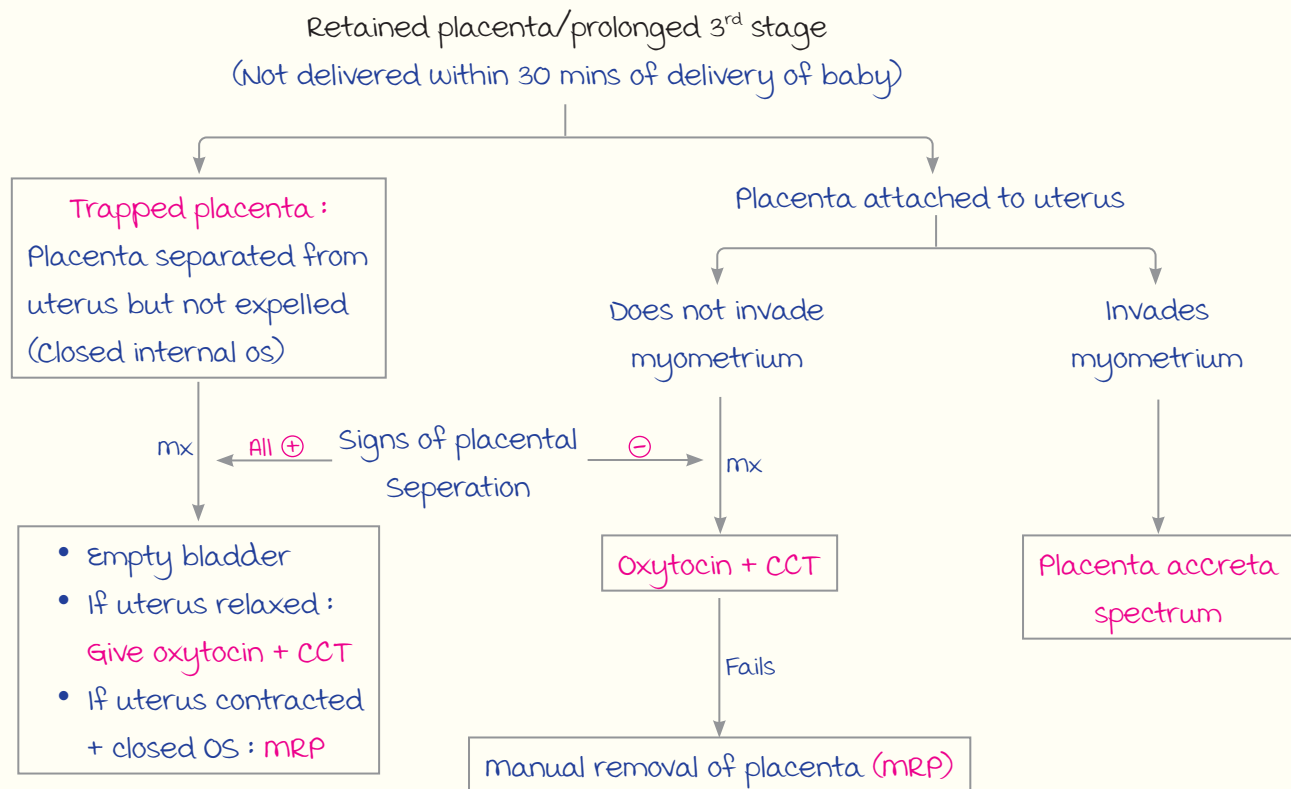
Signs & Methods of Placental Separation

00:06:31

Signs	methods
<ul style="list-style-type: none"> Gush of blood per vaginally Suprapubic bulge Apparent + permanent cord lengthening (2nd best sign) Height of uterus rises slightly 	<p>1. Schultze method (m/c) :</p> <ul style="list-style-type: none"> Central separation → Retroplacental clot formed → ↓Bleeding Shiny fetal surface of placenta comes out first.
<p>Surest sign : Feel of placenta in vagina</p>	<p>2. Duncan method :</p> <ul style="list-style-type: none"> Peripheral separation Dull maternal side of placenta comes out first

Retained Placenta & Placenta Accreta Spectrum

00:07:59

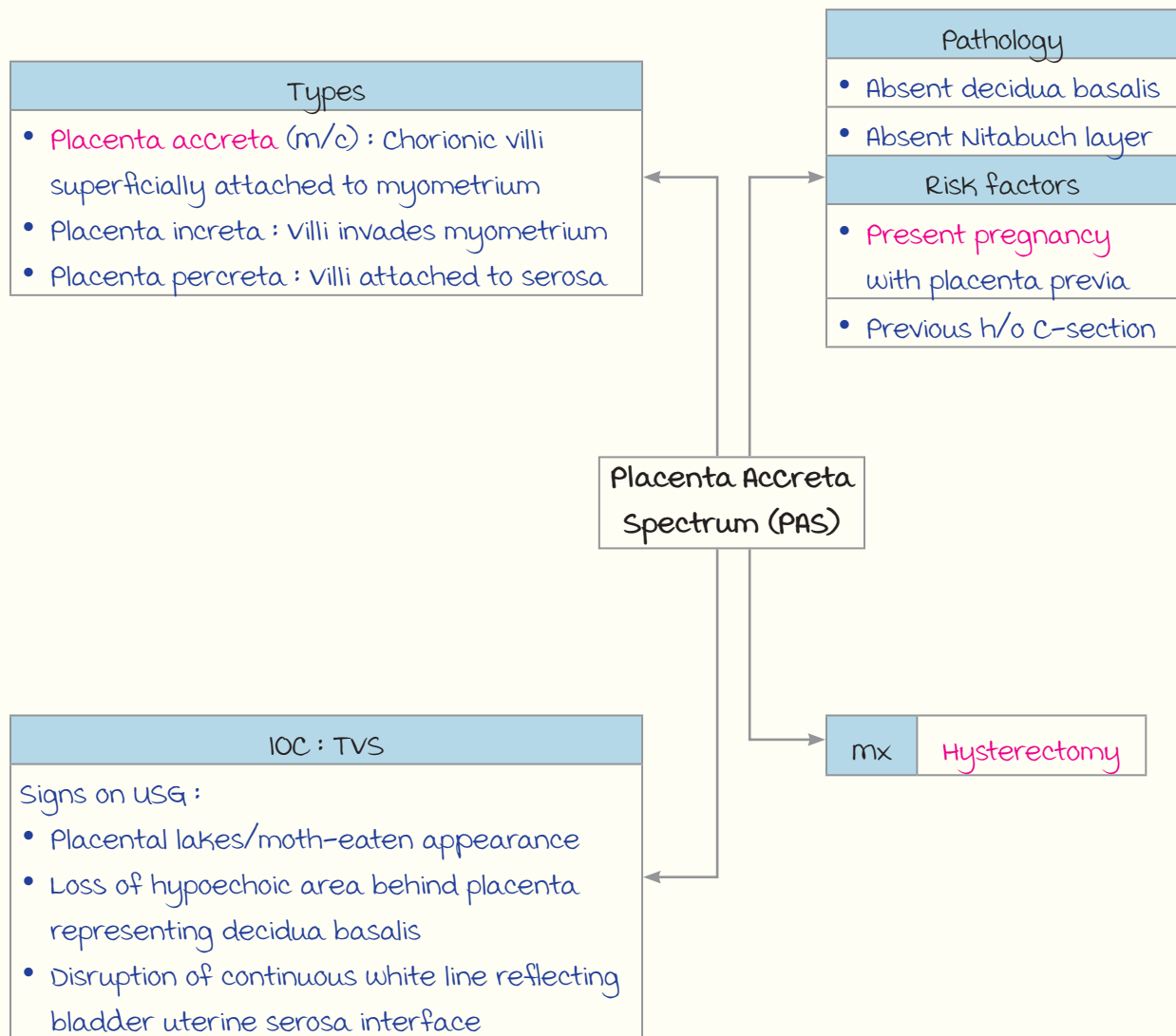


Note :

At any point of time while doing CCT → Cord breaks $\xrightarrow{\text{Next step}}$ MRP

PLACENTA ACCRETA SPECTRUM

----- Active space -----



Postpartum Hemorrhage (PPH)

00:10:55

Definition :

- ≥ 500 ml blood loss → After vaginal delivery.
- ≥ 1000 ml blood loss → After cesarean section.
- ACOG : ≥ 1 litre blood loss → After any type of delivery.

m/c cause : **Atonic uterus.**

m/c cause of 1° PPH (within 24 hours of delivery) : **Atonic uterus.**

m/c cause of 2° PPH (>24 hours to 12 weeks after delivery) : **Retained placental tissue.**

----- Active space ----- **mx of PPH :**

1st step : maternal resuscitation
 Airway, breathing, circulation monitoring & mx | Ix : Blood grouping, BT, CT

P/A examination
 +
 P/A uterine massage

Ⓣ → **Atonic PPH** | **Assess uterine tone** | Ⓝ → **Traumatic PPH**

P/v exam : Rule out presence of membrane/placental tissue

Once diagnosis confirmed

1st line of management
 Bimanual massage + uterotonic drugs +
 Tranexamic acid (1g in 100 ml NS over 10-20 mins)

If bleeding not controlled in 30 mins

mechanical compression
Bakri balloon catheter (max capacity : 500ml)

If bleeding continues, shift to OT

Compression sutures
 1. **B Lynch sutures** (m/c)
 2. Hayman suture
 3. Cho square suture
 4. Gunshella suture

Bleeding persists

Stepwise devascularization
 1. Uterine artery ligation
 2. Ovarian artery ligation

Bleeding persists →

Check vitals

stable →

Ligate anterior division of internal iliac artery

unstable ↓

Subtotal hysterectomy
 (Uterus removed, Cx spared)

Bleeding persists ←

Pelvic pressure packs applied :
 • Umbrella pack
 • Parachute pack

Bleeding persists →

uterotonics in mx of PPH
 Oxytocin IV infusion
 (20 IU in 500ml NS)
 ↓ Fails
 methergine 0.2 mg IM
 (Repeated 2-4 hours)
 ↓ Fails
 Carboprost 250 mcg IM
 • Repeat every 15-90 mins
 • max : **8 times/2 mg.**
 Add on : misoprost
 • WHO : 800 mcg PO or S/L
 • ACOG : 600-1000 mcg oral, S/L or P/R.

Drugs not used in mx of PPH :

- **Dinoprostone** (PGE₂) : used for induction of labour (IOL).
- **Carbitocin** : used in AMTSL.

----- Active space -----

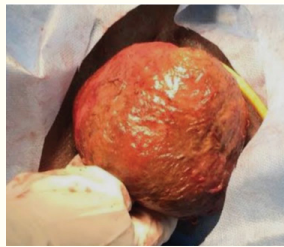Note (97) :

- **Water under bridge** :
 - uterine artery crosses ureter 2 cm lateral to internal OS.
 - m/c **site of ureteric injury** during hysterectomy.
- Postpartum collapse :
 - **PPH** : m/c cause of collapse after delivery.
 - **uterine inversion** : m/c cause of shock immediately after delivery.
 - Amniotic fluid embolism (Anaphylactoid syndrome of pregnancy) :
Shock + difficulty in breathing/DIC.

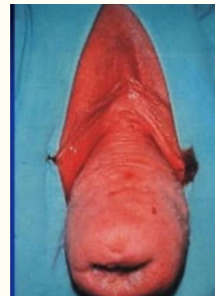Uterine Inversion

00:18:43

Prolapse of uterine fundus into uterine cavity; obstetric emergency.



uterine inversion :
Internal OS not seen



uterine prolapse :
Internal OS visible

m/c cause : **mismanaged 3rd stage of labour.**

Suspect uterine inversion : Immediate shock after delivery.

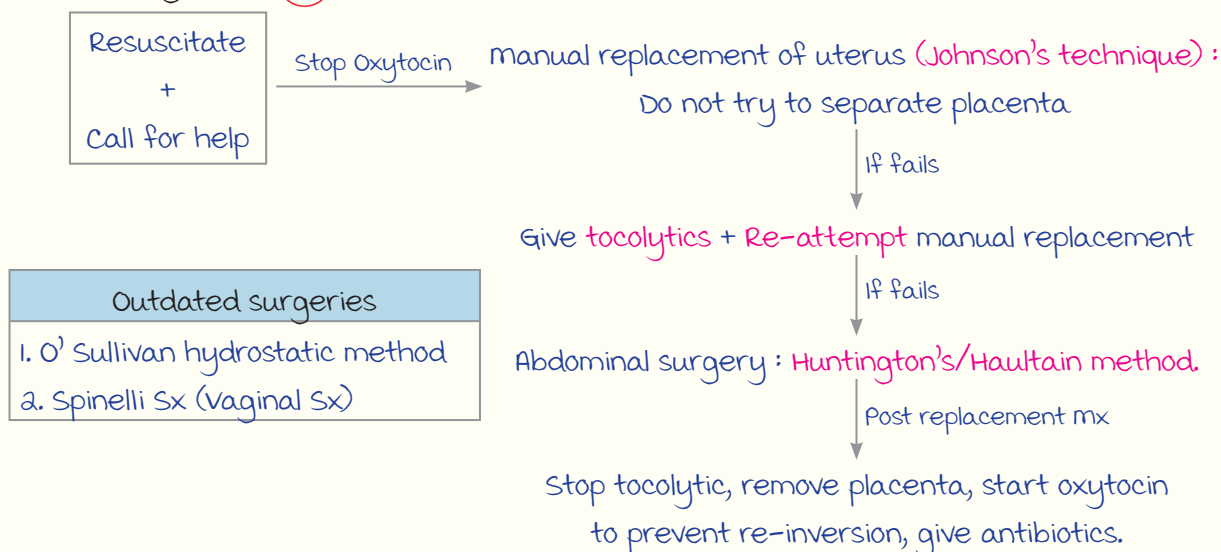
Initial shock : Neurogenic $\xrightarrow{\text{Later}}$ **Hemorrhagic shock** (Cause of death)

O/E :

P/A : Cup-like depression below umbilicus (Fundus is depressed).

P/V : Bleeding + globular mass in vagina.

----- Active space ----- management (97) :



Amniotic Fluid Embolism

00:22:03

- Clinical diagnosis, no confirmatory test.
- P/A & P/V : (N).
- Can lead to maternal mortality within 30-40 mins.

Time of occurrence : At the time of labour/within 30 mins of labour.

2 phases :

- 1st Phase : Cardiorespiratory arrest (Difficulty breathing, ↑PR, ↓BP).
- 2nd Phase : DIC + excessive bleeding.

Diagnostic criteria
<ul style="list-style-type: none"> • unexplained shock + less bleeding. • Clinical onset within 30 mins of labour. • Abrupt cardiorespiratory arrest. • Overt DIC. • No fever.

Perineal Tear & Episiotomy

00:24:26

Grading of Perineal Tear :

Grades	Structures involved	mx
1	vaginal epithelium/perineal skin (Corresponds to median episiotomy)	<ul style="list-style-type: none"> • Repaired like episiotomy (In labour room ↓ LA) • Sequence : vaginal mucosa → muscles → Skin
2	1 + peritoneal muscles (Correspond to mediolateral episiotomy)	

----- Active space -----

Grades	Structures involved	mx
3	2 + anal sphincter	Complete perineal tear (3 & 4) Repair : Done in OT ↓ epidural/GA
3a	<50% of external anal sphincter	
3b	≥50% of external anal sphincter	
3c	Internal sphincter	
4	3 + rectal mucosa	

Avoid pregnancy × 1 year (At least × 6 months after repair).

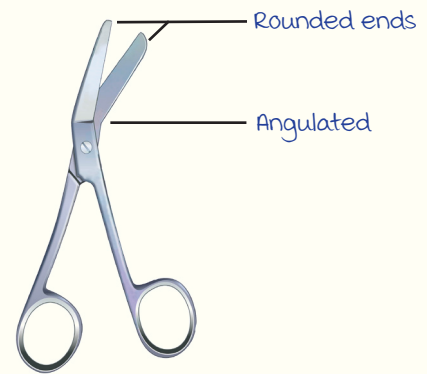
mode of delivery :
 → ♀ can have vaginal delivery.
 → If h/o ≥ 2 times anal sphincter injury → C-section.

EPISIOTOMY

WHO does not recommend routine episiotomy in all ♀'s undergoing vaginal delivery.

Types :

median episiotomy	mediolateral episiotomy
-	Angle : 45°-60°
Involves anal sphincter if extended : Less preferred	Does not involve anal sphincter when extended : m/c preferred
<ul style="list-style-type: none"> ↓ Bleeding, healing quicker ↓ Chances of dyspareunia & wound gaping 	<ul style="list-style-type: none"> ↑ Bleeding, healing delayed ↑ Chances of dyspareunia & wound gaping



Episiotomy scissors

muscles attached in the mid-line/to perineal body are cut.

muscles not cut during episiotomy : Ischiococcygeus/coccygeus, ischiocavernosus, anal sphincter, obturator internus.

VBAC/TOLAC

00:27:46

VBAC : Vaginal birth after cesarean; TOLAC : Trial of labour after cesarean.

Absolute C/I	Relative C/I	Not a C/I
<ul style="list-style-type: none"> Previous : <ul style="list-style-type: none"> - Classical/T shaped C-section - myomectomy/hysterectomy - H/o uterine rupture Home birth/no 24 hours facility availability C/I to vaginal delivery (Placenta previa, CPD) CPD in present pregnancy ≥ 2 LSCS (As per national guidelines) 	<ul style="list-style-type: none"> In present pregnancy : <ul style="list-style-type: none"> - macrosomia - malpresentation Post term pregnancy 	<ul style="list-style-type: none"> Twin pregnancy Polyhydramnios

----- Active space ----- ACOG recommendation :

- TOLAC can be done in previous h/o LSCS (Any number).
- TOLAC can be done in previous Krönig incision (+/-).
- **External cephalic version (ECV)** : Relative C/I in VBAC.
- **Internal podalic version (IPV)** : Absolute C/I in VBAC.
- Twin in present pregnancy → **Not a C/I except** :
 - monochorionic monoamniotic twins.
 - Conjoint twins.
 - 1st twin → Cephalic + 2nd twin → Transverse lie.

monitoring in VBAC

- Pulse rate of mother.
- CTG monitoring.
- **uterine** scar tenderness.

Classical Cesarean Section

00:30:51

Incisions — In upper uterine segment : **Classical** cesarean section.
 — In lower uterine segment : **LSCS**.

Indications :

- Cancer cervix.
- Lower uterine segment adhered to bladder.
- Placenta previa + blood vessels all over lower segment.
- Lower segment not formed :
 - Preterm cesarean section
 - Perimortem cesarean section (maternal cardiac arrest : Delivery in 4 mins)

Previous classical C-section :

- Never do vaginal delivery.
- LSCS (Next pregnancy) → To avoid uterine rupture.

Note : Presentation of uterine rupture :

- Bleeding during labour + pain abdomen.
- O/E → uterus not felt, fetal parts superficially felt, loss of fetal station.

Instrumental Delivery

00:33:49

Types : Forceps delivery & vacuum delivery.


Pre-requisites for Forceps Delivery :

mnemonic : **FORCEP**

- **F**avourable position & station ($\geq +2$).
- **O**S : fully dilated.
- **R**uptured membranes.
- **C**ontracted uterus.
- **E**pisiotomy to be given, empty bladder.
- **P**elvis : Adequate.

Forceps & vacuum applied in

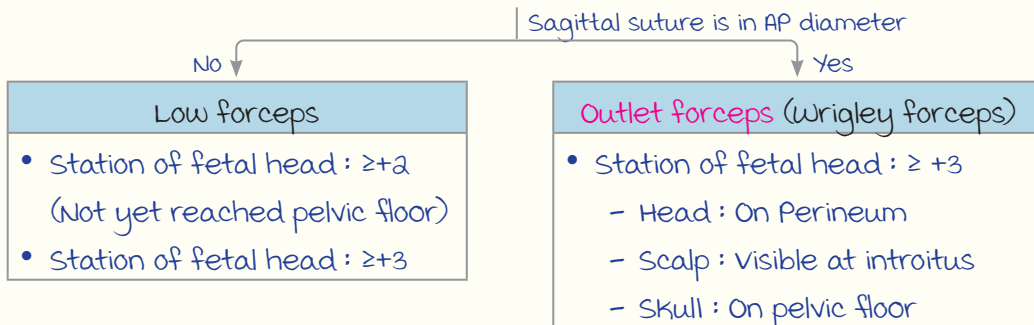
1. **Fully dilated (10 cm) cervix.**
2. Station of head : $\geq +2$.

Forceps vs Vacuum  :

----- Active space -----

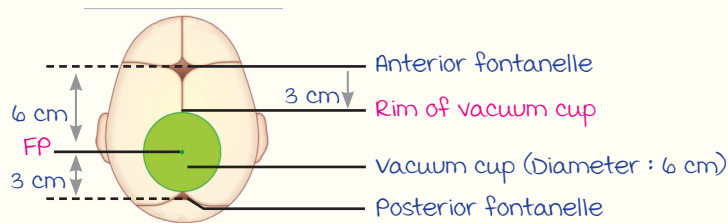
	Forceps	Vacuum
Fetal head rotation	Can not rotate	Can rotate
Used in	<ul style="list-style-type: none"> • Face presentation : mento anterior position • After-coming head of breech (Piper's forceps used) 	Vertex presentation only
Not used in	Vertex presentation	Face presentation (mento anterior), after coming head of breech, preterm labour

Forceps Application :



Vacuum Application :

Site : **Flexion point (FP)**



Complications :

vacuum delivery	Forceps delivery
Fetal > maternal complications	maternal > fetal complications
<p>Fetal complications :</p> <ul style="list-style-type: none"> • 6th nerve palsy • Shoulder dystocia • Cephalothematoma • Subgaleal hematoma • Retinal injury 	<p>Fetal complications :</p> <ul style="list-style-type: none"> • Facial nerve palsy • Brachial plexus injury • Corneal injury

----- Active space -----

Antepartum Fetal Monitoring

00:38:25

Indications :

- All high-risk pregnancies (Begin at : 32 weeks).
- If a pregnant ♀ c/o ↓ fetal movement (Fm).

methods :

Screening tests : NST > modified BPS (Amniotic fluid index + NST).

Diagnostic test : Biophysical score (BPS)/manning score.

Non Stress Test (NST) :

Normal/reactive/negative NST :

Fetal heart rate (FHR) : 110-160 bpm.

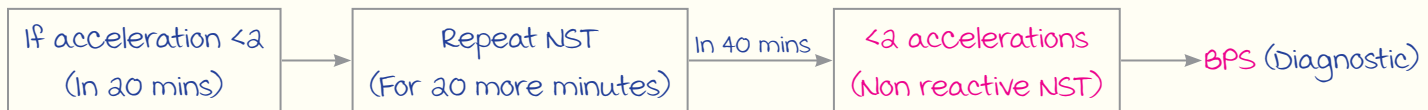
FHR variability : 5-25 bpm.

Accelerations :

- ↑ FHR by 15 bpm x 15 seconds with fetal movement (Good sign).
- In 30-32 weeks : FHR ↑ Capillary permeability. by 10 bpm x 10 seconds.

Reactive NST : ≥2 accelerations in period of 20 mins.

Non reactive/positive NST :



False -ve NST
• Hypoxic fetus but NST : (N)
• False -ve NST rate : Low

False +ve NST
Normal fetus but NST : Non-reactive

BPS/manning score :

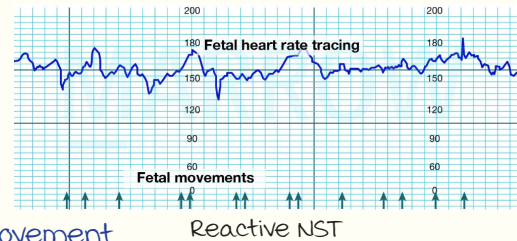
- Done with help of USG over 30 minutes.

Component	Score of 2 given when
Mnemonic : TB meningitis Always Notorious	-
Fetal Tone	≥1 episode of extension/flexion
Fetal Breathing	≥1 chest wall movement for ≥30 seconds
Gross Body movement	≥3 body movements
Amniotic Fluid volume (AFV)	Single deepest pocket ≥2 cm
NST	Reactive

Note : Acceleration → Healthy fetus.

Deceleration → Compromised fetus.

Fetal movements
• Cardiff count of 10 : <ul style="list-style-type: none"> - While at rest : 10 Fm in 2 hours - In activity : 10 Fm in 12 hours
• maximum fetal movements : Seen at 34 weeks
• Quickening : <ul style="list-style-type: none"> - Primigravida : 18-20 weeks - Multigravida : 16-18 weeks



Scoring :

- (N) BPS : 8 or 10 → A/w (N) pH of fetus.
- A score of 0, 2, 4 → A/w fetal acidemia.
- A score of 6 is equivocal.

----- Active space -----

Score	mx
10/10 or 8/10 with AFV : (N)	Fetus : (N), repeat BPS weekly
6/10 with AFV : (N)	Equivocal → ↳ ≥37 weeks : Deliver ↳ <37 weeks : Repeat test in 24 hours
8/10 or 6/10 with AFV : ↓	Deliver ≥36 weeks (In these cases, chronic asphyxia suspected)
Score 4/10	Deliver ≥32 weeks
Score 2/10 or 0/10	Immediate delivery

Intrapartum Fetal Monitoring

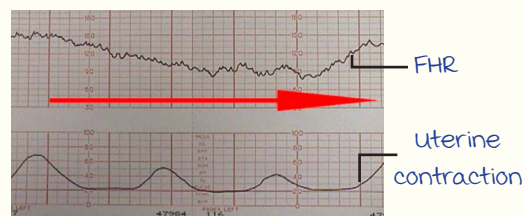00:45:05

CARDIOTOCHOGRAPHY (CTG)

Characteristics of Normal/Category I CTG :

- FHR : 110-160 bpm
- Variability : 5-25 bpm
- Acceleration : (+)/(-)
- Deceleration : Dip in FHR by 15 bpm for 15 seconds (max : 2 mins)
 - Early : (+)/(-)
 - Late } should be (-)
 - Variable }

Prolonged deceleration
<ul style="list-style-type: none"> • When lasts for 2-10 mins • Seen in : <ul style="list-style-type: none"> - uterine stimulation - Drugs like oxytocin, misoprost

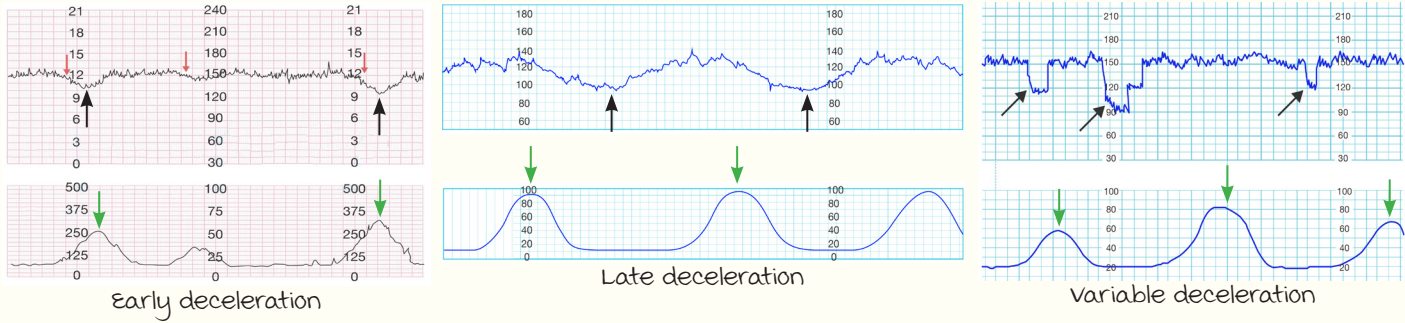


Prolonged deceleration

Types (??) :

	Early deceleration	Late deceleration	Variable deceleration
Shape	'U' shaped		'V' shaped
Onset	Gradual onset		Abrupt onset, rapid frequency
Dip in FHR	Absolutely coincides with uterine contraction	Later than uterine contraction	No relation to uterine contraction
Features	Physiological	most ominous type of deceleration	(-)
Seen	D/t head compression	In uteroplacental insufficiency	In cord compression

----- Active space -----



→ : Dip in FHR
 → : uterine contraction

Category 3 CTG Findings :

1. Sinusoidal heart wave pattern.
2. Absent variability with any of the following :
 - Persistent bradycardia.
 - Persistent late deceleration.
 - Persistent variable deceleration (Only indication for amnioinfusion).

Steps for In-utero resuscitation
<ul style="list-style-type: none"> • Lie in left lateral position • Stop oxytocin → Start O₂, IV fluids • If FHR not normalizing → Give tocolytics.

management : In utero resuscitation + Immediate C-section.

Parameters having worst prognosis :

Sinusoidal heart wave pattern > late deceleration > variable deceleration.

Sinusoidal heart wave pattern	
<ul style="list-style-type: none"> • Constant FHR/⊖ variability/ sine wave pattern • Bad prognosis • Seen in fetal anemia, fetal hypoxia. 	

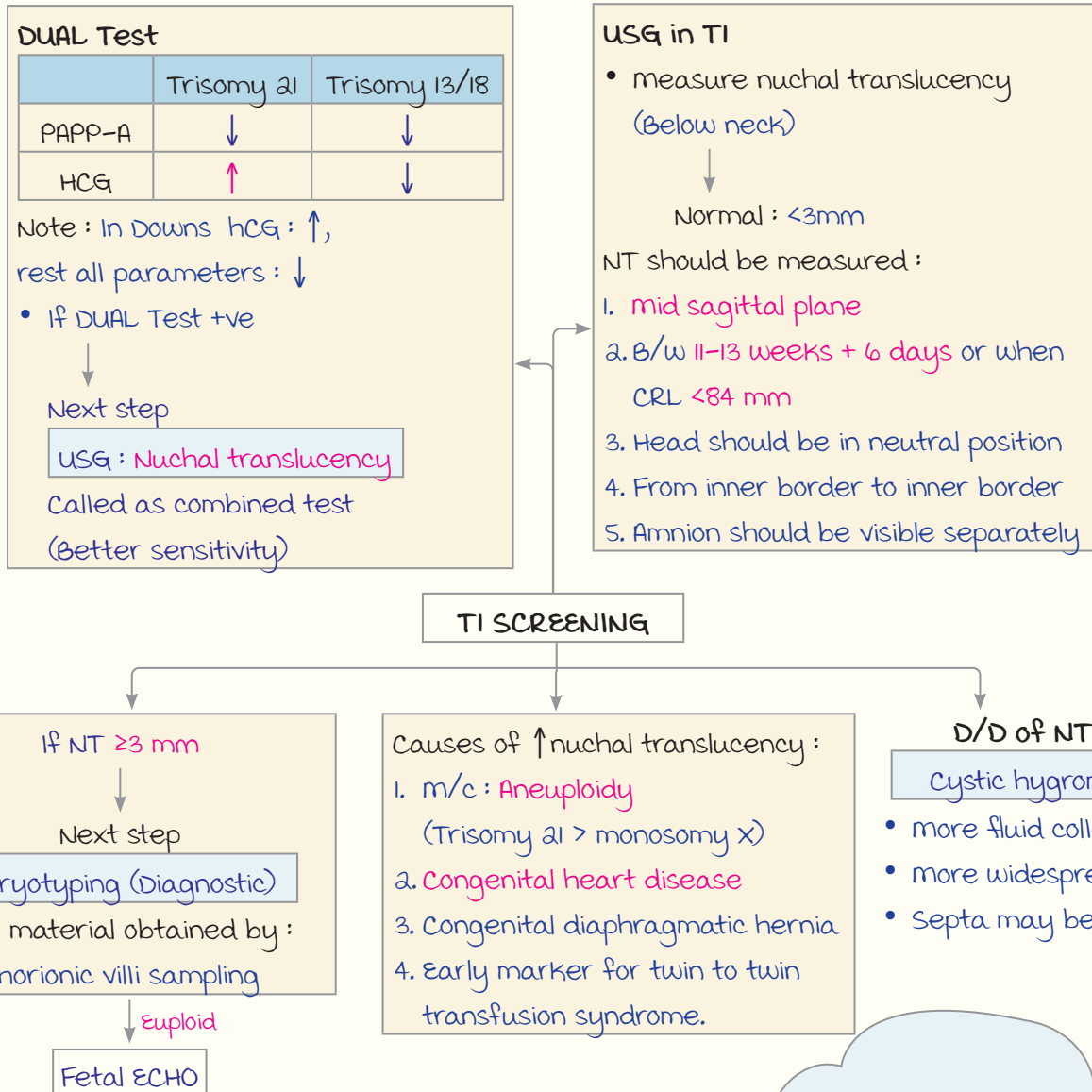
First Trimester Screening

00:52:08

----- Active space -----

Aneuploidy screening :

- universally done (In T₁ : 11 to 13 weeks + 6 days).
- In all pregnant ♀ (irrespective of maternal age).

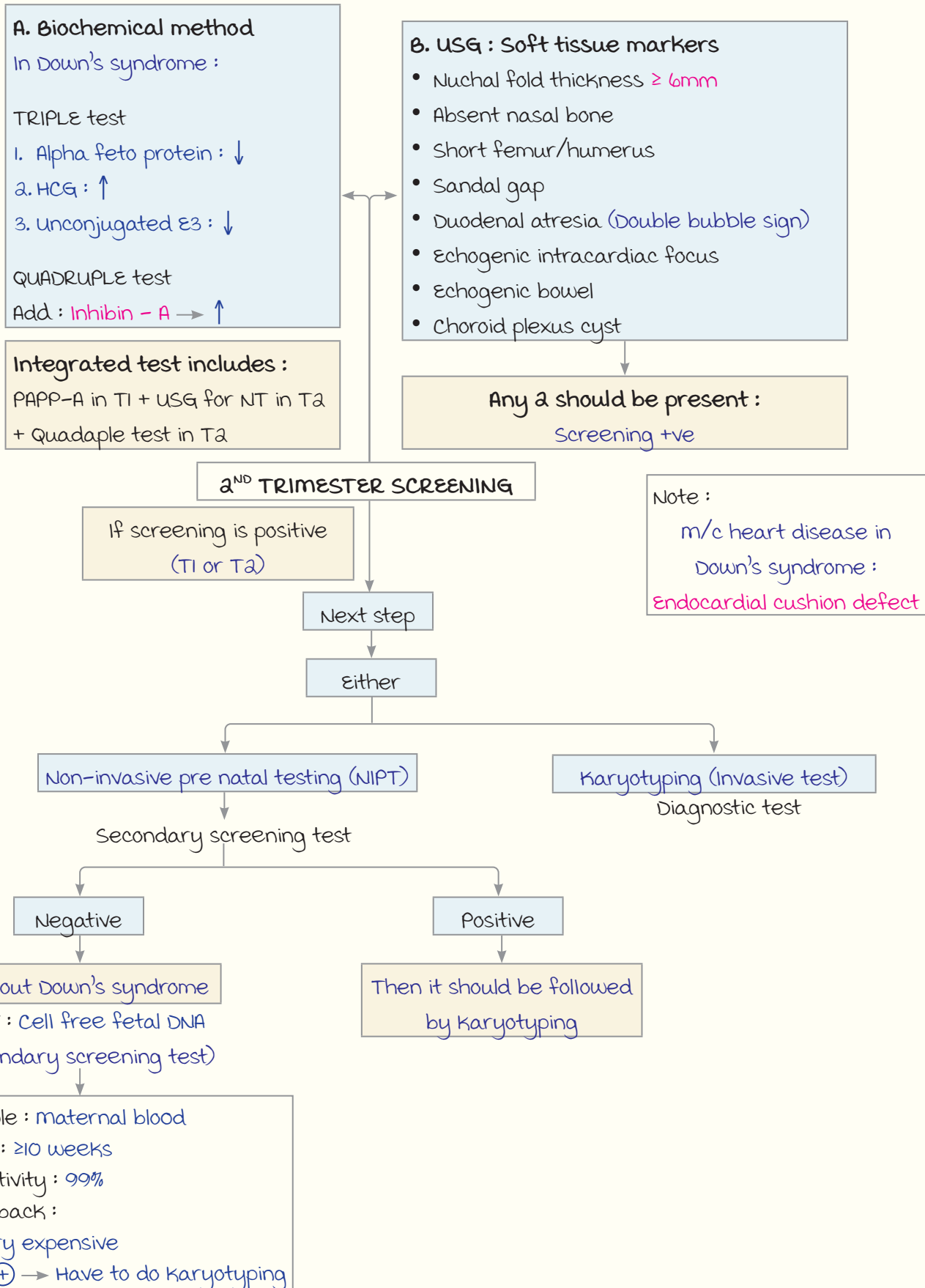


Important : Cystic hygroma → better marker of aneuploidy than nuchal translucency.

Second Trimester Screening

00:56:25

----- Active space -----



methods of Obtaining Genetic material :

----- Active space -----

	Chorionic villi sampling	Amniocentesis	Cordocentesis/ per-umbilical blood sampling
Sample	Trophoblast	Amniocyte, pulmonary fibroblast	Fetal blood (Umbilical vein)
Time	11 to 13 weeks + 6 days	16-18 weeks (15-20 weeks)	≥18 weeks
Avoid in	< 10 weeks (Lead to oromandibular & limb defects in fetus)	11-14 weeks (↑ Chances of fetal loss)	-
Fetal loss	1%	0.5%	3%
Others	Test results obtained faster than amniocentesis	Safer than chorionic villi sampling	<ul style="list-style-type: none"> • Only indication : Rh isoimmunised pregnancy • Not done for karyotyping

Puerperium

01:02:44

Lochia :

Shedding of decidua after delivery.

Average duration : 24-36 days.

Sequence of lochia : Lochia Rubra → Lochia serosa → Lochia alba
 (≥4 days) (≥10 days)

Uterine Involution :

uterine height : Just below umbilicus ≈ 20 weeks of POG

↓ Till 24 hours (Post delivery)

uterine height : unchanged

↓ After 24 hours

Height ↓ by 1 finger breadth/day below umbilicus.

Summary Tables

01:04:30

C/I to Breastfeeding :

Absolute	Galactosemia
Relative	<ul style="list-style-type: none"> • Anticancer drugs/chemotherapy • Illicit drug user
Infections	<ul style="list-style-type: none"> • Active TB infection • Brucellosis • HSV • Ebola virus • HTLV 1, 2 • Varicella zoster infection (within 5 days prior to delivery & 2 days after delivery)

----- Active space ----- **Nutritional Requirements in Pregnancy :**

Variable	Non pregnant ♀	Pregnancy			Lactation	
		T1	T2	T3	0-6 months	6-12 months
Body weight	55 Kg	55 kg + kg in entire pregnancy				
Energy (kcal/d) :						
• Sedentary	1700		+350		+600	+520
• moderate	2100					
• Heavy	2500					
Protein (g/d)	45		+9.5	+22	+16.9	+13.2
Carbohydrates (g/d)	130		175		200	
Iron (mg/d)	29		40		23	
Iodine (mcg/d)	150		250		280	
Calcium (mg/d)	1000		1000		-	
Vitamin A (mcg/d)	840		900		-	
Folate (mcg/d)	220		570 (Tablet : 500mcg)		330	

High Risk Pregnancy (Govt of India) :

- Previous h/o LSCS.
- Bad obstetric history.
- H/o systemic illness.
- Age : >35 years.
- PIH.
- malpresentation.
- Low lying placenta.
- Severe anemia.
- Rh -ve pregnancy.
- Gestational Diabetes.
- Hypothyroid.
- HIV +ve/syphilis.

Radiological Signs of Intrauterine Death :

Robert sign (1 st sign)	Presence of gas in great vessels
Spalding sign	Overlapping of cranial bones of fetus
Ball sign	Hyperflexion/Hyperextension of spine
Deuel's halo sign	↑ Pericranial fat

Time of Termination of Pregnancy (TOP) :

----- Active space -----

Condition	Time of TOP
mild pre-eclampsia	37 weeks
Severe pre-eclampsia	34 weeks
Impending eclampsia/eclampsia	Immediate TOP after 1st dose of steroid
HELLP syndrome	
PIH with fetal distress/abruption	
umbilical artery doppler : s/d ratio >3	37 weeks
Absent diastolic flow	33-34 weeks
Reversed diastolic flow	31-32 weeks
IUGR → Doppler s/d ratio <3 :	
• Weight : 3-9 percentile	39 weeks
• Weight : <3 percentile	37 weeks
IUGR → s/d ratio >3	37 weeks
↑s/d ratio + IUGR + oligohydramnios	34 weeks
Diabetes : Type A1 or A2 (Well controlled)	39 weeks
Diabetes : Type A2 (Not well controlled)	37 weeks
Overt diabetes : No complication	39 weeks
Overt diabetes + vasculopathy	37 weeks
mCMA twins /conjoint twins	32-34 weeks by cesarean section
mCDA twins	34-37 weeks
DCDA twins	38 weeks
Cholestasis in pregnancy	37-38 weeks
AFLP	Immediate TOP

----- Active space ----- Important Drug Dosages :

	Indication	Dose	Schedule
misoprost	TI medical abortion	800 mcg P/v	<ul style="list-style-type: none"> To be given on D3 On D1 : 200 mg mifepristone
	T2 abortion	200-800 mcg P/v	<ul style="list-style-type: none"> WHO : 400 mcg every 3 hourly max : 4 doses
	AMTSL	600 mcg oral	Can : 400-600 mcg
	PPH	800 mcg S/L or oral	ACOG : 600-1000 mcg S/L, oral or P/R
	Induction of labour	25 mcg	Repeat every 4 th hourly (max : 6 doses)
Carbetocin	AMTSL	100 mcg slow IV	-
Carboprost	PPH	250 mcg	<ul style="list-style-type: none"> Repeat in 15-90 minutes max : 8 times → 2 mg
Dinoprostone	Induction of labour	0.5 mg	<ul style="list-style-type: none"> Repeated 6 hourly max : 4 times